

## Original Article

### Assessment of presence of middle mesial canal in mandibular molars in a tertiary hospital using CBCT: A cross sectional study

Dr. K. Hanisha Reddy<sup>1</sup>, Dr. Keshini MP<sup>2</sup>, Dr. Jaydip Marvaniya<sup>3</sup>, Dr. Manjula<sup>4</sup>, Dr. Bhavna Malik<sup>5</sup>, Dr. Dalli Bharath Simha Reddy<sup>6</sup>, Dr. Heena Dixit Tiwari<sup>7</sup>

<sup>1</sup>Assistant professor, Dept of Conservative Dentistry and Endodontics, Government dental College, Vijayawada, India;

<sup>2</sup>MDS, Senior resident, Dept of Craniofacial Anomalies, Kanachur Institute of Medical Sciences, Natekal, Mangalore, India;

<sup>3</sup>MDS, Senior Lecturer, Department of Conservative Dentistry and Endodontics, Teerthanker Mahaveer Dental College and Research Centre, Moradabad, India;

<sup>4</sup>Senior Lecturer, Dept of Orthodontics, Sri Siddhartha Dental College and Hospital, Sri Siddhartha Academy of Higher Education, Tumkur, Karnataka, India;

<sup>5</sup>Assistant professor, Oral and Maxillofacial Surgeon, Department of Dentistry, Shri Guru Ram Rai Institute of Medical and Health Sciences and Shri Mahant Indires Hospital, Dehradun, Uttarakhand, India;

<sup>6</sup>Postgraduate student, Department of Periodontics, Lenora Institute of Dental Sciences, Rajahmundry, AP, India;

<sup>7</sup>BDS, PGDHHM, Final year Student, Master of Public Health, Parul Univeristy, Limda, Waghodia, Vadodara, Gujrat, India

#### ABSTRACT:

**Introduction:** For the successful endodontics all the presentations of the root canals have to be well understood. Hence in this study we aim to assess the presence of the middle mesial canal mandibular molars in a tertiary hospital by CBCT. **Materials and Methods:** We considered 100 subjects whose CBCT images were collected at the institutional department of endodontics. The shape and presence of MMC, canals and number of roots, were evaluated in mandibular molars with no previous restorations or therapies. Thus collected data was analyzed keeping  $p < 0.05$  as significant. **Results:** Out of 254 teeth assessed middle mesial canals found in 30 teeth with an overall prevalence of 10 percent with significantly higher prevalence in first molar than second molar. There was no statistical correlation between the existence of MMCs and demographics. **Conclusion:** we can conclude that, the total prevalence of MMC was 10%. And mostly seen in the first mandibular molar.

**Key Word:** Middle Mesial Canal, Cone Beam Computed Tomography, Mandibular Molar.

Received: 03-07-2021 Revised: 25-07-2021 Accepted: 12-08-2021 Published: 25-08-2021

**Corresponding author:** K. Hanisha Reddy, Assistant professor, Dept of Conservative Dentistry and Endodontics, Government dental College, Vijayawada, India

**This article may be cited as:** Reddy KH, MP Keshini, Marvaniya J, Manjula, Malik B, Reddy DBS, Tiwari HD. Assessment of presence of middle mesial canal in mandibular molars in a tertiary hospital using CBCT: A cross sectional study. *J Adv Med Dent Scie Res* 2021;9(8):143-145.

#### INTRODUCTION

The mandibular molars are the most important teeth in the mouth and also the most common root canal treated. Various presentations of the canals are also reported in the literature.<sup>[1-3]</sup> For successful root canal therapy the thorough knowledge of the anatomies and

the presentations is to be known.<sup>[4]</sup>

The missed canals may lead to failures in the endodontics. Middle Mesial Canal (MMC) is usually reported in the studies.<sup>[5-7]</sup> Failure to detect the presence of an MMC during endodontic treatment of mandibular molar teeth could lead in bacterial

## Oral Hygiene Status of Patients with Cardiac Disorders Undergoing Orthodontic Treatment: An Original Research

Dr. Anies Ahmed<sup>1</sup>, Dr. Sachin Durkar<sup>2</sup>, Dr. Hani Patel<sup>3</sup>, Dr. Kankipati Amrutha<sup>4</sup>, Dr. Jigar M Yadav<sup>5</sup>, Dr. Dalli Bharath Simha Reddy<sup>6</sup>, Dr. A. Madhuri Krishna<sup>7</sup>

<sup>1</sup>Senior Lecturer, Dept of oral medicine and radiology, ACPM dental college dhule, Maharashtra. aniesmalik63@gmail.com

<sup>2</sup>Professor & PG Teacher, Department of Orthodontics & Dentofacial Orthopedics, Dr. D. Y. Patil Vidyapeeth, Pimpri, Pune, India. sachin.durkar@gmail.com

<sup>3</sup>BDS, Sumandeep Vidyapeeth University, Waghodia, Vadodara, Gujarat, India. hanipatel78@gmail.com

<sup>4</sup>Postgraduate student, Department of Periodontics, Lenora Institute of Dental Sciences, Rajahmundry, AP. amrutharamam@gmail.com

<sup>5</sup>Senior lecturer, Department of pediatric and preventive dentistry, The Yogita dental college, Khed, Maharashtra, India. jigarmyadav@gmail.com

<sup>6</sup>Postgraduate student, Department of Periodontics, Lenora Institute of Dental Sciences, Rajahmundry, AP. bharathsimha305@gmail.com

<sup>7</sup>Intern, SIBAR INSTITUTE OF DENTAL SCIENCES, Guntur, AP, India. madhurikrishna18@gmail.com

**Corresponding author:** Dr. Anies Ahmed, Sr. Lecturer, Dept of oral medicine and radiology, ACPM dental college dhule, Maharashtra. aniesmalik63@gmail.com

### ABSTRACT:

**Introduction:** The risk factors associated with cardiovascular diseases also suggest that the relationship between periodontal disease and diabetes works in both ways. The aim of this study was to support and strengthen the association and relationship between oral hygiene status of individuals with cardiovascular diseases and its associated risk factors who were undergoing the orthodontic treatment or have undergone the treatment.

**Material and methods:** A simple random sampling was carried out in 200 subjects. An oral health visit and examination was made for an equal number of males and females of different age groups with cardiovascular diseases. Evaluation of the oral status was made by means of an oral hygiene index, community periodontal index of treatment needs and loss of attachment.

**Results:** Evaluation of oral status in patients with cardiovascular diseases and in the control group has shown a statistically significant low level of oral health in patients with cardiovascular diseases as compared to control. Prevalence of systemic diseases in different age groups significantly correlated with the prevalence of severe periodontal diseases.

**Conclusion:** Treating gum disease may reduce the risk of heart disease and improve health outcomes for patients with periodontal disease and vascular heart problems.

**Key words:** Oral Hygiene, Cardiac Diseases, Orthodontic Treatment.



## Evaluation of Regenerative Periodontal Therapy in Intrabony Defects with Single Flap Approach Using Bovine Xenograft in Smokers and Non-smokers

Dalli Bharath Simha Reddy<sup>1</sup>, Rupasree Gundala<sup>2\*</sup>, Kankipati Amrutha<sup>1</sup>, Nemakal Sumana<sup>1</sup>, Ch Susmitha SS<sup>1</sup> and Sravani Bontu<sup>1</sup>

<sup>1</sup>Postgraduate Student, Department of Periodontics, Lenora Institute of Dental Sciences, Rajamahendravaram, India

<sup>2</sup>Assistant Professor, Government Dental College and Hospital, Vijayawada, India

\*Corresponding Author: Dalli Bharath Simha Reddy, Postgraduate Student, Department of Periodontics, Lenora Institute of Dental Sciences, Rajamahendravaram, India.

Received: February 19, 2021

Published: March 11, 2021

© All rights are reserved by Dalli Bharath Simha Reddy, et al.

### Abstract

**Introduction:** Periodontal disease is the most prevalent disease across the world. It is an inflammatory disease involving progressive and episodic loss of the periodontal attachment apparatus with tissue destruction consequentially arising out of host response against bacterial antigens as well as irritants leads to loss of alveolar bone and supporting the teeth. Chronic periodontitis causes various types of bony defects, among them intra-bony defect is most common. There are two primary treatment modalities for treating periodontitis and associated changes, including non-surgical and surgical periodontal therapy.

**Aims and Objectives:** To compare the results yielded by bovine xenograft in smokers and nonsmokers patients with chronic periodontitis from baseline to 6 months. To compare the clinical parameters - probing depth (PD), clinical Attachment Level (CAL), radiographic Bone fill from baseline to 6 months after the surgical therapy.

**Materials and Methods:** A cross-sectional clinical study was conducted with a sample of twenty-four patients selected from department of periodontics, Lenora institute of dental sciences, Rajahmundry, Andhra Pradesh, India. The patients selected for this study are divided in to two groups i.e., Smokers group and Non-smokers' group. Initially both Smokers and Non-smokers sites were treated with scaling and root planing alone. Patients included in this study were treated with bovine xenograft using single flap approach technique.

**Results:** All values were subjected for statistical analysis by using the following formulas Unpaired 't' Test or independent sample 't' test, Paired "t" test, Mann-Whitney U test.

**Conclusion:** We found that there was significant improvement in clinical parameters i.e., plaque index (PLI), sulcus bleeding index (SBI), probing depth (PD), clinical attachment level (CAL), and bone fill in the sites, before and after periodontal treatment. There was a significant improvement in clinical attachment level gain and bone fill in both the groups treated with bovine xenograft using a single flap approach from baseline to six months. The results of this study point towards the novel direction of current surgical regenerative approaches. Further, long term, multi-center, prospective longitudinal trials are the need of the hour to confirm the find-ing of this study.

**Keywords:** Probing Depth (PD); Clinical Attachment Level (CAL); Smoker

**Citation:** Dalli Bharath Simha Reddy, et al. "Evaluation of Regenerative Periodontal Therapy in Intrabony Defects with Single Flap Approach Using Bovine Xenograft in Smokers and Non-smokers". *Acta Scientific Dental Sciences* 5.4 (2021): 40-48.

## Case Report

# Basal cell adenocarcinoma of the minor salivary gland - A rare case report involving the upper lip

### ABSTRACT

Minor salivary gland neoplasms constitute up to approximately 25% of all salivary gland tumors. The incidence of malignancy of these tumors is slightly greater than half. Basal cell adenocarcinoma (BCAC) is a rare salivary gland malignancy that occurs most commonly in the parotid gland. In this report, we describe a case of an older woman presenting with BCAC of the upper lip arising from the minor salivary gland.

**KEY WORDS:** Basal cell adenocarcinoma, minor salivary gland neoplasm, upper lip lesion

### INTRODUCTION

Basal cell adenocarcinoma (BCAC) is a rare salivary gland tumor, which is considered to be the malignant counterpart of basal cell adenoma (BCA).<sup>[1]</sup> BCAC accounts for only 2.9% of all malignant salivary neoplasms, which was included in the 1991 World Health Organization (WHO) classification.<sup>[2]</sup> In 2005, the WHO classification simply defined BCAC as being an infiltrative epithelial neoplasm.<sup>[3]</sup> It affects predominantly the major salivary glands, and there are very few reports of them occurring in the minor salivary glands.<sup>[4]</sup> BCAC may arise either *de novo* or from a preexisting BCA with which it shares demographic and histologic features. We report an interestingly rare case of BCAC affecting the upper labial mucosa in a 70-year-old female.

### CASE REPORT

A 70-year-old female patient presented with a chief complaint of slow-growing painless swelling on the upper labial mucosa for the past 18 months that was sudden in onset and was smaller initially and gradually attained the present size. On clinical examination, extraorally, a solitary diffuse swelling was seen on the right corner of the upper lip measuring approximately about 2 cm × 1.7 cm in size extending superoinferiorly from the right nasolabial fold to the lower border of the upper lip and mediolaterally from 1 mm away from philtrum

to the right corner of the upper lip [Figure 1]. The skin over the swelling is normal. Intraoral examination revealed a lobulated mass measuring 2.5 cm × 2 cm × 1 cm in diameter, with well-defined borders extending superoinferiorly from the upper right labial vestibule to the vermilion border of the upper lip and mesiodistally from the distal aspect of 11 to the mesial aspect of 14 region with no surface ulceration [Figure 2]. Upon palpation, the swelling was firm, nontender, noncompressible, nonpulsatile. Regional lymph nodes were not palpable. Based on clinical features, the lesion was diagnosed as neurofibroma. Complete surgical excision was done [Figure 3], and the specimen was sent to the department of oral and maxillofacial pathology for a definitive diagnosis.

On gross pathologic examination, it was a firm, unencapsulated, creamish brown oval mass with irregular surface and borders which was grossed into three bits [Figure 4] and was subjected to histochemical processing.

Microscopic examination with hematoxylin and eosin staining showed an unencapsulated salivary gland neoplasm consisting of infiltrative basaloid cells

This is an open access journal, and articles are distributed under the terms of the Creative Commons Attribution-NonCommercial-ShareAlike 4.0 License, which allows others to remix, tweak, and build upon the work non-commercially, as long as appropriate credit is given and the new creations are licensed under the identical terms.

For reprints contact: [WKHLRPMedknow\\_reprints@wolterskluwer.com](mailto:WKHLRPMedknow_reprints@wolterskluwer.com)

**Cite this article as:** Prakash AJ, Christina SS, Lakshmi MV, Polishetty N. Basal cell adenocarcinoma of the minor salivary gland - A rare case report involving the upper lip. *J Can Res Ther* 2022;18:765-9.

A. Jacob Prakash,  
S. Sushmitha  
Christina,  
M. Vijaya  
Lakshmi,  
Naveen  
Polishetty<sup>1</sup>

Department of Oral and Maxillofacial Pathology, Lenora Institute of Dental Sciences, Rajahmundry, <sup>1</sup>Department of Oral and Maxillofacial Surgery, Konaseema Institute of Dental Sciences, Amalapuram, Andhra Pradesh, India

**For correspondence:**  
Dr. M. Vijaya  
Lakshmi,  
Department of Oral and Maxillofacial Pathology, Lenora Institute of Dental Sciences, Rajahmundry, Andhra Pradesh, India.  
E-mail: [viji.mahanthi@gmail.com](mailto:viji.mahanthi@gmail.com)

Submitted: 25-Jan-2020

Revised: 06-Apr-2020

Accepted: 22-Jun-2020

Published: 25-Jul-2022

Access this article online

Website: [www.cancerjournal.net](http://www.cancerjournal.net)

DOI: 10.4103/jcr.t.JCRT\_108\_20

Quick Response Code:






Content available at: <https://www.ipinnovative.com/open-access-journals>

International Journal of Oral Health Dentistry

Journal homepage: [www.ijohd.org](http://www.ijohd.org)



## Original Research Article

# Evaluation of possible reasons for asymmetries associated with Class II subdivision, Class II division 1 and normal malocclusion

Velagapalli Jessie Ratan<sup>1,\*</sup>, Kiran Kumar<sup>2</sup>, Ravi Krishna K<sup>2</sup>, Eswar Prasad S<sup>2</sup>, Pavan K<sup>1</sup>, Siddhartha N<sup>2</sup>, Naresh V<sup>2</sup>

<sup>1</sup>Dept. of Orthodontics, Lenora Institute of Dental Sciences, Orthodontics, Andhra Pradesh, India

<sup>2</sup>Dept. of Orthodontics, Drs Sudha & Nageswara Rao Siddhartha Dental Institute, Andhra Pradesh, India



### ARTICLE INFO

#### Article history:

Received 16-06-2021

Accepted 22-09-2021

Available online 28-12-2021

#### Keywords:

Asymmetry

Piriform aperture

Maxillary buttress

### ABSTRACT

**Objectives:** To evaluate and compare the asymmetries in subjects with two malocclusions that is Class II subdivision, Class II div 1 and normal occlusion.

**Materials and Methods:** 90 subjects ranging from 15 to 30 years divided into 3 groups A, B, C. Group A – Class II subdivision, Group B – Class II division I, Group C – Normal Class I occlusion. Angular, linear paired, linear unpaired measurements were calculated based on the Van De Coppell analysis using PA views.

**Results:** Asymmetry was found in all the three groups where Group A patients showed greater degree of asymmetry near maxillary buttress and piriform aperture areas compared to the three groups. Group C patients showed greater degree of asymmetry in the occlusal plane angle.

**Conclusion:** All the three malocclusions that is Class II div 1 Subdivision, Class II div 1 and Class I malocclusions showed equal amounts of asymmetry. Class II subdivision patients showed greater asymmetry near maxillary buttress area and piriform aperture. Class I malocclusion showed deviation in occlusal plane angle. Along with the lower third involving mandible, maxillary area also can equally show asymmetry in both skeletal and dental parameters.

This is an Open Access (OA) journal, and articles are distributed under the terms of the Creative Commons Attribution-NonCommercial-ShareAlike 4.0 License, which allows others to remix, tweak, and build upon the work non-commercially, as long as appropriate credit is given and the new creations are licensed under the identical terms.

For reprints contact: [reprint@ipinnovative.com](mailto:reprint@ipinnovative.com)

## 1. Introduction

Perfect symmetry is largely a theoretical concept that seldom exists in living organisms. Variations in size, shape and relationship of dental, skeletal and soft tissue facial structures are important in providing each individual with his or her own identity.<sup>1</sup> Stedman's medical dictionary defines symmetry as "Equality or correspondence in form or parts distributed around a center or an axis at the two extremes or poles, or on the two opposite sides of the body."<sup>2</sup> Symmetry when applied to facial morphology refers to the correspondence in size, shape

and location of facial landmarks on the opposite sides of the median sagittal plane.<sup>3</sup> Asymmetries can be classified according to the structures involved into dental asymmetries, skeletal asymmetries, muscular asymmetries and functional asymmetries.<sup>4</sup> Asymmetry of craniofacial skeleton is most readily diagnosed in frontal view than from any other view.<sup>5</sup> The etiology of asymmetries include:<sup>1</sup>

1. Genetic or congenital malformation. Eg: Hemifacial microsomia, unilateral clefts of lip and palate.
2. Environmental factors. Eg: Habits and trauma.
3. Functional deviations. Eg: Mandibular shifts as a result of tooth interferences.

\*Corresponding author.

E-mail address: [ratanjessie@gmail.com](mailto:ratanjessie@gmail.com) (V. J. Ratan).

<https://doi.org/10.18231/ijohd.2021.056>

2395-4914/© 2021 Innovative Publication, All rights reserved.

287

# An In Vitro Evaluation of the Antimicrobial Activity of Probiotics Against Endodontic Pathogens

Received 06/05/2022  
Review began 06/11/2022  
Review ended 06/19/2022  
Published 06/30/2022

© Copyright 2022  
Charan Teja et al. This is an open access article distributed under the terms of the Creative Commons Attribution License CC-BY 4.0., which permits unrestricted use, distribution, and reproduction in any medium, provided the original author and source are credited.

Garapati Venkata Charan Teja<sup>1</sup>, Mahali Raghu Nandana Raju<sup>1</sup>, Uppu Lavanya Neelima Reddy<sup>1</sup>, Uppalapati V V Satyanarayana<sup>1</sup>, Devatha Praneeth<sup>2</sup>, Kumpatla Maheswari<sup>1</sup>

1. Department of Conservative Dentistry and Endodontics, Lenora Institute of Dental Sciences, Rajahmundry, IND 2. Department of Conservative Dentistry and Endodontics, Meghna Institute of Dental Sciences, Nizamabad, IND

Corresponding author: Garapati Venkata Charan Teja, charangarapati@gmail.com

## Abstract

**Background and aim:** Despite scientific evidence that even some microorganisms may be useful, endodontic intervention has persisted to prioritize the removal of all microorganisms from the root canal system. Indeed, information regarding the significant role of probiotic microorganisms in endodontic treatment has been sparse. This study aimed to carry out an in vitro evaluation of the antimicrobial activity of probiotics against endodontic pathogens.

**Methods:** The evaluation was carried out in three stages. In Stage 1, the agar cup well procedure was used to analyse the efficiency of probiotics microorganisms against *Enterococcus faecalis* bacteria and *Candida albicans* microorganisms in the planktonic stage. In Stage 2, a deferred antagonistic experiment was used to determine the activity of probiotic microorganisms against endodontic pathogens like *E. faecalis* and *C. albicans* in the planktonic phase. In Stage 3, biofilm phase evaluation of an intracanal probiotic microorganism carrier was done. The region of maximum inhibition was measured at the end of Stages 1 and 2. The antimicrobial activity was recognized when the dimension of the region of maximum inhibition was 10 mm or above. The colony-forming unit/millilitre was measured at the end of Stage 3.

**Results:** There was marked antimicrobial activity of probiotic microorganisms against the pathogenic microorganisms *E. faecalis* as well as *C. albicans* in Stages 1 and 3, i.e., during the evaluation involving agar cup and evaluation at the biofilm stage. However, no antimicrobial activity of probiotic microorganisms was observed against pathogenic endodontic microorganisms in Stage 2, i.e., during evaluation involving the use of the deferred antagonistic technique.

**Conclusion:** It can be concluded that probiotic therapy is a promising antibacterial treatment approach that should be further investigated. This study shows that probiotics can help effectively in endodontic treatment and that more in vitro as well as in vivo research is needed to fully appreciate the advantages of bacteriotherapy in the field of endodontics.

**Categories:** Dentistry, Oral Medicine

**Keywords:** e. faecalis, in vitro, candida albicans, endodontic pathogens, probiotics

## Introduction

The goal of endodontic therapy is to complete healing of periapical periodontitis, and the success of therapy is usually measured in eradicating the actual infection and preventing re-infection. It's worth noting that Kakehashi et al. found that study participants having no bacteria did not experience inflammation of periodontal tissues at the root apex despite physical access of the pulp of their molars to the oropharynx. However, control samples with typical oral microbiota acquired considerable radiolucency at the area around the root apex [1]. The flora of the root canal includes different types of microorganisms, with anaerobic species predominating. The root canal microenvironment is ideal for anaerobic microorganisms, which can degrade accessible amino acids and polypeptides to meet their metabolic requirements. Following infection, many microbial species interact among themselves, causing microbial population changes [2].

Furthermore, such microbial relationships are involved in the formation of complex microbiota in endodontic settings as well as ecological management. As a result, there is an ongoing debate in the field of endodontics about how much we can truly eradicate pathogenic germs from root canals. Multiple auxiliary and lateral canals were discovered during microscopic investigations of serial slices of the roots of various teeth [3]. The most favourable result that can be accomplished is a diminution in the biological burden on these branches, which are never fully free of microorganisms. Most likely, the effectiveness of endodontic treatments is due to a decrease in the number of germs, the removal of the most inflamed or dead tissue, and a healthy systemic background.

### How to cite this article

Charan Teja G, Nandana Raju M, Neelima Reddy U, et al. (June 30, 2022) An In Vitro Evaluation of the Antimicrobial Activity of Probiotics Against Endodontic Pathogens. Cureus 14(6): e26455. DOI 10.7759/cureus.26455

# Identification & Correlation of Candida Strains with CD4+ Count Among HIV Patients on HAART and Evaluation of In-Vitro Susceptibility to Fluconazole and Voriconazole

Naidu Harika, Koduri Sridevi, Buduru Krishnaveni, Nalli Prasanth Kumar, Gutta Mounika, Adari Devi Naga Deepika<sup>1</sup>

Department of Oral Medicine and Radiology, Lenora Institute of Dental Sciences, Rajahmundry, <sup>1</sup>GSL Dental College and Hospital, Andhra Pradesh, India

## Abstract

**Background:** HIV is a life-threatening disease that increases morbidity and mortality due to the alterations of the body's immune system, leading to several opportunistic infections due to the progressive loss of CD4+ T lymphocytes. **Aim:** To identify and correlate the Candida strains with CD4+ count in Human Immunodeficiency Virus (HIV) patients on Highly active antiretroviral therapy (HAART) and evaluate the in-vitro susceptibility to fluconazole and voriconazole. **Materials and Methods:** A total of 100 HIV-positive patients who were not under HAART therapy were examined at three different intervals for the presence of Candida strains along with their CD4+ count and evaluated for in-vitro susceptibility to fluconazole and voriconazole. The obtained values were analyzed using the Spearman correlation test and Chi-square tests with a significant *P* value of 0.005 and SPSS version 20.0 software. **Results:** *C. albicans* was the most common species isolated, followed by *C. krusei*, *C. glabrata*, and *C. tropicalis*. *C. glabrata* showed a positive correlation with CD4+ count at 6 months of HAART therapy. The variation in CD4+ count prior to HAART therapy and at 3 and 6 months of HAART therapy showed a significant increase in the CD4+ count. Antifungal susceptibility testing showed that all Candida strains were resistant to fluconazole and susceptible to voriconazole. **Conclusion:** The correlation of CD4+ count with Candida strains and in-vitro susceptibility of voriconazole to all the identified strains of Candida as observations from the present study suggests the need for more periodic studies among different sample populations with larger sample size.

**Keywords:** Antifungal susceptibility, CD4+ count, CHROMagar Chromogenic media, highly active antiretroviral therapy, human immunodeficiency virus

## INTRODUCTION

Human immunodeficiency virus (HIV) is an RNA retrovirus that affects the human immune system, resulting in loss of normal defense mechanisms and life-threatening infections. Its detection for the first time in India was in April 1986 in the state of Tamil Nadu.<sup>[1]</sup> HIV infects and kills CD4+ T cells; therefore, during HIV infection, infected and healthy CD4+ T cells act in opposition to each other, reproducing virus particles and resulting in progressive failure of the immune system.<sup>[2]</sup>

Opportunistic infections are the common and early complications and are predictors for the progression of the HIV disease, resulting in shortening the life span.<sup>[3]</sup> Oral candidiasis is the most common opportunistic fungal infection in HIV patients caused by *C. albicans*. Although *C. albicans* is the most common strain, other non-*albicans* strains are also predominantly seen in HIV patients. The high


incidence of candidiasis in HIV patients and increased use of antifungal drugs eventually results in increased resistance to the conventional antifungal agents. Moreover, the prevalence of non-*albicans* strains that do not respond to conventional antifungal therapy is on the rise.<sup>[4]</sup>

Moreover, oral physicians get to encounter HIV patients with candidiasis on a daily basis. As various strains of

**Address for correspondence:** Dr. Naidu Harika,  
Department of Oral Medicine and Radiology, Lenora Institute of Dental  
Sciences, Rajahmundry, Andhra Pradesh, India.  
E-mail: [harikanaidu8@gmail.com](mailto:harikanaidu8@gmail.com)

This is an open access journal, and articles are distributed under the terms of the Creative Commons Attribution-NonCommercial-ShareAlike 4.0 License, which allows others to remix, tweak, and build upon the work non-commercially, as long as appropriate credit is given and the new creations are licensed under the identical terms.

For reprints contact: [WKHLRPMedknow\\_reprints@wolterskluwer.com](mailto:WKHLRPMedknow_reprints@wolterskluwer.com)

Access this article online	
Quick Response Code: 	Website: <a href="http://www.jiaomr.in">www.jiaomr.in</a>
	DOI: 10.4103/jiaomr.jiaomr_82_21

**How to cite this article:** Harika N, Sridevi K, Krishnaveni B, Kumar NP, Mounika G, Naga Deepika AD. Identification & correlation of candida strains with CD4+ count among HIV patients on HAART and evaluation of in-vitro susceptibility to fluconazole and voriconazole. *J Indian Acad Oral Med Radiol* 2022;34:38-44.

Received: 25-03-2021  
Accepted: 26-01-2022

Revised: 18-10-2021  
Published: 25-03-2022

# Evaluation of Genomic Damage from Buccal Epithelial Cells in Patients Subjected to Cone Beam Computed Tomography

Gutta Mounika, Koduri Sridevi, Buduru Krishnaveni, Nalli Prasanth Kumar, Harika Naidu, Bonthagarla Krishna Sahi<sup>1</sup>

Department of Oral Medicine and Radiology, Lenora Institute of Dental Sciences, <sup>1</sup>Department of Oral Medicine and Radiology, GSL Dental College and Hospital, Rajahmundry, Andhra Pradesh, India

## Abstract

**Background:** Radiography forms an important and integral part in diagnosis which is used in the oral and maxillofacial region to give an appropriate diagnosis and treatment planning. But, diagnostic radiations also induce some amount of cell damage at cytogenetic levels, depending on the dosage of the radiation administered. The ionizing radiation which has been emitted during these procedures has deleterious effects on the DNA and induces cell death. **Aim:** To evaluate the genomic damage from buccal epithelial cells in patients subjected to cone-beam computed tomography (CBCT). **Materials and Methods:** Patients were divided into two groups with 30 subjects in each group. Group-1 included the subjects advised for single CBCT exposure and Group-2 included the subjects advised for double CBCT exposure. Exfoliated buccal epithelial cells were collected immediately before the exposure, 15 days, and 30 days after the CBCT exposure. The cytological smears were examined to detect the micronucleus and pyknotic nucleus. **Results:** The mean of the micronucleus and pyknotic nucleus obtained from group-2 (double exposure) subjects was significantly higher in males than group-1 (single exposure) subjects with a *P* value of 0.0001 during pre-exposure, 15 days, and 30 days after exposure. **Conclusion:** Genomic damage does take place due to cone-beam computed tomography. So, CBCT should be cautiously used when necessary and it cannot be considered as a risk-free procedure.

**Keywords:** Buccal epithelial cells, CBCT, micronucleus, papanicolaou stain, pyknotic nucleus

## INTRODUCTION

The fortuitous chance discovery of X-rays by Sir Wilhelm Conrad Roentgen on November 8, 1895, revolutionized the practice of medicine and made radiology an important diagnostic method in modern medicine.<sup>[1]</sup> As a transition from two dimensional (2D) to three dimensional (3D) procedures, Computed Tomography (CT), Cone-beam computed tomography (CBCT) and Magnetic resonance imaging (MRI) ameliorated the field of Oral Maxillofacial Radiology to determine a definite diagnosis and interventional procedures pertaining to the maxillofacial region.<sup>[2,3]</sup>

As most of the diagnostic radiological modalities or aids use ionising radiation, they may result in cell damage leading to genotoxicity or cytotoxicity.<sup>[4]</sup> The radiation effects of low dose diagnostic radiographic exposures and the resultant genomic damage can be assessed and evaluated by numerous methods, wherein the sensitive analysis and specific approach being the micronucleus (MN) test.<sup>[5,6]</sup>

Buccal Micronucleus Cytome (BMCyt) assay was first proposed in 1983 to determine the presence of micronucleus. The micronuclei are the small extranuclear cytoplasmic DNA bodies that are induced in cells by numerous genotoxic agents that damage chromosomes.<sup>[7,8]</sup>

As the literature shows, there are few studies regarding the genetic damage from the buccal epithelial cells, the present study was undertaken to evaluate the genomic damage from buccal epithelial cells with an attempt to know the effect of radiation exposure in patients subjected to cone-beam computed tomography scans.


**Address for Correspondence:** Dr. Gutta Mounika, Post Graduate Student, Department of Oral Medicine and Radiology, Lenora Institute of Dental Sciences, Rajahmundry, Andhra Pradesh, India, E-mail: dr.mounikamalyadri@gmail.com

This is an open access journal, and articles are distributed under the terms of the Creative Commons Attribution-NonCommercial-ShareAlike 4.0 License, which allows others to remix, tweak, and build upon the work non-commercially, as long as appropriate credit is given and the new creations are licensed under the identical terms.

For reprints contact: WKHLRPMedknow\_reprints@wolterskluwer.com

**How to cite this article:** Mounika G, Sridevi K, Krishnaveni B, Kumar NP, Naidu H, Sahi BK. Evaluation of genomic damage from buccal epithelial cells in patients subjected to cone beam computed tomography. *J Indian Acad Oral Med Radiol* 2021;33:372-8.

Received: 25-03-2021 Revised: 16-08-2021  
Accepted: 28-09-2021 Published: 27-12-2021

Access this article online	
Quick Response Code: 	Website: www.jiaomr.in
	DOI: 10.4103/jiaomr.jiaomr_83_21





## TEETH AS A TOOL IN AGE ESTIMATION: A REVIEW

<b>Katru Sreekar*</b>	Post Graduate Student, Dept. of Oral Medicine and Radiology, Lenora Institute of Dental Sciences, Rajahmundry. *Corresponding Author
<b>Koduri Sridevi</b>	Professor and Head, Dept. of Oral Medicine and Radiology, Lenora Institute of Dental Sciences, Rajahmundry.
<b>Buduru Krishnaveni</b>	Reader, Dept. of Oral Medicine and Radiology, Lenora Institute of Dental Sciences, Rajahmundry.
<b>Nalli Prasanth Kumar</b>	Senior lecturer, Dept. of Oral Medicine and Radiology, Lenora Institute of Dental Sciences, Rajahmundry.
<b>Sherly Ruth</b>	Post Graduate Student, Dept. of Oral Medicine and Radiology, Lenora Institute of Dental Sciences, Rajahmundry.
<b>Komma Leela Ramani</b>	Post Graduate Student, Dept. of Oral Medicine and Radiology, Lenora Institute of Dental Sciences, Rajahmundry.

**ABSTRACT** Age estimation is essential in the field of forensic sciences for the identification of diseased victims and also for crimes and accidents. Dental maturity plays an important role in estimating the age of individuals because of the low variability of dental indicators. Chronological age, recorded by registration of birth date, is referred throughout an individual's life. Age is an essential factor not only in clinical practice & research but also in the court of law. Dental age is vital as tooth development shows less variability than other developmental features and hence the different age estimation methods using dental tissues and their eruption sequence of the teeth became crucial in establishing the age of an individual especially those persons in the interest of forensic science. This paper discusses different methods of age estimation using teeth as possible indicator for the biological age, growth & development of the body.

**KEYWORDS** : Chronological age, Dental age, Radiographic method.

#### INTRODUCTION

Teeth are instrumental in estimation of age and the formation of deciduous teeth begins in utero at about four months, while permanent teeth<sup>1</sup> complete the configuration at approximately 25 years of age<sup>2</sup>. Usually chronological age is recorded by registration of date of birth and age is an essential factor in clinical practice<sup>3</sup>, research and court of law. Various methods have constructed and tested to determine the age of young individuals<sup>4</sup>. Among them include the physical examinations using anthropometric measurements<sup>5</sup>, skeletal maturation<sup>6</sup>, dental age estimation, a combination of dental development and anthropometric measurements, and a combination of skeletal and tooth eruption.

#### Need for Dental Age Estimation<sup>1</sup>

Age estimation is an essential step in constructing a biological profile from human skeletal remains, also widely used in estimating the chronological age of children of unknown birth records and for medico-legal purposes. Estimation of age at death and determination of gender of the victim or remains are essential to help in the process of identification<sup>2</sup>. A distinction is there between forensic age estimation of unidentified corpses and skeleton for identification purposes on one hand and on living persons on other hand. In case of living persons, genetic and geographic origin and concomitant socio-economic status must also be taken into account. In case of corpses, crucial factors are the quality and quantity of the mortal remains. In the process of identification of age, usually in the first and second decades, teeth are the most reliable tools.

#### Dental Age Estimation Methods

Based on the technique used for the determination of the age<sup>2</sup>, the dental age estimation methods are classified as follows: Visual or Clinical, Radiographic, Histological, Chemical and Physical analysis.

#### Visual or Clinical Method:

Visual observation of the stage of the teeth eruption and evidence of changes due to functions like attrition, changes in color can give an approximate estimate of age. With this method approximate age estimation can be done, based on the evaluation of the dentition, considering the tooth wear/attrition, tooth color and stains, periodontal status, etc. which can provide valuable information of an individual's development and age<sup>3</sup>. However, tooth wear may not be reliable in age estimation, as tooth wear is influenced by various factors that include functional or parafunctional habits, patterns of mandibular movement,

bite force, saliva, diet, medication, diseases, geographical location, occupational and habitual environment and gender.

#### Radiographic Method:

The most commonly used method aiding in age determination over a long period, using the radiographs of the dentition by determining the stage of development of the teeth. Various radiographic aids used in age estimation are intraoral periapical radiographs, lateral oblique radiographs, cephalometric radiographs, panoramic radiographs along with the digital imaging and advanced imaging modalities. The radiographic method<sup>23</sup> is a simple, non-invasive and reproducible method that can be employed both on living and unknown dead. In adults, following completion of the growth period, the accuracy of age estimation by radiographic method becomes insufficient.

#### Histological Method:

The histological methods determine more accurately the stage of development of the dentition and can detect the mineralization before being detected in the radiographs. This technique is more appropriate for postmortem situations and is also significant in the estimation of age of early development. However, histological methods<sup>3</sup> require the tissue preparation necessitating the extraction or avulsion of teeth for the microscopic examination.

#### Chemical and Physical Analysis:

Formation of tooth involves continuous deposition of ions at different ages. Hence, alteration in the ion levels can be used for age estimation by chemical and physical methods<sup>2,3</sup>. While these techniques are not of great value to the forensic odontologist, future developments may provide an adjunctive of collecting evidence of value.

Based on the age of the individuals, the estimation methods can be categorized into age estimation in prenatal, neonatal & early postnatal child, in children & adolescents and in adults.

#### Age Determination in Prenatal, Neonatal & Early Postnatal Stage:<sup>1,2</sup>

Age estimation in this group can be accurate as it can be correlated with the development of deciduous & permanent teeth. The primary tooth germ begins to form at seven weeks in utero (IU). Determination of age during the development of dentition obtained with an accuracy of "plus or minus one year," and during the early part of this period,



## ANTIOXIDANTS IN ORAL DISEASES: A REVIEW

## Dental Science

<b>Dr. N. Harika*</b>	Post Graduate Student, Dept. of Oral Medicine & Radiology, Lenora Institute of Dental Sciences, Rajahmundry. *Corresponding Author
<b>Dr. K. Sridevi</b>	Professor, Dept. of Oral Medicine & Radiology, Lenora Institute of Dental Sciences, Rajahmundry.
<b>Dr. B. Krishnaveni</b>	Reader, Dept. of Oral Medicine & Radiology, Lenora Institute of Dental Sciences, Rajahmundry.
<b>Dr. N. Prasanth Kumar</b>	Senior Lecturer, Dept. of Oral Medicine & Radiology, Lenora Institute of Dental Sciences, Rajahmundry.
<b>Dr. G. Mounika</b>	Post Graduate Student, Dept. of Oral Medicine & Radiology, Lenora Institute of Dental Sciences, Rajahmundry.

## ABSTRACT

Antioxidants are compounds that destroy the free radicals in the body, thereby preventing harmful oxidation-reduction reactions. Free radicals are chemical species possessing an unpaired electron that can be considered fragments of molecules and generally very reactive. They are produced continuously in cells either as accidental by-products of metabolism or deliberately during phagocytosis. However, excess free radical production originating from endogenous or exogenous sources might play a role in many diseases. Antioxidants are man-made or natural substances that may prevent or delay some types of cell damage. Antioxidants are crucial for maintaining optimum health and well-being. Free radicals have been implicated in numerous oral diseases like leukoplakia, Periodontal diseases, and oral cancer.

## KEYWORDS

Antioxidant, Periodontal disease, oral cancer, leucoplakia.

## INTRODUCTION:

An antioxidant is "any substance that, when present in low concentrations compared to that of an oxidizable substrate, significantly delays or inhibits the oxidation of that substrate."<sup>1</sup> The physiological role of antioxidants, is to prevent damage to cellular components arising as a consequence of chemical reactions involving free radicals. A free radical is any molecular species capable of independent existence that contains an unpaired electron in an atomic orbital—the presence of unpaired electron results in certain common properties shared by most radicals. Many radicals are highly reactive and can either donate an electron to or extract an electron from other molecules, therefore behaving as oxidants or reductants. The most important free radicals in many disease states are oxygen derivatives, particularly superoxide and the hydroxyl radical. Radical formation in the body occurs by several mechanisms involving both endogenous and environmental factors.<sup>1</sup> Antioxidants are nutrients as well as enzymes that assist in chemical reactions.<sup>2</sup>

## HISTORY OF ANTIOXIDANTS:

Duclaux first demonstrated the participation of atmospheric O<sub>2</sub> in the oxidation of free fatty acids. The first reports on antioxidants employed for food lipids were about using natural sources. Olcott and Mattill first reported antioxidant synergism in food. This was significant in achieving oxidative stability in food by using various antioxidants found in the unsaponifiable fraction of oils. Recently, Ferreira et al. studied the prophylactic effect of topical Vitamin E in head and neck cancer patients to prevent radiation-induced oral mucositis.<sup>3</sup>

## GENERATION OF FREE RADICALS AND OXIDANTS:

Free radicals are chemically active atoms with a charge due to an excess or a deficient number of electrons. Free radicals containing oxygen, known as reactive oxygen species (ROS),<sup>4</sup> and reactive nitrogen species (RNS) are the most biologically significant free radicals. ROS includes the radicals superoxide and hydroxyl. Free radicals and other reactive oxygen species are derived from normal essential metabolic processes in the human body or external sources such as exposure to X-rays, ozone, cigarette smoking, air pollutants, and industrial chemicals. Because they have one or more unpaired electrons, free radicals are highly unstable. They scavenge the body to grab or donate electrons, thereby damaging cells, proteins, and DNA.<sup>2</sup>

Superoxide (O<sub>2</sub><sup>-</sup>) is produced by the addition of a single electron to oxygen, and several mechanisms exist by which superoxide can be produced *in vivo*.<sup>5</sup> Several molecules, including adrenaline, flavine

nucleotides, thiol compounds, and glucose, can oxidize in the presence of oxygen to produce superoxide. These reactions are greatly accelerated by the presence of transition metals such as iron or copper. The electron transport chain in the inner mitochondrial membrane performs the reduction of oxygen to water. During this process, free radical intermediates are generated, which are generally tightly bound to the transport chain's components. However, there is a constant leak of a few electrons into the mitochondrial matrix, resulting in superoxide formation.<sup>6</sup> The activity of several other enzymes, such as cytochrome p450 oxidase in the liver and enzymes involved in the synthesis of adrenal hormones, also results in the leakage of a few electrons into the surrounding cytoplasm and hence superoxide formation. There might also be continuous superoxide production by vascular endothelium to neutralize nitric oxide, production of superoxide by other cells to regulate cell growth and differentiation, and superoxide production by phagocytic cells during the respiratory burst.<sup>7</sup>

Any biological system generating superoxide will also produce hydrogen peroxide as a result of a spontaneous dismutation reaction. Several enzymatic reactions, including those catalyzed by glycolate D-amino acid oxidase, might produce hydrogen peroxide directly.<sup>8</sup> Hydrogen peroxide is not a free radical itself but is usually included under the general heading of reactive oxygen species. It is a weak oxidizing agent that might directly damage proteins and enzymes containing reactive thiol groups. However, its most vital property is the ability to cross cell membranes freely, which superoxide generally cannot do. Therefore, hydrogen peroxide acts as a conduit to transmit free radical-induced damage across cell compartments and between cells.

In the presence of hydrogen peroxide, myeloperoxidase will generate hypochlorous acid and singlet oxygen, a reaction that plays an important role in the killing of bacteria by phagocytes. The hydroxyl radical (OH<sup>•</sup>), or a closely related species, is probably the final mediator of most free radical-induced tissue damage. All of the reactive oxygen species described above exert most of their pathological effects by giving rise to hydroxyl radical formation.

Although free radical production occurs due to the endogenous reactions described above and plays a vital role in normal cellular function, it is essential to remember that exogenous environmental factors can also promote radical formation. Ultraviolet light will lead to the formation of singlet oxygen and other reactive oxygen species in the skin. Atmospheric pollutants such as ozone and nitrogen dioxide



THERMOGRAPHY - A REVIEW

<b>Dr. G. Mounika*</b>	Post Graduate Student, Department of Oral Medicine and Radiology, Lenora Institute of Dental Sciences, Rajahmundry. *Corresponding author
<b>Dr. K. Sridevi</b>	Professor, Department of Oral Medicine and Radiology, Lenora Institute of Dental Sciences, Rajahmundry.
<b>Dr. B. Krishnaveni</b>	Reader, Department of Oral Medicine and Radiology, Lenora Institute of Dental Sciences, Rajahmundry.
<b>Dr. N. Prasanth Kumar</b>	Senior Lecturer, Department of Oral Medicine and Radiology, Lenora Institute of Dental Sciences, Rajahmundry.
<b>Dr.N. Harika</b>	Post Graduate Student, Department of Oral Medicine and Radiology, Lenora Institute of Dental Sciences, Rajahmundry.

**ABSTRACT**

Thermography is a technique of measurement of skin temperature distribution on the body over a given period of time. It is a noncontact, noninvasive method that utilizes the heat from an object to detect, display, and record thermal patterns and temperature across the surface of the object. Over the years, various devices have been used to measure the amount of heat dissipated by the body and most recently thermography has been emerged to detect the oral and maxillofacial pathologies. It is used to detect malignancies of the maxillofacial region such as vitality of teeth, TMJ disorders, chronic orofacial pain, assessing inferior alveolar nerve deficit, and detection of herpes labialis. The present article highlights the history, basic principles, types and applications of thermography and its beneficial role in detecting the maxillofacial pathologies in dentistry.

**KEYWORDS :** Facial telethermography, Infrared thermography, Liquid crystal thermography, Telethermography.

**INTRODUCTION:**

Heat has a profound cognitive impact on humans.<sup>1</sup> A strong relationship exists between life and body temperature where moderate body temperature associates with normal health and severe body temperature associates with disease process.<sup>2</sup> Human skin is very sensitive and is remarkably good absorber and emitter of infrared radiation having an emissivity of 0.97 in the infrared spectrum.<sup>3</sup> As the quantity of blood circulation at various parts of the skin differs, the temperature changes accordingly. Therefore, diseases affect the flow of blood may result in the irregularities in distribution of temperature. These changes can be evaluated by a method known as Thermography.

Thermography is an imaging technique that allows to record the distribution of thermal radiation emitted by the surface of the body and transforming it through the laws of physics into temperature values.<sup>4</sup> Earlier to thermography, an array of devices have been employed such as thermometers, thermistors, thermocouples and liquid crystal imaging systems for determining the body temperature.<sup>5</sup> Compared to other imaging modalities thermography is characterized as not being invasive and not having side effects such as exposure to nuclear radiation for the accuracy of diagnosis through immediate results by recording a simple image that resembles a photograph.<sup>5</sup>

**HISTORY:**

The diagnostic application of infrared thermography began in Germany, in 1952 followed by the medical association of thermography in 1954 which was operating as German Society for Thermography and Regulation Medicine.<sup>6</sup> (Table:1)

Table 1: Reported Research On Thermography.

S.No	Year	Scientist	Research
1.	400 BC	Hippocrates	Human body temperature was used as a medical diagnostic sign.

2.	130-210 AD	Galen	Body heat is produced by the bio-combustion of food. Galen theory: Feedback between sensory and motor nerves, today it is known as a primary mechanism of thermoregulators.
3.	1592	Galileo	Invented the semi-quantitative air thermometer called Galileo's thermoscope, which exhibits temperature changes.
4.	1611	Sanctorius	Modified the thermoscope and invented a thermometer, which demonstrated the variation in core temperature of humans in both health and diseases.
5.	1872	Wunderlich	He introduced fever measurements as a routine clinical diagnostic procedure.
6.	1928	Czerny	He documented the first infrared image of a human subject in Frankfurt.
7.	1931	Hardy	Initiated the modern era of telethermometry. He described the physiological role of infrared emission of human skin and its potential diagnostic importance.
8.	1951	Schwamm and Reeh	A single-detector infrared bolometer for sequential thermal measurement of defined regions of the human body surface for diagnostic purposes. <sup>4,6,7</sup>

**PRINCIPLE:**

The thermography principle is the variation in amount of blood circulation at different layers of skin, the temperature changes accordingly. Consequently, disorders that affect the blood flow too result in abnormalities in temperature



## EXPRESSIONS MATTER IN PROSTHODONTICS – A NARRATIVE REVIEW

Sravanthi T.L.G., Rao BL., Sudheer K., Monika.P.K., SaiKumar.C D and Bhargavi.B

Department of Prosthodontics, Lenora Institute of Dental Sciences, N.T.R. University, Andhra Pradesh

### ARTICLE INFO

**Article History:**

Received 13<sup>th</sup> November, 2020

Received in revised form 11<sup>th</sup>

December, 2020

Accepted 8<sup>th</sup> January, 2021

Published online 28<sup>th</sup> February, 2021

### ABSTRACT

A study of normal facial landmarks is necessary before attempting to achieve the goal of natural and pleasing expression. The prosthodontist has more to do with the beauty of a face than any other beautician. Mouth plays an important role in facial expressions.

**Key words:**

Facial muscles, prosthodontics, expressions.

Copyright©2021 Sravanthi T.L.G et al. This is an open access article distributed under the Creative Commons Attribution License, which permits unrestricted use, distribution, and reproduction in any medium, provided the original work is properly cited.

### INTRODUCTION

Mouth is not the initiator of mastication or the finalizer of speech but is the most versatile of the expressive features of a human beings. Mouth reflects a wide range of emotions. The lips, sometimes termed the mouth's curtains, actually become the main actors in facial expression.

**Muscles of facial expression:** These muscles generally donot insert into the bone. They are subcutaneous in position and produces wrinkles or fold in the skin when they contract. They are responsible for expression of different emotions of an individual. These are also called as mimetic muscles. Their movements are controlled by the muscular activity affecting the mouth's corners. The five types of movements which occur in the lip area are (1) elevation, (2) depression, (3) retraction, (4) compression, and (5) protrusion. Each is the result of the contraction and relaxation of groups of muscles.

Consequently, functional consideration of such actions should be in terms of the groups of muscles producing the action rather than in terms of individual muscles. Elevation of the lips is produced by the zygomaticus, quadratus labii superioris, 2nd caninus muscles. The lips are drawn downward by the triangularis, quadratus labii inferioris, and platysma muscles. Retraction of the lips is produced by the zygomaticus, risorius, platysma, triangularis, and buccinator. The chief compressors of the lips are the orbicularis oris, incisivi labii superioris and inferioris, mentalis, and orbicularis oris. Now, changing these group of actions will be converted into facial expressions. The lips are stretched and drawn against the teeth and tend to part and open the mouth.

\*Corresponding author: Sravanthi T.L.G

Department of Prosthodontics, Lenora Institute of Dental Sciences, N.T.R. University, Andhra Pradesh

The degree of the opening varies with the individual or the depth of emotion expressed. True laughter occurs when the orbicularis oris is completely and involuntarily inhibited. As such there is no literature evidence is available on the facial expressions and prostheses.

Hence, the aim of this narrative review is to highlight the different facial musculature and their role in the success of prosthodontic treatments.

### DISCUSSION

The prosthodontic significance of a smile is the recognition that if one part of the intricate complex which produces smiling is out of position, this affects all of the other components which make up the smile. With the elevation of the maxillary lips and the retraction of the corners of the mouth, the lips are drawn against the teeth, and the placing of these teeth becomes extremely important in forming the backdrop for the smile. If the teeth are placed too far labially, the orbicularis oris is stretched, and the modioli are positioned too far anteriorly so that they are prevented from moving in the positions they were accustomed to when natural teeth were present. This stretching effect of the lips against the teeth also tends to exert a dislodging force on the maxillary denture.

Sometimes, cheek plumpers are placed in maxillary dentures near the reflective borders in an effort to raise the corners of the mouth.

An increase or decrease in the vertical dimension of occlusion can also cause strained maxillomandibular relationships, which result in damaging effects on residual ridges and distortion of facial structures.



**Awareness of Prosthodontic Treatment in the General Population of the East-Godavari District**

<sup>1</sup>Dr. G.V.R.S.R. Krishna Teja, <sup>2</sup>Dr. B.L. Rao, <sup>3</sup>Dr. T.S.V. Satyanarayana, <sup>4</sup>Dr. T.L.G. Sravanthi, <sup>5</sup>Dr. K. Aditya, <sup>6</sup>Dr. P.K. Monika

<sup>1,4,5,6</sup>Postgraduate student, Department of Prosthodontics, Lenora Institute of Dental Sciences, NTR University, Andhra Pradesh.

<sup>2</sup>Professor & Head, Department of Prosthodontics, Lenora Institute of Dental Sciences, NTR University, Andhra Pradesh.

<sup>3</sup>Reader, Department of Prosthodontics, Lenora Institute of Dental Sciences, NTR University, Andhra Pradesh.

**Corresponding Author:** Dr. G.V.R.S.R. Krishna Teja, Postgraduate student, Department of Prosthodontics, Lenora Institute of Dental Sciences, NTR University, Andhra Pradesh.

**Citation of this Article:** Dr. G.V.R.S.R. Krishna Teja, Dr. B.L. Rao, Dr. T.S.V. Satyanarayana, Dr. T.L.G. Sravanthi, Dr. K. Aditya, Dr. P.K. Monika, "Awareness of Prosthodontic Treatment in the General Population of the East-Godavari District", IJDSIR- May - 2021, Vol. – 4, Issue - 3, P. No. 532 – 542.

**Copyright:** © 2021, Dr. G.V.R.S.R. Krishna Teja, et al. This is an open access journal and article distributed under the terms of the creative commons attribution noncommercial License. Which allows others to remix, tweak, and build upon the work non commercially, as long as appropriate credit is given and the new creations are licensed under the identical terms.

**Type of Publication:** Original Research Article

**Conflicts of Interest:** Nil

**Abstract**

**Aim:** To assess the awareness of prosthodontic treatment in the general population of East-Godavari district.

**Objective:** To assess the awareness of prosthodontic treatment in the general population of the East-Godavari district.

**Material and methodology:** A cross-sectional survey was carried out among general population (public) of the East-Godavari district with a sample size of 300. A self-designed questionnaire form was made to fill to assess the awareness on Prosthodontic treatments. Data was analyzed using the software SPSS version 23.0. Descriptive statistics were generated. Chi square test was applied for age and gender response comparison. A p-value of <0.05 was kept as statistically significant.

**Results:** Only 46% of the subjects were aware of dental implant treatment. 34% were aware of replacement of lost part by a prosthodontist; and 30% were aware that cleft palate treatment could be performed by a prosthodontist. When results were compared between different age groups, subjects between the age group of 25-35 years showed more awareness among prosthodontic treatments compared to other age groups. There is significantly less awareness of prosthodontic treatments in the general population of the East-Godavari district.

**Conclusion:** Even though with the increase in the number of dental clinics and dentists, there is still a lack of complete awareness about the various kinds of treatments a prosthodontist can perform.

*Corresponding Author: Dr. G.V.R.S.R. Krishna Teja, ijdsir, Volume – 4 Issue - 3, Page No. 532 - 542*



## Armamentarium for Reduction of Transmission of COVID-19 Infection in Dental Operatory

Parvathi PSHL<sup>1</sup>, Rao BL<sup>2</sup>, Sruthi YSS<sup>3</sup>, Vinay Kumar P<sup>4</sup>, Chakradhar V<sup>5</sup>.

<sup>1</sup> Postgraduate Student, Department of Prosthodontics, Lenora Institute of Dental Sciences.

<sup>2</sup> Professor & Hod, Department of Prosthodontics, Lenora Institute of Dental Sciences.

<sup>3</sup> Postgraduate Student, Department of Prosthodontics, Lenora Institute of Dental Sciences.

<sup>4</sup> Postgraduate Student, Department of Prosthodontics, Lenora Institute of Dental Sciences.

<sup>5</sup> Postgraduate Student, Department of Prosthodontics, Lenora Institute Of Dental Sciences

### ABSTRACT

The Pandemic of Novel Corona Virus Disease which emerged in December 2019 in WUHAN city is having an overshadowing impact on everyone's life. Its mode of spread is primarily through droplets of saliva or discharge from the nose when an infected person coughs or sneezes. Research labs are joining forces to find a therapy and a preventive vaccine. Preventive and extraordinary safety measures are crucial to reducing the spread of SARS-CoV-2 (severe acute respiratory syndrome coronavirus 2) among health care professionals (HCP). HCP performing or assisting aerosol-generating procedures are classified as 'very high exposure risk' workers. Dentists are one among higher risk HCP as they deal with oral cavity problems. This is because most of the procedures are involved with aerosol production in dentistry and saliva is the best medium for the dwelling of Covid-19. So, along with the use of standard preventive measures in reducing the transmission of COVID -19 it is essential for dental offices to change the operating modes. As we all know 'Prevention is better than cure' In this article, we reviewed auxiliary armamentariums required for prevention of transmission of Covid-19 infection to be used by dental health care professionals while providing urgent dental care to the patients. Currently, in the absence of a rapid diagnostic device with high sensitivity/ specificity and without an effective therapy or vaccine against SARS-CoV2, it is strongly recommended to treat each patient as a COVID-19 positive. So that Appropriate safety measures will protect both dental professionals and patients in transmitting this pandemic disease.

### Key words:

COVID-19 transmission, infection control, armamentarium, sanitizer dispensers, masks.

### Article History:

Received On: 08.04.2020

Revised On: 20.06.2020

Accepted On: 29.06.2020


### \*Corresponding Author

Name: Parvathi PSHL

Email: harika.knp4@gmail.com

DOI: <https://doi.org/10.37022/wjcmpr.vi.146>

This article is licensed under a Creative Commons Attribution-Non Commercial 4.0 International License. Copyright © 2020 Author(s) retain the copyright of this article.



### INTRODUCTION

Corona virus disease 2019 (COVID-19) clinically manifest as the severe acute respiratory syndrome coronavirus 2 (SARS-COV-2) [1]. dental professionals are at greater risk as their treatment deals with oral cavity problems and saliva is the best medium for dwelling of COVID-19 viruses. Dental patients and professionals are at high risk to expose covid -19 infections, because of Dental procedures using drills or ultrasonic devices cause aerosol release, thus, most often exposure to saliva (droplets, aerosols), blood, working position with patients, face to face communication can spread disease and also contaminates the dental clinical environment [1 -6].

The routes of transmission of COVID-19 in dental practice are:

1. airborne spread
2. Contact spread
3. contaminated surface spread

Although many routine precautionary measures to reduce the transmission of COVID-19 infection; there are some other armamentarium required for prevention of transmission of COVID-19 infection. In this article we discussed various

auxiliary armamentarium required for prevention of transmission.

### 1. AUTOMATIC HAND SANITIZER DISPENSERS [7]

Generally, manually operated hand sanitizers were dispensed in dental clinical premises. [Figureure 01] In this type, the risk of contaminated surfaces can be a potential source of corona virus transmission. Therefore, electrically operated with sensor attached automatic hand sanitizer dispensers is more advantageous.



Figure 01

<https://doi.org/10.46344/JBINO.2021.v10i2b.07>

## PROSTHODONTIC MANAGEMENT OF MID- FACIAL DEFECT – A CASE REPORT

Sruthi YSS<sup>1</sup>, Rao BL<sup>2</sup>, Satyanarayana S V Tammlneedi<sup>3</sup>, Pallavi C<sup>4</sup>

1. Postgraduate student, Department of prosthodontics, Lenora institute of dental sciences
2. Professor & Head, Department of prosthodontics, Lenora institute of dental sciences
3. Reader, Department of prosthodontics, Lenora institute of dental sciences
4. Senior Lecturer, Department of Prosthodontics, Sree Sai dental college & research institute.

### ABSTRACT

Any maxillofacial deformity lowers the person's quality of life by affecting them in all grounds of life physically, psychologically, and socially. Rehabilitation of patients with these deformities is of great challenge to the Prosthodontist because it is the esthetics that has to be achieved, giving equal importance in these cases and the function. This case report illustrates maxillofacial prosthetic rehabilitation of significant midfacial defect, including orbit and its contents, zygoma, soft tissues, including half of the nose, cheeks of the right side orofacial communication, which resulted from resection of mucoepidermoid carcinoma. Various retentive aids were utilized, such as ear lobe of spectacles, magnets, adhesives, and acrylic to enhance the retention and provide the near to natural appearance and functioning.

**KEYWORDS:** Facial defect, Facial prosthesis, Silicone, Mucoepidermoid carcinoma, Prosthodontist, Magnets



**Journal of Prosthodontics Dentistry**  
**An Official Publication of Bureau for Health & Education Status Upliftment**  
 (Constitutionally Entitled As Health-Education, Bureau)

## Craft of Choosing A Prime Luting Agent

Parvathi PSHL<sup>1</sup>, Rao BL<sup>2</sup>, Satyanarayana TSV<sup>3</sup>, Sruthi YSS<sup>4</sup>, Padmini D<sup>5</sup>, Chakradhar V<sup>6</sup>

1. Postgraduate Student, Department of Prosthodontics, Lenora Institute of Dental Sciences
2. Professor & HOD, Department of Prosthodontics, Lenora Institute of Dental Sciences
3. Reader, Department of Prosthodontics, Lenora Institute of Dental Sciences
4. Senior lecturer, Department of Prosthodontics, Lenora Institute of Dental Sciences
5. Postgraduate Student, Department of Prosthodontics, Lenora Institute of Dental Sciences
6. Postgraduate Student, Department of Prosthodontics, Lenora Institute of Dental Sciences

**Email Id:** [serviceheb@gmail.com](mailto:serviceheb@gmail.com)

### Abstract:

The longevity of the fixed partial denture depends on the type of luting cement used. Whereas the selection of the luting agent is dependent on the specific clinical situation, the type of restoration utilized, and the physical, biologic, and handling properties of the luting agent. The primary purpose of the luting procedure is to achieve a durable bond and to have an excellent marginal adaptation of the luting material to the restoration and tooth. There are varieties of luting agents available, from conventional water-based to newest adhesive resin cements. However, no single luting agent is capable of meeting all the stringent requirements. The introduction of adhesive resin systems has completely changed the face of fixed prosthodontic practice leading to increased use of bonded all-ceramic crowns and resin-retained fixed partial dentures. The purpose of the article is to provide a discussion that includes a clinical perspective and type of restoration-based selection of luting agents.

**Keywords:** Dental luting cements, GIC, Luting cements, Provisional and Definitive luting cements, Resin cements, Resin-modified luting cements.

Access this Article Online

Website: <http://heb-nic.in/jopd>

Received on 07/04/2021

Accepted on 22/04/2021 © HEB All rights reserved

Quick Response Code:







MASTERY ON BALANCED OCCLUSION

Sruthi YSS<sup>1</sup>, Rao BL<sup>2</sup>, Dr. Satyanarayana S V Tammineedi<sup>3</sup>, Chakradhar V<sup>4</sup> and Parvathi PSHL<sup>5</sup>

<sup>1</sup>Postgraduate Student, Department of Prosthodontics, Lenora Institute of Dental Sciences

<sup>2</sup>Professor & Head, Department of Prosthodontics, Lenora Institute of Dental Sciences

<sup>3</sup>Reader, Department of Prosthodontics, Lenora Institute of Dental Sciences

<sup>4</sup>Postgraduate Student, Department of Prosthodontics, Lenora Institute of Dental Sciences

<sup>5</sup>Postgraduate Student, Department of Prosthodontics, Lenora Institute of Dental Sciences

ARTICLE INFO

Article History:

Received 4<sup>th</sup> February, 2020

Received in revised form 25<sup>th</sup>

March, 2020

Accepted 23<sup>rd</sup> April, 2020

Published online 28<sup>th</sup> May, 2020

Key words:

occlusion, balanced occlusion, hanau quint, compensating curves, artificial dentition

ABSTRACT

The success of any prosthesis depends how well it is into function. The function of a prosthesis is to help in mastication, speech, esthetics without effecting the neuromuscular system. Occlusion is the main determinant of the functioning of prosthesis. Occlusion has been, and still is to some extent, a controversy issue in what is now called conventional removable and fixed prosthodontics. The range of opinion in the dental profession as to the importance of occlusion is enormous. The aim of this paper is to bring out the role of balanced occlusion in complete denture and factors influencing it.

Copyright©2020 Sruthi YSS et al. This is an open access article distributed under the Creative Commons Attribution License, which permits unrestricted use, distribution, and reproduction in any medium, provided the original work is properly cited.

INTRODUCTION

According to GPT-9,<sup>1</sup> Occlusion is defined as the static relationships between the incising or masticating surfaces of maxillary and mandibular teeth or tooth analogues. But teeth either natural or artificial are not immobile so occlusion can never be considered a purely static relationship. The word "Articulation" refers primarily to the dynamic movements of the teeth in relation to each other. It also refers joint relationships, relationships of jaws / casts, the arrangement of teeth and enunciation of speech.<sup>1</sup>Term occlusion is derived from the Latin word, "occlusio" defined as the relationship between all the components of the masticatory system in normal function, dysfunction and parafunction. An ideal occlusion is the perfect interdigitation of the upper and lower teeth, which is a result of developmental process consisting of the three main events, jaw growth, tooth formation and eruption occlusal development can be divided into the following development periods: neo-natal period. (lasts up to 6 months after birth). primary dentition period (from around the 6<sup>th</sup> month to 6 years) mixed dentition period (around 6 years - 12 years) permanent dentition period (12 years onwards).<sup>1,2</sup> Restoring a completely edentulous condition is entirely different from restoring a partially edentulous condition as there are no teeth to guide in completely edentulous state. This difference or difficulty in treating a completely edentulous

patient is because of the differences in the natural and artificial dentition. (Table 1).

Table 1 Differences between natural and artificial dentition:<sup>3,4,5,6</sup>

Natural dentition	Artificial dentition
Natural teeth function independently & each tooth disperses the occlusal load	Artificial teeth functions as a group & the occlusal loads are not individually managed
Malocclusion can be non-problematic for long time	Malocclusion poses immediate drastic problems
Non-vertical forces are well tolerated	Non-vertical forces damages the supporting tissues
Incising doesnot affect the posterior teeth (chritsensens phenomeon)	Incising will lift the posterior part of denture
2 <sup>nd</sup> molar area is the favored area for heavy mastication & better	Heavy mastication over the 2 <sup>nd</sup> molar area can tilt or lift the denture base
Bilateral balance is not necessary and usually considered as hinderance	Bilateral balance is mandatory to stabilize the denture
Proprioceptive impulses to avoid occlusal pre-maturities. This helps patient to have habitual occlusion away from centric relation	There is no feedback and denture rests in centric relation. Any pre-maturities can shift the base.
Forces of mastication 5 to 175 pounds	Incisor area - 9pound Premolar & molar area - 22-24 pounds

Concepts of complete denture occlusion (balanced occlusion)

Balanced occlusion is defined as "The bilateral, simultaneous occlusal contact of the anterior and posterior teeth in excursive movements." (GPT- 9)<sup>1</sup>

\*Corresponding author: Sruthi YSS

Postgraduate Student, Department of Prosthodontics, Lenora Institute of Dental Sciences



## KEEPING IN TIME – TILT OF THE CAST : A REVIEW

## Dental Science

<b>Dr. Y. Satya Sai Sruthi</b>	Postgraduate Student, Department Of Prosthodontics, Lenora Institute Of Dental Sciences, Andhra Pradesh
<b>Dr. Lakshmana Rao Bathala*</b>	Professor & Head , Department Of Prosthodontics, Lenora Institute Of Dental Sciences, Andhra Pradesh *Corresponding Author
<b>Dr. R. Narendra Kumar</b>	Professor , Department of prosthodontics, Lenora institute of dental sciences, Andhra Pradesh
<b>Dr. Jibi Joseph</b>	Postgraduate Student, Department Of Prosthodontics, Lenora Institute Of Dental Sciences, Andhra Pradesh
<b>Dr. Nibha Kumari Singh</b>	Reader , Department Of Prosthodontics, Lenora Institute Of Dental Sciences, Andhra Pradesh.

## ABSTRACT

**PURPOSE:** This study was aimed to review the different methods for reproduction of tilt of a cast on a surveyor.  
**METHODOLOGY:** An electronic literature search was conducted through Medline via Pubmed, Wiley Online library, Ebscohost, Science Direct, as well as the Google Scholar for article published between October 1973 and March 2016, using the key words, tilt of cast, surveying, path of insertion, preservation of tilt and reproduction of tilt. A total of 20 articles were found out of these 8 were not related to present search and hence were excluded from the study. Finally 12 articles were found to be relevant.  
**RESULTS:** All the techniques given by the different authors are having both advantages and disadvantages.  
**CONCLUSION:** The path of insertion of a removable partial denture must be determined during treatment planning and permanently recorded on the cast. Literature has suggested several methods for the reproduction of cast tilt on surveyors.

## KEYWORDS

Tilt Of The Cast, Surveying, Preservation Of Tilt, Reproduction Of Tilt, Path Of Insertion.

## MAINTEXT

## INTRODUCTION:

Removable dental prosthesis (RDP) is still considered a treatment of choice for partially edentulous patients when fixed dental prosthesis or implant supported restorations are not possible because of technical, biologic conditions and financial concerns. Clinician should consider biologic and biomechanical elements in RDP treatment planning. Appropriate analysis of the diagnostic cast is one of the initial and fundamental steps in planning RDP.<sup>1</sup>

Surveying the diagnostic cast allows the clinician to study and design an adequate planning for RDP framework.<sup>1,2</sup> Determining the best path of insertion and removal is an essential step in RDP's planning. The path of insertion is determined with the surveyor regards to height of contours, guiding planes, interferences and esthetics for RDPs.<sup>1,2,3</sup>

The path of insertion should be exactly recorded on the study cast in order to be transferred into definitive cast or working cast. This also allows the dental technician to reposition the casts on the surveyor.<sup>1,2,3</sup>

The tilt of the cast determines at what angle the partial denture will seat over the remaining teeth. This angle is referred to as the path of placement or path of insertion. It may be impossible to achieve the optimum among all factors which affect the path of insertion as one or other may need to be compromised. It is only clinical judgment which finally dictates and may be compromised without sacrificing the quality of service. The four factors that should be considered before final path of placement are retentive undercut, interferences, aesthetics and guiding planes. The tilt of a cast must be recorded so that it can be easily transferred from the cast holder of the surveyor and subsequently reproduce it in its original position in designing and fabrication of a removable partial denture, so the main purpose of the article is to review the different methods for preservation and reproduction of the cast of the cast in fabrication of Cast Partial Denture (CPD).<sup>1,2</sup>

## METHODOLOGY:

An electronic literature search was conducted through Medline via Pubmed, Wiley Online library, Ebscohost, Science Direct, as well as the Google Scholar for article published between October 1973 and

March 2016, using the key words, tilt of cast, surveying, path of insertion, preservation of tilt and reproduction of tilt. A total of 20 articles were found out of these 8 were not related to present search and hence were excluded from the study. The articles which are published in English language only considered. Finally 12 articles were found to be relevant. Standard textbooks were also referred. All the articles were followed for the technique mentioned and the advantages and disadvantages of the technique.

## RESULTS:

The techniques mentioned are having both the advantages and disadvantages. Some of the methods mentioned are technique sensitive and required special equipment other than the surveyor and the things that are available in the laboratory, and even difficult for the technician to follow. Few methods used the materials that are available in the laboratory but need little time to fabricate them [Table 1].

## DISCUSSION:

The Surveyor plays a cardinal role in the designing of a CPD. The GPT 9 defines a surveyor as a paralleling instrument used in the construction of a dental prosthesis to locate and delineate the contours and relative positions of abutment teeth and associated structures. As per literature a Surveyor is used in the following manner in the designing of a CPD<sup>2</sup>

1. Surveying the diagnostic cast,
2. Contouring wax patterns,
3. Surveying ceramic veneer crowns,
4. Machining cast restorations,
5. Placing intra coronal retainers and internal rest seats,
6. Surveying the master cast.

As the listing reveals tripoding is one important component of surveying. Thus although tripoding is not a component of surveying per se it does play an important role in the overall procedure of surveying as tripoding allows the reorientation of a cast on the tripoding table to a pre-determined path of insertion even after the cast has been moved from the surveying table. This enables multiple users to access the instrument which otherwise would be inaccessible till an individual user has completed the entire design process. This article focused on the variety of methods adopted to perform tripoding obtained from a literature review from [oldest year to current one],



## ANTIOXIDANTS IN ORAL DISEASES: A REVIEW

## Dental Science

<b>Dr. N. Harika*</b>	Post Graduate Student, Dept. of Oral Medicine & Radiology, Lenora Institute of Dental Sciences, Rajahmundry. *Corresponding Author
<b>Dr. K. Sridevi</b>	Professor, Dept. of Oral Medicine & Radiology, Lenora Institute of Dental Sciences, Rajahmundry.
<b>Dr. B. Krishnaveni</b>	Reader, Dept. of Oral Medicine & Radiology, Lenora Institute of Dental Sciences, Rajahmundry.
<b>Dr. N. Prasanth Kumar</b>	Senior Lecturer, Dept. of Oral Medicine & Radiology, Lenora Institute of Dental Sciences, Rajahmundry.
<b>Dr. G. Mounika</b>	Post Graduate Student, Dept. of Oral Medicine & Radiology, Lenora Institute of Dental Sciences, Rajahmundry.

## ABSTRACT

Antioxidants are compounds that destroy the free radicals in the body, thereby preventing harmful oxidation-reduction reactions. Free radicals are chemical species possessing an unpaired electron that can be considered fragments of molecules and generally very reactive. They are produced continuously in cells either as accidental by-products of metabolism or deliberately during, phagocytosis. However, excess free radical production originating from endogenous or exogenous sources might play a role in many diseases. Antioxidants are man-made or natural substances that may prevent or delay some types of cell damage. Antioxidants are crucial for maintaining optimum health and well-being. Free radicals have been implicated in numerous oral diseases like leukoplakia, Periodontal diseases, and oral cancer.

## KEYWORDS

Antioxidant, Periodontal disease, oral cancer, leucoplakia.

## INTRODUCTION:

An antioxidant is "any substance that, when present in low concentrations compared to that of an oxidizable substrate, significantly delays or inhibits the oxidation of that substrate."<sup>1</sup> The physiological role of antioxidants, is to prevent damage to cellular components arising as a consequence of chemical reactions involving free radicals.<sup>1</sup> A free radical is any molecular species capable of independent existence that contains an unpaired electron in an atomic orbital—the presence of unpaired electron results in certain common properties shared by most radicals. Many radicals are highly reactive and can either donate an electron to or extract an electron from other molecules, therefore behaving as oxidants or reductants. The most important free radicals in many disease states are oxygen derivatives, particularly superoxide and the hydroxyl radical. Radical formation in the body occurs by several mechanisms involving both endogenous and environmental factors.<sup>1</sup> Antioxidants are nutrients as well as enzymes that assist in chemical reactions.<sup>2</sup>

## HISTORY OF ANTIOXIDANTS:

Duclaux first demonstrated the participation of atmospheric O<sub>2</sub> in the oxidation of free fatty acids. The first reports on antioxidants employed for food lipids were about using natural sources. Olcott and Mattill first reported antioxidant synergism in food. This was significant in achieving oxidative stability in food by using various antioxidants found in the unsaponifiable fraction of oils. Recently, Ferreira et al. studied the prophylactic effect of topical Vitamin E in head and neck cancer patients to prevent radiation-induced oral mucositis.<sup>3</sup>

## GENERATION OF FREE RADICALS AND OXIDANTS:

Free radicals are chemically active atoms with a charge due to an excess or a deficient number of electrons. Free radicals containing oxygen, known as reactive oxygen species (ROS),<sup>4</sup> and reactive nitrogen species (RNS) are the most biologically significant free radicals. ROS includes the radicals superoxide and hydroxyl. Free radicals and other reactive oxygen species are derived from normal essential metabolic processes in the human body or external sources such as exposure to X-rays, ozone, cigarette smoking, air pollutants, and industrial chemicals. Because they have one or more unpaired electrons, free radicals are highly unstable. They scavenge the body to grab or donate electrons, thereby damaging cells, proteins, and DNA.<sup>2</sup>

Superoxide (O<sub>2</sub><sup>-</sup>) is produced by the addition of a single electron to oxygen, and several mechanisms exist by which superoxide can be produced in vivo.<sup>5</sup> Several molecules, including adrenaline, flavine

nucleotides, thiol compounds, and glucose, can oxidize in the presence of oxygen to produce superoxide. These reactions are greatly accelerated by the presence of transition metals such as iron or copper. The electron transport chain in the inner mitochondrial membrane performs the reduction of oxygen to water. During this process, free radical intermediates are generated, which are generally tightly bound to the transport chain's components. However, there is a constant leak of a few electrons into the mitochondrial matrix, resulting in superoxide formation.<sup>6</sup> The activity of several other enzymes, such as cytochrome p450 oxidase in the liver and enzymes involved in the synthesis of adrenal hormones, also results in the leakage of a few electrons into the surrounding cytoplasm and hence superoxide formation. There might also be continuous superoxide production by vascular endothelium to neutralize nitric oxide, production of superoxide by other cells to regulate cell growth and differentiation, and superoxide production by phagocytic cells during the respiratory burst.<sup>7</sup>

Any biological system generating superoxide will also produce hydrogen peroxide as a result of a spontaneous dismutation reaction. Several enzymatic reactions, including those catalyzed by glycolate D-amino acid oxidase, might produce hydrogen peroxide directly.<sup>8</sup> Hydrogen peroxide is not a free radical itself but is usually included under the general heading of reactive oxygen species. It is a weak oxidizing agent that might directly damage proteins and enzymes containing reactive thiol groups. However, its most vital property is the ability to cross cell membranes freely, which superoxide generally cannot do. Therefore, hydrogen peroxide acts as a conduit to transmit free radical-induced damage across cell compartments and between cells.

In the presence of hydrogen peroxide, myeloperoxidase will generate hypochlorous acid and singlet oxygen, a reaction that plays an important role in the killing of bacteria by phagocytes. The hydroxyl radical (OH<sup>•</sup>), or a closely related species, is probably the final mediator of most free radical-induced tissue damage. All of the reactive oxygen species described above exert most of their pathological effects by giving rise to hydroxyl radical formation.

Although free radical production occurs due to the endogenous reactions described above and plays a vital role in normal cellular function, it is essential to remember that exogenous environmental factors can also promote radical formation. Ultraviolet light will lead to the formation of singlet oxygen and other reactive oxygen species in the skin. Atmospheric pollutants such as ozone and nitrogen dioxide



(RESEARCH ARTICLE)



## Morphometric analysis of foramen magnum using helical computed tomography for gender determination

Nalli Prasanth Kumar <sup>1</sup>, Edara Naga Priyanka <sup>2</sup>, Kolappan R <sup>3,\*</sup>, Rajendran Ganesh <sup>4</sup>, Rajala Sushmitha <sup>5</sup>

<sup>1</sup> Senior Lecturer, Lenora Institute of Dental Sciences, Rajahmundry, Andhra Pradesh, India.

<sup>2</sup> Senior Lecturer, Lenora Institute of Dental Sciences, Rajahmundry, Andhra Pradesh, India.

<sup>3</sup> Siva Sakthi Dental Hospital, Tirunelveli, India.

<sup>4</sup> Assistant Professor in Pediatric and Preventive Dentistry, Al Baha University, Al Baha, Saudi Arabia

<sup>5</sup> Welfare Dental Clinic, Ravulapalem, India.

Publication history: Received on 15 November 2020; revised on 24 November 2020; accepted on 26 November 2020

Article DOI: <https://doi.org/10.30574/wjarr.2020.8.3.0439>

### Abstract

**Background:** The morphometric analysis of foramen magnum (FM) plays a crucial role in forensics and paleontology in identifying the gender of the unknown skeletal fragments. However, the reliability of these parameters vary among populations and races. The present study was conducted to investigate the reliability of the four foramen magnum parameters ie, foramen magnum transverse diameter, foramen magnum sagittal diameter, foramen magnum area and foramen magnum circumference in this native population.

**Methods:** A total of 60 subjects belonging to both genders aged between 20 – 50 years who were undergoing computed tomography (CT) examination of head and neck region were selected for the study. The study sample comprised of 30 males in group A and 30 females in group B. The measurements were obtained from reformatted axial sections using helical CT scan. The FM sagittal diameter (FMSD) and the FM transverse diameter (FMTD) were measured by the greatest anteroposterior dimension and the greatest width of the foramen. The circumference (FMC) and the area (FMA) were obtained after tracing the bony margin of the FM on the CT image using CT workstation.

**Results:** Mean values of all four parameters were found to be significantly higher in males compared to female subjects ( $P < 0.001$ ). Further, the accuracy of sex determination analyzed using the discriminant equation was 70% for males and 80% for females with overall accuracy of 75%. The predictability of gender was higher in female subjects than in male subjects.

**Conclusion:** The dimensions of the foramen magnum can be used in gender determination of skeletal fragments with considerable accuracy. The Helical CT scan plays a pivotal role in providing accurate dimensions of the foramen magnum that could be useful in forensic testing.

**Keywords:** Foramen Magnum; Helical Computed Tomography; Forensics; Discriminant Function Analysis

### 1. Introduction

With the advancement of technology and data collection methods, forensic odontology has advanced through the evolution of mankind [1]. Over the years, forensic odontology has been recognized as a vital science in medico-legal cases and in the identification of dead person. Gender determination plays a crucial role in medicolegal cases especially in cases of natural calamities, mass disasters or crime scenes when body is decomposed and fragmented [2]. However,

\* Corresponding author: Kolappan R  
Siva Sakthi Dental Hospital, Tirunelveli.



## The Authentic Inbred Sheath - "The Immunoglobulin"

Santhi Gorle<sup>1</sup>, Srikanth Adusumilli<sup>2</sup>, Rukmini Jyothirmayee Jakati<sup>3</sup>,  
Rani Ponnaganti<sup>1</sup>, Sahithi Valluripalli<sup>4</sup> and Sanjeev V Jakati<sup>5\*</sup>

<sup>1</sup>Senior Lecturer, KLR Lenora Institute of Dental Sciences, Rajahmundry, India

<sup>2</sup>Professor, Dr Sudha and Nageshwara Rao Siddhartha Institute of Dental Sciences,  
Vijaywada, India

<sup>3</sup>Senior Lecturer, Yogita Dental College and Hospital, Khed Ratnagiri, India

<sup>4</sup>Private Practitioner, Rajahmundry, India

<sup>5</sup>Reader, Yogita Dental College and Hospital, Khed Ratnagiri, India

\*Corresponding Author: Sanjeev V Jakati, Reader, Yogita Dental College and  
Hospital, Khed Ratnagiri, India.

DOI: 10.31080/ASDS.2020.05.1015

Received: December 02, 2020

Published: January 11, 2021

© All rights are reserved by Santhi G., et al.

**Abstract**

Humans have developed a highly specialized defense mechanism system due to continuous stimulation by foreign material from the environment. Immunoglobulins are unique structures in the body which is synthesized by plasma cells and, to some extent, by lymphocytes. They have a significant role in recognizing and protecting the body against foreign material, either present freely in the body fluids or attached to cell surfaces. Besides the plasma, immunoglobulins may be identified in other body fluids or tissues such as urine, spinal fluid, milk, saliva, tears, lymph nodes, and spleen. The plasma cells and lymphocytes produce immunoglobulins at various stages of differentiation. Immunoglobulins represent a heterogeneous population to their Physico-chemical and biological properties. Immunoglobulins are divided into five classes IgG, IgA, IgM, IgD, and IgE, which are classified based on H chains.

**Keywords:** Immunoglobulins; Pathogens; Immunity

**Introduction**

The continuous stimulation by the foreign materials from the environment has made vertebrates to develop a highly specialized system of defense mechanism [1]. Towards the close of the nineteenth century, the humoral basis of immunity was established by demonstrating the introduction of an antigen into an animal. Certain substances called antibodies appeared in the serum and tissue fluids and reacted with antigen specifically in some observable manner. Depending on the observable reaction produced on mixing with antigens, the antibodies were designated as agglutinins, precipitin, and so on. Sera having high antibody levels following infection or immunization, was called 'immune sera'.

Fractionation of immune sera by half-saturation with ammonium sulfate separated serum proteins into soluble albumins and in-

soluble globulins. Globulins could be separated into water-soluble pseudoglobulins and insoluble euglobulins. Most antibodies were found to be euglobulins. Tiselius (1937) separated serum proteins into albumin, alpha, beta, and gamma globulins based on their electrophoretic mobilities. He showed that antibody activity was associated with the gammaglobulin fraction.

WHO in 1964 gave the generic term 'Immunoglobulin' and defined as "Immunoglobulins are proteins of animal origin endowed with known antibody activity and certain proteins related to them by chemical structure and hence antigenic specificity." Immunoglobulins provide structural and chemical concepts, while the term "antibody" is a biological and functional concept. All antibodies are immunoglobulins, but all immunoglobulins may not be antibodies [2]. They have a significant role in recognizing and protecting the body against foreign material, either present freely in the body



## Challenges for dental professionals during COVID-19 pandemic: Are we prepared?

Mukesh Kumar, Truppti P. Sonone<sup>1</sup>, Alok Kumar Shukla<sup>2</sup>, Kumar Tathagat Singh<sup>3</sup>, Jay Kishore<sup>4</sup>, M. Harsha<sup>5</sup>

Department of Conservative Dentistry and Endodontics, Patna Dental College and Hospital, Patna, India, <sup>1</sup>Department of Orthodontics and Dentofacial Orthopaedics, Yerala Dental College, Mumbai, Maharashtra, India, <sup>2</sup>Department of Prosthodontics, Crown and Bridge and Implantology, Dental College Azamgarh, Azamgarh, Uttar Pradesh, India, <sup>3</sup>Department of Oral and Maxillofacial Surgery, Dr. BR Ambedkar Institute of Dental Sciences and Hospital, Patna, India, <sup>4</sup>Department of Oral Pathology and Microbiology Primary Health Centre, Vaishali, Bihar, India, <sup>5</sup>Department of Oral Pathology and Microbiology, Lenoro Institute of Dental Sciences, Rajanagaram, Andhra Pradesh, India

Address for correspondence:  
Dr. Kumar Tathagat Singh,  
Department of Oral and Maxillofacial Surgery,  
Dr. BR Ambedkar Institute of Dental Sciences and Hospital, Patna, Bihar, India.  
E-mail: dr.tathagat@yahoo.co.in

Received: 05-07-2020  
Accepted: 29-07-2020  
Published: 20-05-2021

### Abstract:

**BACKGROUND:** With the emerging knowledge and understanding of novel coronavirus infection, dentists must be capable of resuming their practice with necessary precautions in near future; hence, the aim of the present study was to evaluate the knowledge, attitude, and practices along with felt challenges by the dentists concerning practicing dentistry during pandemic in India.

**MATERIALS AND METHODS:** An online cross-sectional questionnaire study was conducted on the dental practitioners of Uttarakhand, India. The dentists were approached by obtaining their E-mail address from the heads of dental institutions or dental association branches in the state. The knowledge, attitude, and practices along with apparent challenges of practicing during pandemic were assessed using closed-ended questionnaire. The relationship between the mean scores and demographic variables was determined using Student's unpaired t-test by keeping the significance level below 0.05.

**RESULTS:** Out of 759 respondents, a total of 458 respondents were male (60%), whereas 301 (40%) were female. The mean knowledge scores were higher in females ( $11.06 \pm 2.12$ ) compared to males ( $9.72 \pm 4.53$ ), which was statistically significant ( $P < 0.05$ ). The mean practice score was lower in males ( $17.49 \pm 6.47$ ) compared to females ( $19.26 \pm 6.69$ ) and likewise lower scores were seen in graduates compared to specialists and these differences were again statistically significant ( $P < 0.05$ ). Majority of the study participants felt that following various safety guidelines were not feasible (96.97%) and too expensive (96.44%) and considered them as a challenge.

**CONCLUSION:** It is imperative that dentists should be fully prepared before resuming their services and reach the right kind of awareness to limit the spread of the disease.

### Keywords:

COVID-19, dental practice, pandemic, readiness

### Introduction

The COVID-19 is a viral disease affecting the lungs, which might be serious and deadly and has emerged as an exigent calamity for public health across the world.<sup>[1]</sup> It has been designated as a pandemic by the World Health Organization (WHO) on 11 March 2020.<sup>[2]</sup> Apart from the health consequences by the disease itself, this pandemic has even altered the society worldwide, with obligatory lockdowns and social distancing almost

globally, leading to devastating economic effects for various industries and resulted in shutting of factories, stores, and offices.<sup>[1]</sup>

In India also from the time when lockdown measures were announced in March 2020, dental offices have been closed. This has resulted in no income in dental offices from some time and situation for dental practice is still unclear.<sup>[3]</sup>

In delivering a dental service, the foremost significant concern is the spread of novel

This is an open access journal, and articles are distributed under the terms of the Creative Commons Attribution-NonCommercial-ShareAlike 4.0 License, which allows others to remix, tweak, and build upon the work non-commercially, as long as appropriate credit is given and the new creations are licensed under the identical terms.

For reprints contact: WKHLRPMedknow\_reprints@wolterskluwer.com

**How to cite this article:** Kumar M, Sonone TP, Shukla AK, Singh KT, Kishore J, Harsha M. Challenges for dental professionals during COVID-19 pandemic: Are we prepared? J Edu Health Promot 2021;10:128.

# Comparative Evaluation of Efficacy of Kefir Milk Probiotic Curd and Probiotic Drink on *Streptococcus mutans* in 8–12-year-old Children: An *In Vivo* Study

Saida Reddy<sup>1</sup>, Vasepalli Madhu<sup>2</sup>, Rachuri Punithavathy<sup>3</sup>, Martha Satyam<sup>4</sup>, Uday Kumar Chowdary<sup>5</sup>, Raparla Mythraiyee<sup>6</sup>

## ABSTRACTS

**Aim and objective:** To compare the effect of probiotic products in reducing the levels of salivary *Streptococcus mutans* before and after their consumption.

**Materials and methods:** Eighty school children with initial carious lesions in the age group of 8–12 years were selected and divided into four groups. Children in group I (control) were undergone with restorations without supplementation of probiotics. Children in group II (kefir milk), group III (probiotic curd), and group IV (probiotic drink) supplemented 100 mL of their respective probiotics for 1 month. Assessment of saliva sample was done at baseline, 1 hour after administration of probiotics followed by weekly intervals till 1 month.

**Results:** The study showed a marked reduction in colony-forming units (CFUs) at a 1-hour time interval in all four groups when compared to baseline. On the 30th-day, children in group II and group III have shown an equal reduction of CFUs when compared to group IV and group I.

**Conclusion:** Probiotic products like kefir milk and probiotic curd have shown an equal and marked decrease in CFUs when compared to the probiotic drink group.

**Clinical significance:** The administration of probiotics along with dairy products can be used as an adjuvant to routine preventive treatment procedures in the prevention of dental caries along with the remineralization of the demineralized tooth structure.

**Keywords:** ANOVA, Kefir milk, *Post hoc*, Probiotic curd, Probiotic drink, *Streptococcus mutans*.

*International Journal of Clinical Pediatric Dentistry* (2021): 10.5005/jp-journals-10005-1883

## INTRODUCTION

The oral cavity is a complex ecosystem that provides shelter to different species of microflora. The disturbance in the homeostatic condition between the host and microflora results in the progression of oral diseases like dental caries and periodontitis.<sup>1</sup>

Dental caries is a multifactorial disease that occurs predominantly in childhood that interferes with speech, emotional conditions, and nutritional intake, which influences the development of the overall health status of the child.<sup>2</sup> The microflora and the chief pathogenic bacteria present in oral biofilm which causes dental caries is *Streptococcus mutans*.<sup>1</sup> Bacteriotherapy, by probiotics, is an alternative to routine preventive therapies of dental caries that helps to fight against pathogenic bacteria.<sup>3</sup>

The term "probiotics" was coined by Lilley and Stillwell in 1965 means "For life". Probiotics can be defined as "live microorganisms which, when administered in adequate amounts, confers a health benefit on the host"—Food and Agriculture Organization (FAO) and World Health Organization (WHO).<sup>4</sup> *Bifidobacterium* was the first isolated probiotic bacteria.<sup>3</sup> Consumption of probiotics that are available in various forms helps in the prevention of dental caries by competing with the pathogenic bacteria and also helps to modulate the defense mechanism.<sup>4</sup>

## MATERIALS AND METHODS

In this study, the levels of salivary *S. mutans* were compared before and after consumption of probiotic products.

The kefir drink used in this study was homemade. After boiling milk and cooling it at room temperature, 5% of kefir

<sup>1–6</sup>Department of Pedodontics and Preventive Dentistry, KLR's Lenora Institute of Dental Sciences, Rajahmundry, Andhra Pradesh, India

**Corresponding Author:** Saida Reddy, Department of Pedodontics and Preventive Dentistry, KLR's Lenora Institute of Dental Sciences, Rajahmundry, Andhra Pradesh, India, Phone: +91 9491118525, e-mail: saidareddy1994@gmail.com

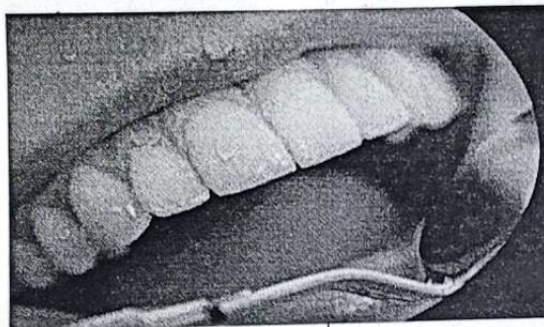
**How to cite this article:** Reddy S, Madhu V, Punithavathy R, et al. Comparative Evaluation of Efficacy of Kefir Milk Probiotic Curd and Probiotic Drink on *Streptococcus mutans* in 8–12-year-old Children: An *In Vivo* Study. *Int J Clin Pediatr Dent* 2021;14(1):120–127.

**Source of support:** Nil

**Conflict of interest:** None

grains (containing *Lactobacillus casei* subsp. *Pseudoplantarum* and *Saccharomyces cerevisiae* and pH = 4) were added. The fermentation was done at 25°C for 12 hours, and then the kefir grains were separated by filtering.

Eighty school-going children of 8–12 years were selected. Permissions were taken from the college and the respective schools to evaluate the children. Selected children were divided into group I (control group), group II (kefir milk group), group III (probiotic curd group), and group IV (probiotic drink group) (Figs 1 to 3). All the initial carious lesions in the included children were restored before the supplementation of probiotics. Children in each group were supplemented with 100 mL of their respective probiotics once daily for 1 month along with the restorations except in group I. All the children were instructed to maintain normal oral hygiene measures and were instructed not to consume any food till 1 hour after taking of probiotic products.



## International Journal of Applied Dental Sciences

ISSN Print: 2394-7489  
ISSN Online: 2394-7497  
IJADS 2021; 7(1): 345-351  
© 2021 IJADS  
[www.oraljournal.com](http://www.oraljournal.com)  
Received: 16-11-2020  
Accepted: 20-12-2020

**S. Srikanth Raju**  
Assistant Professor, Department  
of Pedodontics, Kamineni  
Institute of Dental Sciences,  
Narketpally, Telangana, India

**Srujana MP**  
Associate Professor, Department  
of Pedodontics, Kamineni  
Institute of Dental Sciences,  
Narketpally, Telangana, India

**Dr. M Kiranmayi**  
Associate Professor, Department  
of Pedodontics, Kamineni  
Institute of Dental Sciences,  
Narketpally, Telangana, India

**E Rajendra Reddy**  
Professor and HOD, Department  
of Pedodontics, Kamineni  
Institute of Dental Sciences,  
Narketpally, Telangana, India

**S Sai Divya**  
Consultant Pedodontist,  
Hyderabad, Telangana, India

**P Gowtham**  
Consultant Pedodontist,  
Hyderabad, Telangana, India

**Corresponding Author:**  
**Dr. M Kiranmayi**  
Associate Professor, Department  
of Pedodontics, Kamineni  
Institute of Dental Sciences,  
Narketpally, Telangana, India

### Bio active materials in pediatric dentistry: A review

S Srikanth Raju, Srujana MP, M Kiranmayi, E Rajendra Reddy, S Sai Divya and P Gowtham

DOI: <https://doi.org/10.22271/oral.2021.v7.i1e.1153>

#### Abstract

Remineralization, a natural repair process of carious tooth, is widely followed treatment strategy and requires action of specific agents, which may further assist in preventing formation of newer lesions in the oral cavity. Materials which promote the remineralization are extensively researched and understanding the action of these materials and their dynamics is utmost important.

These bioactive and biomimetic materials have evolved over a period of four decades and have become specialized, easier to manipulate with better properties. A continuous research for further betterment of these materials to meet the increasing clinical and restorative needs should be promoted. The future of dentistry shifts towards use of these biomimetic materials and the aim is to provide the tooth with minerals rather than using chemicals to restore. This article focuses about various bio active materials and their applications in pediatric dentistry.

**Keywords:** Remineralization, bio active materials, pediatric dentistry

#### 1. Introduction

Dentistry is an ever evolving branch with continuous stipulation for advancements in dental materials. From the dawn of history, dental practitioners have been in the quest of ideal restorative dental materials. Initially ideal restorative materials were thought to be biologically inert and biocompatible but in the last two decades bioactive materials seem to be alternative to these inert biocompatible materials [1]. The teeth undergo a constant cycle of demineralization and re-mineralization, but this natural re-mineralization process is inadequate to prevent progression of dental caries. Hence there is a need to supplement the tooth with a biomaterial which is bioactive in nature to re-mineralize, repair or regenerate the tissues of tooth [2]. The term 'Bioactivity' is defined as the ability of a material to elicit a response in a living tissue [3]. Bioactive Material is a material that has the effect on or eliciting a response from living tissue, organisms or cell such as inducing the formation of hydroxyapatite [4]. The ideal properties of bioactive materials are bactericidal and bacteriostatic, sterile, stimulate reparative dentine formation and maintain pulp vitality [5].


Restoratively we use these bio active materials to prevent pulpal death and initiate the formation of a dentinal bridge during direct or indirect pulp capping. Alkalinity is a critical factor that contributes to the effectiveness of bio active materials. The bio active material contributes to pulpal repair not only by stimulating two proteins i.e bone morphogenic protein [BMP] and transforming growth factor-beta [TGF BETA] from the surrounding dentin but also by forming an anti-bacterial seal over the pulp exposure [6].

#### 1.1 Uses of bioactive materials in pediatric dentistry

- Promotes tooth re-mineralization
- As pulp capping material
- For permanent restorations
- In apexification procedure
- Act as scaffold and helps in regeneration of bone tissue.

These bio active materials play a very important role in pediatric dentistry and hence this article emphasize on various bioactive materials and their importance in pediatric dentistry.





## KNOWLEDGE, ATTITUDE AND PRACTICE OF PEDIATRIC DENTISTS IN TREATING THE CHILDREN DURING COVID -19

### Dental Science

<b>E. Rajendra Reddy</b>	Professor & HOD, Dept of Pedodontics, Kamineni Institute of Dental Sciences, Narketpally, Nalgonda.
<b>Srujana M P *</b>	Reader, Dept. of Pedodontics, Kamineni Institute of Dental Sciences, Narketpally, Nalgonda. *Corresponding Author
<b>M. Kiranmayi</b>	Reader, Dept. of Pedodontics, Kamineni Institute of Dental Sciences, Narketpally, Nalgonda.
<b>S. Srikanth raju</b>	Sr. Lecturer, Dept. of Pedodontics, Kamineni Institute of Dental Sciences, Narketpally, Nalgonda.
<b>M. Anupama</b>	post graduate, Dept. of Pedodontics, Kamineni Institute of Dental Sciences, Narketpally, Nalgonda
<b>M. Anil Kumar</b>	MDS, Pediatric Dentist

### ABSTRACT

**Background:** Besides the fact that dentists are more prone to covid-19, pediatric dentists can be considered under further more risk due to their unique characteristic of their working conditions and demands. Upgrading the knowledge and adapting to the new realities has become the high priority and mandatory obligation for pediatric dentists. **Purpose:** To evaluate knowledge, attitude and practice of pediatric dentists in treating the children during COVID -19. **Methods:** This report is based on a questionnaire that was conducted among 100 pediatric dentists. The questionnaire consisting of demographic data and questions aiming to assess the knowledge and change in attitude of pediatric dentists in treating children during this pandemic was prepared and circulated through Google doc among the pediatric dentists. The Results were obtained and the data was tabulated and analysed. **Results:** Out of a total of 100 responses, there were 37 males and 73 females. Qualification distribution revealed 73% as students pursuing post graduation in the department of pediatric dentistry and 27% as practicing pediatric dental specialists (MDS). Majority of pediatric dentists included in the study were following the new COVID norms such as verifying the usage of Arogya sethu app, following social distancing in waiting area, one attendant for one child rule, hand sanitisation temperature check-up and pre procedural mouth rinses. **Conclusion:** Awareness regarding COVID-19 among study participants was good. Pediatric dentists are considering upgrading PPE kits child friendly, restricted play area and updating their knowledge and for proficiency in treating children during this pandemic.

### KEYWORDS

Knowledge, Attitude, Pediatric Dentists, Covid-19

### INTRODUCTION

The novel corona virus SARS-CoV-2 pandemic has affected the world deeply. COVID-19 infection in children has important public health, social, and economic implications. Even though children may have considerably milder symptoms than adults, those infected seem to have the same levels of circulating virus in their body and may be as infectious as adults.<sup>1</sup> Despite robust infection control efforts, nosocomial COVID-19 infections have been reported. Organizations such as the Centers for Disease Control and Prevention (CDC) and the World Health Organization (WHO) have developed preparedness and prevention checklists regarding the containment of the spread of COVID-19, to be used by public and health care professionals.<sup>2,3</sup>

Pediatric dentists form one of the highest risk groups in acquiring and transmitting the infections due to their unique characteristic of their working conditions and needs additional infection control considerations. Hence, as a pediatric dentist one should balance many conflicting demands and needs in both personal and professional front, during this era of COVID-19. For an uneventful practice during this pandemic, pediatric dentists should be equipped with the adequate knowledge of infection control and precautions to be taken in a proficient manner. This questionnaire study is conducted to assess the knowledge and change in attitude of pediatric dentists in treating children during this pandemic.

### METHODOLOGY

The study protocol was approved by institutional ethical committee at Kamineni institute of dental sciences, Sreepuram, Narketpally, Telangana. A sample of 100 dentists which included both the post-graduate students and practicing pediatric dentists was involved in the study. The questionnaire consists of 20 questions. Questions which were developed bearing in mind the present COVID 19 scenario and challenges faced by the pediatric dentists during COVID -19 times. The Google doc had 2 parts. In the first part, participant had to mention his/her demographic data which include their age, experience, gender and email id, and the second part of the questionnaire includes the questions regarding the study. No personal information was included

in the questionnaire. The link was sent to 150 postgraduate students belonging to various colleges in India and practicing dentists in various parts of the country. The questionnaire was circulated by means of Google docs among the study participants, and the data was collected during a 10 days period. A total of 100 postgraduates and practicing pediatric dentists responded and filled out the questionnaire. All the 100 responses which were obtained were considered in the study. Results were obtained and the data was tabulated and analysed.

### RESULTS

The data collected was subjected to Statistical analysis using SPSS software version 19.0. Chi-square analysis was used to analyze statistical significance. Out of a total of 100 responses, there were 37 males and 73 females. Qualification distribution revealed 73% as students pursuing post graduation in the department of pediatric dentistry and 27% as practicing pediatric dental specialists (MDS).

Majority of pediatric dentists included in the study were following the new COVID norms such as verifying the usage of Arogya sethu app, following social distancing in waiting area, one attendant for one child rule, hand sanitization, temperature check and pre procedural mouth rinses.

Out of all participants in the study, 98% of pediatric dentists included in the study had a opinion that PPE had decreased their working efficiency and it also has need to be modified child friendly. About, 61% of sample had denied recalling the patients with space maintainers and orthodontic appliances during this COVID times. Among all the 96% of pediatric dentists are educating the dental assistant, children and parent about COVID 19 precautions. Majority of dentists were unaware of 'two before three after rule' (Table 1). About 44% of clinicians fumigate their clinics on regular basis, 16% every alternate day, 33% only on the days of treatments and 7% once in a week.

### DISCUSSION

The corona virus disease pandemic has had a substantial tandem

## Dental Science

## KEYWORDS:

Unconventional dentures, Special dentures, Complete dentures, Denture characterization, Liquid supported dentures, Reinforced dentures, Hollow dentures.

## BEING UNCONVENTIONAL IN COMPLETE DENTURES: A REVIEW



Volume - 6, Issue - 1, January- 2021

ISSN (O): 2618-0774 | ISSN (P): 2618-0766

**Dr. G.V.R.S.R. Krishna Teja\***

Postgraduate student, Department of Prosthodontics, Lenora Institute of Dental Sciences, NTR University, Andhra Pradesh. \*Corresponding Author  
krishnateja1106@gmail.com

**Dr. B.L. Rao**

Professor & Head, Department of Prosthodontics, Lenora Institute of Dental Sciences, NTR University, Andhra Pradesh.

**Dr. Nibha Kumari Singh**

Reader, Department of Prosthodontics, Lenora Institute of Dental Sciences, NTR University, Andhra Pradesh.

**Dr. T.L.G. Sravanthi**

Postgraduate student, Department of Prosthodontics, Lenora Institute of Dental Sciences, NTR University, Andhra Pradesh.

**Dr. P.K. Monika**

Postgraduate student, Department of Prosthodontics, Lenora Institute of Dental Sciences, NTR University, Andhra Pradesh.

**Dr. K. Aditya**

Postgraduate student, Department of Prosthodontics, Lenora Institute of Dental Sciences, NTR University, Andhra Pradesh.

INTERNATIONAL JOURNAL  
OF PURE MEDICAL RESEARCH



unconventional approach for fabricating complete dentures. So, starring new techniques based on same old fundamentals of prosthodontics is known as the unconventional complete dentures, a manifestation of new vision in prosthesis construction.<sup>3</sup>

## ABSTRACT:

Complete dentures have been and continue to be the standard treatment for edentulous patients, despite the fact that they cannot be considered a replacement for natural teeth. The majority of them seem to have benefited from complete denture therapy and claim that their use has improved their oral and masticatory function. Every case of edentulism, cannot be treated with conventional methods in fabrication of dentures. There is a need for modification in impression procedure or designing the prosthesis to achieve better results in case of compromised situations. This article aims to illustrate clinically important complete denture prosthesis modifications that should be held in mind when such cases arise in everyday practice.

## INTRODUCTION:

Complete loss of teeth leads to significant psychological trauma, loss of masticatory efficiency, loss of the supporting alveolar bone, reduced vertical dimension, lack of support for the facial musculature, and altered jaw functions. Advancing age can lead to exaggerated tissue folds and tissue atrophy, loss of tissue support, increase in the number of creases and folds on the face and loss of tonicity of the muscles and skin.<sup>1</sup>

These changes lead to reduced vertical dimension with a collapsed lower third of the face and affects the overall esthetics of the patient. The external appearance of a complete denture patient is characterized by the presence of deep nasolabial folds, lack of lip support as indicated by the loss of vermilion border and dropping of the corner of the lips.<sup>2</sup>

Complete dentures made in conventional manner proves satisfactory in most of the patients, but in some of the compromised patient's conventional method brings with certain disadvantages. Transforming conventional into unconventional approach is a characteristic feature of ever-growing prosthodontic branch. The increasing demand of patients and revolutionary thought of prosthodontists have led to the outcome of the special, i.e., the

The conventional approach may not fulfill the basic principles of complete denture like retention, stability, support, esthetics and preservation of supporting structures which are of utmost importance for the complete satisfaction of the patient.<sup>1</sup> Hence, it is ideal to use unconventional methods in fabrication of prosthesis. This article aimed to describe a simple, effective and noninvasive treatment alternative to the classical conventional technique in a completely edentulous patient, such as Reinforced complete dentures, Hinged and sectional complete dentures, Liquid supported dentures, Hollow dentures, Salivary reservoir dentures, Cheek plumper's, Modified flange dentures, Labeled dentures, Characterized dentures and Duplicate dentures.

## Reinforced Complete Denture:

Acrylic resins (polymethyl methacrylate [PMMA]) are the most commonly used denture base materials since early 1940's. The properties such as excellent appearance, ease in processing and ease in repair contribute to its success as a denture base material. However, the acrylic resins have the disadvantages like poor strength characteristics which include low impact strength and low fatigue resistance. The fatigue failure occurs when the denture base deforms repeatedly through occlusal forces and impact failure occurs when the dentures are accidentally dropped on a hard surface. Hence, the dentures tend to break during usage in the due course of time. In order to improve the strength of the material, various methods have been proposed like:

- Using Polycarbonates and polyamides as substitutes for PMMA.
- Chemical modification of PMMA by the addition of rubber in the form of butadiene styrene.
- The incorporation of fibers or metal inserts into the denture bases.<sup>1</sup>

## Indications:

- Include high frenal attachment, deep palatal vault, prominent residual ridges, when additional strength is needed because stresses are concentrated over small parts of denture, shallow flat palates and mentally compromised patients who may drop their denture.



## EXPRESSIONS MATTER IN PROSTHODONTICS – A NARRATIVE REVIEW

Sravanthi T.L.G., Rao BL., Sudheer K., Monika.P.K., SaiKumar.C D and Bhargavi.B

Department of Prosthodontics, Lenora Institute of Dental Sciences, N.T.R. University, Andhra Pradesh

### ARTICLE INFO

**Article History:**

Received 13<sup>th</sup> November, 2020

Received in revised form 11<sup>th</sup>

December, 2020

Accepted 8<sup>th</sup> January, 2021

Published online 28<sup>th</sup> February, 2021

### ABSTRACT

A study of normal facial landmarks is necessary before attempting to achieve the goal of natural and pleasing expression. The prosthodontist has more to do with the beauty of a face than any other beautician. Mouth plays an important role in facial expressions.

**Key words:**

Facial muscles, prosthodontics, expressions.

Copyright©2021 Sravanthi T.L.G et al. This is an open access article distributed under the Creative Commons Attribution License, which permits unrestricted use, distribution, and reproduction in any medium, provided the original work is properly cited.

### INTRODUCTION

Mouth is not the initiator of mastication or the finalizer of speech but is the most versatile of the expressive features of a human beings. Mouth reflects a wide range of emotions. The lips, sometimes termed the mouth's curtains, actually become the main actors in facial expression.

**Muscles of facial expression:** These muscles generally donot insert into the bone. They are subcutaneous in position and produces wrinkles or fold in the skin when they contract. They are responsible for expression of different emotions of an individual. These are also called as mimetic muscles. Their movements are controlled by the muscular activity affecting the mouth's corners. The five types of movements which occur in the lip area are (1) elevation, (2) depression, (3) retraction, (4) compression, and (5) protrusion. Each is the result of the contraction and relaxation of groups of muscles.

Consequently, functional consideration of such actions should be in terms of the groups of muscles producing the action rather than in terms of individual muscles. Elevation of the lips is produced by the zygomaticus, quadratus labii superioris, 2nd caninus muscles. The lips are drawn downward by the triangularis, quadratus labii inferioris, and platysma muscles. Retraction of the lips is produced by the zygomaticus, risorius, platysma, triangularis, and buccinator. The chief compressors of the lips are the orbicularis oris, incisivi labii superioris and inferioris, mentalis, and orbicularis oris. Now, changing these group of actions will be converted into facial expressions. The lips are stretched and drawn against the teeth and tend to part and open the mouth.

\*Corresponding author: Sravanthi T.L.G

Department of Prosthodontics, Lenora Institute of Dental Sciences, N.T.R. University, Andhra Pradesh

The degree of the opening varies with the individual or the depth of emotion expressed. True laughter occurs when the orbicularis oris is completely and involuntarily inhibited. As such there is no literature evidence is available on the facial expressions and prostheses.

Hence, the aim of this narrative review is to highlight the different facial musculature and their role in the success of prosthodontic treatments.

### DISCUSSION

The prosthodontic significance of a smile is the recognition that if one part of the intricate complex which produces smiling is out of position, this affects all of the other components which make up the smile. With the elevation of the maxillary lips and the retraction of the corners of the mouth, the lips are drawn against the teeth, and the placing of these teeth becomes extremely important in forming the backdrop for the smile. If the teeth are placed too far labially, the orbicularis oris is stretched, and the modioli are positioned too far anteriorly so that they are prevented from moving in the positions they were accustomed to when natural teeth were present. This stretching effect of the lips against the teeth also tends to exert a dislodging force on the maxillary denture.

Sometimes, cheek plumpers are placed in maxillary dentures near the reflective borders in an effort to raise the corners of the mouth.

An increase or decrease in the vertical dimension of occlusion can also cause strained maxillomandibular relationships, which result in damaging effects on residual ridges and distortion of facial structures.

# Rehabilitation of a Midfacial Defect Using a Two-Piece Maxillofacial Prosthesis: A Case Report

Chakradhar Vadlamudi<sup>1</sup>, Lakshmana Rao Bathala<sup>1</sup>, Satyanarayana S V Tammineedi<sup>1</sup>, Bhargavi Bandlamudi<sup>1</sup>, Parvathi PSHL<sup>1</sup>

1. Department of Prosthodontics, Lenora Institute Of Dental Science, Rajahmundry, IND

Corresponding author: Chakradhar Vadlamudi, vadlamudichakradhar007@gmail.com

Review began 12/24/2021  
Review ended 02/04/2022  
Published 02/11/2022

© Copyright 2022  
Vadlamudi et al. This is an open access article distributed under the terms of the Creative Commons Attribution License CC-BY 4.0., which permits unrestricted use, distribution, and reproduction in any medium, provided the original author and source are credited.

## Abstract

Maxillofacial defects and their rehabilitation are a major concern in this socially productive era. The rehabilitation of these massive defects in the oral and maxillofacial region poses a challenge to the prosthodontist in terms of selection of material, retentive aids, the adaptive capability of the patient, and cost. This case report describes the management of the midfacial defect involving the orbit, zygoma, maxilla, and their soft tissue counterparts with a removable silicone extraoral compartment and an acrylic intraoral compartment, which are retained with strong cobalt samarium magnets, an elastic loop around the occiput, and spectacles. The maxillofacial prosthesis fabricated for this patient restored the patient's facial esthetics, speech, dental articulation, lip support, mastication, and anterior maxillary seal.

Categories: Dentistry

Keywords: neoplasms, speech, maxillofacial prosthesis, mastication, zygoma, midfacial defects

## Introduction

The main etiology of maxillofacial defects is either congenital or acquired. The acquired defects may be caused by different pathologies, radiation burns, trauma, and surgical interventions. Marunick et al. classified midfacial defects into (1) midline defects, including the nose and upper lip, and (2) lateral defects, which include the cheek and orbital portions. Additionally, combinations of these categories can be found [1].

The main goals of prosthetic rehabilitation of maxillofacial defects are to restore the patient's facial esthetics and function of the associated structures and to maintain the integrity of the remaining tissues. These maxillofacial defects are difficult to restore with a prosthesis because of a lack of bony support, scar tissue formation, and their enormous size [2]. Alternative retention strategies include eyeglasses, elastic bands, magnets, adhesives, combinations of the above, and implants [3-7].

The patient treated in this report was previously rehabilitated with a facial prosthesis [8], the main drawbacks of which were color instability and loss of marginal integrity, for which complete refabrication using a two-piece prosthesis was planned. This case report describes the fabrication of a two-piece prosthesis, for which an intraoral prosthesis refabrication was not required. Additionally, an extraoral prosthesis can be refabricated every six months to one year based on the properties of the silicone. This case report differs from previous reports in terms of fabrication technique, iris positioning, and type of auxiliary retention system used. Because the soft tissues had incomplete healing and there was minimal osseous tissue, we selected a removable prosthesis as a treatment option for this clinical situation.

## Case Presentation

A 56-year-old male patient was referred to the Department of Prosthodontics, Lenora Institute of Dental Sciences, Rajahmundry, India, for maxillofacial rehabilitation. Past medical history includes that the patient was known to be diabetic and was under medication and had a history of surgical resection of the right side's hard palate, zygomatic arch, and orbital contents due to mucoepidermoid carcinoma (Figure 1). The patient was previously treated with the obturator that was not retentive enough to hold the massive intraoral and extraoral compartments. Intraoral examination revealed partial maxillary defect and teeth from the lateral incisor to the second molar on the right side of the arch, communicating with the extraoral defect. There is generalized attrition and staining on the maxillary and mandibular teeth. Tongue movements were normal without obstruction. Temporomandibular movements were normal without any deflection or deviation.

### How to cite this article

Vadlamudi C, Bathala L, Tammineedi S, et al. (February 11, 2022) Rehabilitation of a Midfacial Defect Using a Two-Piece Maxillofacial Prosthesis: A Case Report. *Cureus* 14(2): e22138. DOI 10.7759/cureus.22138



ISSN: 0975-833X

Available online at <http://www.journalcra.com>

INTERNATIONAL JOURNAL  
OF CURRENT RESEARCH

International Journal of Current Research  
Vol. 13, Issue, 03, pp.16483-16486, March, 2021

DOI: <https://doi.org/10.24941/ijcr.40888.03.2021>

REVIEW ARTICLE

OPEN ACCESS

## THE PREPONDERANCE OF KENNEDY'S CLASSIFICATION IN THE POPULATION OF GODAVARI DISTRICTS OF ANDHRA PRADESH - A 10 YEAR RETROSPECTIVE STUDY

<sup>1</sup>\*Dr. Santhi, B., <sup>2</sup>Dr. Rao, B.L., <sup>3</sup>Dr. Satyanarayana, T.S.V., <sup>4</sup>Dr. Sravanthi, T.L.G., <sup>5</sup>Dr. Satya Sai Sruthi, Y. and <sup>6</sup>Dr. Parvathi, P.S.H.L.

<sup>1</sup>Postgraduate student, Department of Prosthodontics, Lenora institute of dental sciences, N.T.R., University, Andhra Pradesh; <sup>2</sup>Professor & Head, Department of Prosthodontics, Lenora institute of dental sciences, N.T.R. University, Andhra Pradesh; <sup>3</sup>Reader, Department of Prosthodontics, Lenora institute of dental sciences, N.T.R. University, Andhra Pradesh; <sup>4</sup>Postgraduate student, Department of Prosthodontics, Lenora institute of dental sciences, N.T.R. University, Andhra Pradesh; <sup>5</sup>Senior Lecturer, Department of Prosthodontics, Lenora institute of dental sciences, N.T.R. University, Andhra Pradesh; <sup>6</sup>Postgraduate student, Department of Prosthodontics, Lenora institute of dental sciences, N.T.R. University, Andhra Pradesh

### ARTICLE INFO

#### Article History:

Received 10<sup>th</sup> December, 2020  
Received in revised form  
14<sup>th</sup> January, 2021  
Accepted 11<sup>th</sup> February, 2021  
Published online 17<sup>th</sup> March, 2021

Key Words: Missing

### ABSTRACT

**Aim of the study** - To assess the incidence of different Kennedy's partially edentulous classification in the two Godavari districts and find its relationship with age, gender in 10 years at Lenora Institute of Dental Sciences, Rajanagaram. **Objectives of the study:** To evaluate the incidence of various Kennedy's classification of partial edentulous conditions, assess the gender ratio among the partially edentulous subjects and the epidemiological features of partial edentulousness in the age group 15-30, 31-45, 46-60 and above 60 years at Lenora Institute of Dental Sciences, Rajanagaram based on the post-treatment of Kennedy's classification situations. **Materials and methods:** Examined post-treatment patient records for various Kennedy's classes of partial edentulism in the department of prosthodontics, Lenora Institute of Dental Sciences, Rajanagaram, from 2010 to 2019. **Results:** A total of 18046 post-treated patient records were found, out of which males were 9308 and females 8738. Patients with Kennedy's Class III were found more in number, and class IV was less. **Conclusion:** Kennedy's Class I was less in number than Class III, whereas in females, Class I was more than other classes.

Copyright © 2021. Santhi et al. 2021. This is an open access article distributed under the Creative Commons Attribution License, which permits unrestricted use, distribution, and reproduction in any medium, provided the original work is properly cited.

Citation: Dr. Santhi, B., Dr. Rao, B.L., Dr. Satyanarayana, T.S.V., Dr. Sravanthi, T.L.G., Dr. Satya Sai Sruthi, Y., Dr. Parvathi, P.S.H.L. "The Preponderance Of Kennedy's Classification in the Population of Godavari Districts of Andhra Pradesh - A 10 Year Retrospective study.", 2021. International Journal of Current Research, 13, (03), 16483-16486.

## INTRODUCTION

Edentulism may be considered identical to dental carnage. Among the origin of diversified dental problems, edentulousness consider as a whole situation. Loss of teeth will consider as dental carnage. In India, with varied cultures, contrasting socioeconomic conditions mixed with the non-availability of wealth for dental treatment accord more to pine exclusively to treat partial edentulousness.

\*Corresponding author: Dr. Santhi, B., Postgraduate student, Department of Prosthodontics, Lenora institute of dental sciences, N.T.R., University, Andhra Pradesh.

Due to traditions, faith and habits will lead to the challenges and approach to health care restricted in India's rural population. It is mandatory to classify the partially edentulous arches to visualize the underlying condition and inter-operator communication better. Kennedy's classification of partially edentulous arches is universally acceptable and followed in this study. Edward Kennedy originally proposed Kennedy's category in 1925. Kennedy's type permits immediate visualization of partially edentulous arches and allows early distinction between tooth-supported and tooth tissue-supported cases (Manimaran, 2017; Burt, 1985). A simple estimation of the proportion of partially edentulous persons is a rough



### RESEARCH ARTICLE

#### A SURVEY TO ASSESS THE AWARENESS AND KNOWLEDGE OF CLINICAL STUDENTS(III & IV BDS), INTERNS, AND POSTGRADUATES ON DENTAL CONSIDERATIONS OF PATIENTS WITH SOME SYSTEMIC DISEASES IN ANDHRA PRADESH - AN ONLINE SURVEY

Sravanthi T.L.G<sup>1</sup>, Rao B.L.<sup>2</sup>, Nibha Kumari Singh<sup>3</sup>, Satyanarayana T.S.V<sup>4</sup>, Krishna Teja G.<sup>5</sup> and Aditya K.<sup>6</sup>

1. Postgraduate Student, Department of Prosthodontics, Lenora Institute of Dental Sciences, NTR University, Andhra Pradesh.
2. Professor & Head, Department of Prosthodontics, Lenora Institute of Dental Sciences, NTR University, Andhra Pradesh.
3. Reader, Department of Prosthodontics, Lenora institute of Dental Sciences, NTR University, Andhra Pradesh.
4. Reader, Department of Prosthodontics, Lenora institute of Dental Sciences, NTR University, Andhra Pradesh.
5. Postgraduate Student, Department of Prosthodontics, Lenora Institute of Dental Sciences, NTR University, Andhra Pradesh.
6. Postgraduate Student, Department of Prosthodontics, Lenora Institute of Dental Sciences, NTR University, Andhra Pradesh.

#### Manuscript Info

##### Manuscript History

Received: 10 March 2021  
Final Accepted: 14 April 2021  
Published: May 2021

#### Abstract

**Aim of the study:** To assess the awareness and knowledge of clinical students (III& IVBDS), interns, and postgraduates on dental considerations of patients with some systemic diseases in Andhra Pradesh.

**Materials and Methods:** A questionnaire was made and uploaded in the form of google sheets. The survey was performed electronically for about three months, from February 1st, 2020, to May 1st, 2020. Finally, the results were obtained in the form of pie charts and were represented systematically by using Docs Editors software in google forms.

**Results:** A total of 500 members participated in the survey, out of which 63 percent of the people responded, and 37 percent of the people did not respond.

**Conclusion:** There is a need to inculcate information and knowledge about systemic diseases and their preventions and precautions to be taken while performing a dental treatment, particularly in clinical students.

Copy Right, IJAR, 2021.. All rights reserved.

#### Introduction:-

In general, the dental patients and, in particular, the medically compromised patients, the knowledge of pathologies related to or possibly induced by prosthetic microbial plaque<sup>1</sup> is essential for maintaining oral health and preventing possible complications. Prosthodontic procedures should not be planned until the systemic condition of the patient is evaluated. Treatment planning considers all the diagnostic findings, systemic and local, which influence the mouth's surgical preparations, impression making, maxilla-mandibular relation records, occlusion, form, and material in the teeth. Many systemic diseases have a local manifestation with no apparent systemic symptoms, and others have both local and systemic reactions. Evaluating the patient for proper diagnosis prognosis and appropriate treatment plan is the first step in a denture treatment. A significant number of complete denture patients are beset with considerable

Corresponding Author:- Sravanthi T.L.G

Address:- Postgraduate Student, Department of Prosthodontics, Lenora Institute of Dental Sciences, NTR University, Andhra Pradesh.



ISSN: 0975-833X

Available online at <http://www.journalcra.com>

International Journal of Current Research  
Vol. 13, Issue, 02, pp.16227-16232, February, 2021

DOI: <https://doi.org/10.24941/ijcr.40847.02.2021>

INTERNATIONAL JOURNAL  
OF CURRENT RESEARCH

## REVIEW ARTICLE

### DIE MATERIALS AND DIE SYSTEMS – REVIEW

<sup>1,\*</sup>Sravanthi, T.L.G., <sup>2</sup>Rao B.L., <sup>3</sup>Satyanarayana, T., <sup>4</sup>Krishna Teja, G., <sup>5</sup>Monika, P.K., <sup>6</sup>Aditya, K.

<sup>1</sup>Postgraduate Student, Department of Prosthodontics, Lenora Institute of Dental Sciences, NTR University, Andhra Pradesh; <sup>2</sup>Professor & Head, Department of Prosthodontics, Lenora Institute of Dental Sciences, NTR University, Andhra Pradesh; <sup>3</sup>Reader, Department of Prosthodontics, Lenora Institute of Dental Sciences, NTR University, Andhra Pradesh; <sup>4</sup>Postgraduate student, Department of Prosthodontics, Lenora Institute of Dental Sciences, NTR University, Andhra Pradesh; <sup>5</sup>Postgraduate student, Department of Prosthodontics, Lenora Institute of Dental Sciences, NTR University, Andhra Pradesh; <sup>6</sup>Postgraduate student, Department of Prosthodontics, Lenora Institute of Dental Sciences, NTR University, Andhra Pradesh

#### ARTICLE INFO

##### Article History:

Received 10<sup>th</sup> November, 2020  
Received in revised form  
19<sup>th</sup> December, 2020  
Accepted 20<sup>th</sup> January, 2021  
Published online 26<sup>th</sup> February, 2021

##### Key Words:

Die System, Pindex System,  
Accutrac system, Die Pins.

#### ABSTRACT

**Aim:** This study was aimed to review the role of die systems in prosthodontics and how it is relevant to fixed prosthodontics. **Methodology:** A systematic literature search was performed electronically and also hand-searched with terms. The search was carried out through Medline via Pubmed, Wiley online library, Ebscohost, Science Direct, and the Google Scholar for articles published from 2000 to 2019. A total of 172 articles were found. A total of 111 articles were found relevant to the topic. Articles selected were critically appraised to evaluate their quality. **Results:** Different articles described various die systems its advantages and disadvantages. The literature search revealed 33 articles in PMC. 56 articles were found on Wiley online library, 32 articles in google search, 22 articles in Ebscohost. Additional 29 articles were identified by hand search. **Conclusion:** An accurate working cast with removable dies is essential to make a well-fitting restoration. Detailed reproduction of die materials for fixed prosthesis affect the accuracy of operating casts and was expounded to the compatibility between the die and impression materials.

Copyright © 2021, Sravanthi et al. This is an open access article distributed under the Creative Commons Attribution License, which permits unrestricted use, distribution, and reproduction in any medium, provided the original work is properly cited.

Citation: Sravanthi, T.L.G., Rao B.L., Satyanarayana, T., Krishna Teja, G., Monika, P.K., Aditya, K. 2021. "Die materials and Die systems – Review", *International Journal of Current Research*, 13, (02), 16227-16232.

## INTRODUCTION

As direct fabrication of patterns for extra coronal restorations in the mouth is inconvenient, difficult, time-consuming, and virtually impossible, practically all wax patterns are made in the laboratory with the indirect technique. This technique requires accurate reproduction of the prepared tooth, the surrounding soft tissues, and the adjacent and opposing teeth. A cast-and-die system captures the necessary information so that it can be transferred to the laboratory.<sup>1</sup>

## MATERIALS AND METHODOLOGY

PubMed/Medline, Wiley online, and Google search were the electronic resources used to review the biomedical literature, using the following keywords. Die system, Pindex system, Accutrac system, Die pins. In total, we found 172 relevant articles. The literature search revealed 33 articles in PMC; 56 articles were found on Wiley online library, 32 articles in google search, 22 articles in Ebscohost. Additional 29 articles were identified by hand search.

\*Corresponding author: Sravanthi, T.L.G.,  
Postgraduate student, Department of prosthodontics, Lenora institute of dental sciences, NTR University, Andhra Pradesh.

As a criterion for selecting these studies, we included only the articles published in English; after reading the abstracts, we selected 111 articles that fit these criteria, with the publication dates ranging from 2000 to 2019.

#### Definitions

**DIE:** The positive reproduction of the form of a prepared tooth in any suitable substance.<sup>2</sup>

**WORKING CAST:** This is the replica of the prepared teeth, ridge areas & other parts of dental arch.<sup>1</sup> (figure-1).

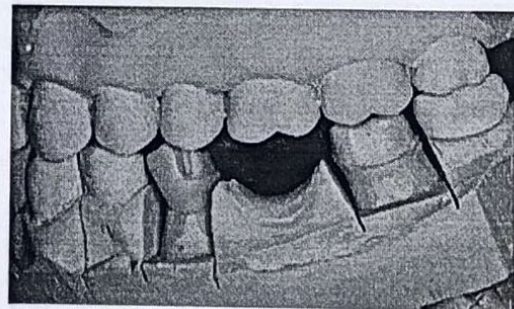


Figure 1.

## **“EFFICACY OF OZONATED OIL AND SODIUM PERBORATE AGAINST CANDIDA ALBICANS AS DENTURE CLEANSERS AND ITS EFFECT ON COLOR STABILITY IN PMMA RESINS”- A PILOT STUDY**

**Sravanthi T L G1, Rao B L2, Nibha K Singh3, Teja G4, Aditya K5**

1. Postgraduate student, Department of Prosthodontics, Lenora institute of dental sciences, NTR University, Andhra Pradesh.
2. Professor & Head, Department of Prosthodontics, Lenora institute of dental sciences, NTR University, Andhra Pradesh.
3. Reader, Department of Prosthodontics, Lenora institute of dental sciences, NTR University, Andhra Pradesh.
4. Postgraduate student, Department of Prosthodontics, Lenora institute of dental sciences, NTR University, Andhra Pradesh.
5. Postgraduate student, Department of Prosthodontics, Lenora institute of dental sciences, NTR University, Andhra Pradesh.
- 6.

*Abstract: There are many commercially available denture cleansers in the market, but yet there is a need to find natural denture cleanser. One such example is stated in this article.*

### **AIM OF THE STUDY:**

*Evaluation of efficacy of ozonated oil and sodium perborate against candida Albicans as denture cleansers and its effect on color stability in PMMA resins.*

### **OBJECTIVES OF THE STUDY:**

1. *To evaluate the efficacy of ozonated olive oil, as a denture cleanser against Candida Albicans.*
2. *To evaluate the efficacy of sodium perborate as a denture cleanser against Candida Albicans.*
3. *To evaluate the color stability of denture base after rinsing with ozonated olive oil.*
4. *To evaluate the color stability of denture base after rinsing with sodium perborate.*
5. *To compare the efficacy of ozonated oil (immersion) and sodium perborate against Candida Albicans.*
6. *To compare the color stability of denture base after rinsing in ozonated olive oil and sodium perborate.*

*Results: ozonated olive oil showed superior properties in both anticandidal efficacy and color stability as a denture cleanser on PMMA resins*

**Keywords:** *Ozonated olive oil, Sodium perborate, Distilled water, Denture cleanser*

### **Introduction:**

Polymethylmethacrylate (PMMA) was first introduced by Walter Wright in 1937 as a denture base resin and became superior overall materials by 1940. It is been used successfully for various applications in dentistry for many years.<sup>1</sup> It is the material of choice because of its ease of processing, low cost, lightweight, favorable physical and mechanical properties, water sorption, solubility, and ability to repair easily.<sup>2</sup>



 <p>ISSN NO. 2320-5407</p>	<p>Journal Homepage: - <a href="http://www.journalijar.com">www.journalijar.com</a></p> <p><b>INTERNATIONAL JOURNAL OF ADVANCED RESEARCH (IJAR)</b></p> <p>Article DOI: 10.21474/IJAR01/12829 DOI URL: <a href="http://dx.doi.org/10.21474/IJAR01/12829">http://dx.doi.org/10.21474/IJAR01/12829</a></p>	
-------------------------------------------------------------------------------------------------------------	------------------------------------------------------------------------------------------------------------------------------------------------------------------------------------------------------------------------------------------------------------------------------------------------------------------	-------------------------------------------------------------------------------------

### RESEARCH ARTICLE

#### A SURVEY TO ASSESS THE AWARENESS AND KNOWLEDGE OF CLINICAL STUDENTS(III & IV BDS), INTERNS, AND POSTGRADUATES ON DENTAL CONSIDERATIONS OF PATIENTS WITH SOME SYSTEMIC DISEASES IN ANDHRA PRADESH - AN ONLINE SURVEY

Sravanthi T.L.G<sup>1</sup>, Rao B.L<sup>2</sup>, Nibha Kumari Singh<sup>3</sup>, Satyanarayana T.S.V<sup>4</sup>, Krishna Teja G.<sup>5</sup> and Aditya K.<sup>6</sup>

1. Postgraduate Student, Department of Prosthodontics, Lenora Institute of Dental Sciences, NTR University, Andhra Pradesh.
2. Professor & Head, Department of Prosthodontics, Lenora Institute of Dental Sciences, NTR University, Andhra Pradesh.
3. Reader, Department of Prosthodontics, Lenora institute of Dental Sciences, NTR University, Andhra Pradesh.
4. Reader, Department of Prosthodontics, Lenora institute of Dental Sciences, NTR University, Andhra Pradesh.
5. Postgraduate Student, Department of Prosthodontics, Lenora Institute of Dental Sciences, NTR University, Andhra Pradesh.
6. Postgraduate Student, Department of Prosthodontics, Lenora Institute of Dental Sciences, NTR University, Andhra Pradesh.

#### Manuscript Info

##### Manuscript History

Received: 10 March 2021

Final Accepted: 14 April 2021

Published: May 2021

#### Abstract

**Aim of the study:** To assess the awareness and knowledge of clinical students (III& IVBDS), interns, and postgraduates on dental considerations of patients with some systemic diseases in Andhra Pradesh.

**Materials and Methods:** A questionnaire was made and uploaded in the form of google sheets. The survey was performed electronically for about three months, from February 1st, 2020, to May 1st, 2020. Finally, the results were obtained in the form of pie charts and were represented systematically by using Docs Editors software in google forms.

**Results:** A total of 500 members participated in the survey, out of which 63 percent of the people responded, and 37 percent of the people did not respond.

**Conclusion:** There is a need to inculcate information and knowledge about systemic diseases and their preventions and precautions to be taken while performing a dental treatment, particularly in clinical students.

Copy Right, IJAR, 2021,. All rights reserved.

#### Introduction:-

In general, the dental patients and, in particular, the medically compromised patients, the knowledge of pathologies related to or possibly induced by prosthetic microbial plaque<sup>1</sup> is essential for maintaining oral health and preventing possible complications. Prosthodontic procedures should not be planned until the systemic condition of the patient is evaluated. Treatment planning considers all the diagnostic findings, systemic and local, which influence the mouth's surgical preparations, impression making, maxilla-mandibular relation records, occlusion, form, and material in the teeth. Many systemic diseases have a local manifestation with no apparent systemic symptoms, and others have both local and systemic reactions. Evaluating the patient for proper diagnosis prognosis and appropriate treatment plan is the first step in a denture treatment. A significant number of complete denture patients are beset with considerable

Corresponding Author:- Sravanthi T.L.G

Address:- Postgraduate Student, Department of Prosthodontics, Lenora Institute of Dental Sciences, NTR University, Andhra Pradesh.

226



**EXPRESSIONS MATTER IN PROSTHODONTICS – A NARRATIVE REVIEW**

**Sravanthi T.L.G., Rao BL., Sudheer K., Monika.P.K., SaiKumar.C D and Bhargavi.B**

Department of Prosthodontics, Lenora Institute of Dental Sciences, N.T.R. University, Andhra Pradesh

**ARTICLE INFO**

**Article History:**

Received 13<sup>th</sup> November, 2020

Received in revised form 11<sup>th</sup>

December, 2020

Accepted 8<sup>th</sup> January, 2021

Published online 28<sup>th</sup> February, 2021

**ABSTRACT**

A study of normal facial landmarks is necessary before attempting to achieve the goal of natural and pleasing expression. The prosthodontist has more to do with the beauty of a face than any other beautician. Mouth plays an important role in facial expressions.

**Key words:**

Facial muscles, prosthodontics, expressions.

Copyright©2021 Sravanthi T.L.G et al. This is an open access article distributed under the Creative Commons Attribution License, which permits unrestricted use, distribution, and reproduction in any medium, provided the original work is properly cited.

**INTRODUCTION**

Mouth is not the initiator of mastication or the finalizer of speech but is the most versatile of the expressive features of a human beings. Mouth reflects a wide range of emotions. The lips, sometimes termed the mouth's curtains, actually become the main actors in facial expression.

**Muscles of facial expression:** These muscles generally don't insert into the bone. They are subcutaneous in position and produces wrinkles or fold in the skin when they contract. They are responsible for expression of different emotions of an individual. These are also called as mimetic muscles. Their movements are controlled by the muscular activity affecting the mouth's corners. The five types of movements which occur in the lip area are (1) elevation, (2) depression, (3) retraction, (4) compression, and (5) protrusion. Each is the result of the contraction and relaxation of groups of muscles.

Consequently, functional consideration of such actions should be in terms of the groups of muscles producing the action rather than in terms of individual muscles. Elevation of the lips is produced by the zygomaticus, quadratus labii superioris, 2nd caninus muscles. The lips are drawn downward by the triangularis, quadratus labii inferioris, and platysma muscles. Retraction of the lips is produced by the zygomaticus, risorius, platysma, triangularis, and buccinator. The chief compressors of the lips are the orbicularis oris, incisivi labii superioris and inferioris, mentalis, and orbicularis oris. Now, changing these group of actions will be converted into facial expressions. The lips are stretched and drawn against the teeth and tend to part and open the mouth.

**\*Corresponding author: Sravanthi T.L.G**

Department of Prosthodontics, Lenora Institute of Dental Sciences, N.T.R. University, Andhra Pradesh

The degree of the opening varies with the individual or the depth of emotion expressed. True laughter occurs when the orbicularis oris is completely and involuntarily inhibited. As such there is no literature evidence is available on the facial expressions and prostheses.

Hence, the aim of this narrative review is to highlight the different facial musculature and their role in the success of prosthodontic treatments.

**DISCUSSION**

The prosthodontic significance of a smile is the recognition that if one part of the intricate complex which produces smiling is out of position, this affects all of the other components which make up the smile. With the elevation of the maxillary lips and the retraction of the corners of the mouth, the lips are drawn against the teeth, and the placing of these teeth becomes extremely important in forming the backdrop for the smile. If the teeth are placed too far labially, the orbicularis oris is stretched, and the modioli are positioned too far anteriorly so that they are prevented from moving in the positions they were accustomed to when natural teeth were present. This stretching effect of the lips against the teeth also tends to exert a dislodging force on the maxillary denture.

Sometimes, cheek plumpers are placed in maxillary dentures near the reflective borders in an effort to raise the corners of the mouth.

An increase or decrease in the vertical dimension of occlusion can also cause strained maxillomandibular relationships, which result in damaging effects on residual ridges and distortion of facial structures.



**Awareness of Prosthodontic Treatment in the General Population of the East-Godavari District**

<sup>1</sup>Dr. G.V.R.S.R. Krishna Teja, <sup>2</sup>Dr. B.L. Rao, <sup>3</sup>Dr. T.S.V. Satyanarayana, <sup>4</sup>Dr. T.L.G. Sravanthi, <sup>5</sup>Dr. K. Aditya, <sup>6</sup>Dr. P.K. Monika

<sup>1,4,5,6</sup>Postgraduate student, Department of Prosthodontics, Lenora Institute of Dental Sciences, NTR University, Andhra Pradesh.

<sup>2</sup>Professor & Head, Department of Prosthodontics, Lenora Institute of Dental Sciences, NTR University, Andhra Pradesh.

<sup>3</sup>Reader, Department of Prosthodontics, Lenora Institute of Dental Sciences, NTR University, Andhra Pradesh.

**Corresponding Author:** Dr. G.V.R.S.R. Krishna Teja, Postgraduate student, Department of Prosthodontics, Lenora Institute of Dental Sciences, NTR University, Andhra Pradesh.

**Citation of this Article:** Dr. G.V.R.S.R. Krishna Teja, Dr. B.L. Rao, Dr. T.S.V. Satyanarayana, Dr. T.L.G. Sravanthi, Dr. K. Aditya, Dr. P.K. Monika, "Awareness of Prosthodontic Treatment in the General Population of the East-Godavari District", IJDSIR- May - 2021, Vol. - 4, Issue - 3, P. No. 532 - 542.

**Copyright:** © 2021, Dr. G.V.R.S.R. Krishna Teja, et al. This is an open access journal and article distributed under the terms of the creative commons attribution noncommercial License. Which allows others to remix, tweak, and build upon the work non commercially, as long as appropriate credit is given and the new creations are licensed under the identical terms.

**Type of Publication:** Original Research Article

**Conflicts of Interest:** Nil

**Abstract**

**Aim:** To assess the awareness of prosthodontic treatment in the general population of East-Godavari district.

**Objective:** To assess the awareness of prosthodontic treatment in the general population of the East-Godavari district.

**Material and methodology:** A cross-sectional survey was carried out among general population (public) of the East-Godavari district with a sample size of 300. A self-designed questionnaire form was made to fill to assess the awareness on Prosthodontic treatments. Data was analyzed using the software SPSS version 23.0. Descriptive statistics were generated. Chi square test was applied for age and gender response comparison. A p-value of <0.05 was kept as statistically significant.

**Results:** Only 46% of the subjects were aware of dental implant treatment. 34% were aware of replacement of lost part by a prosthodontist; and 30% were aware that cleft palate treatment could be performed by a prosthodontist. When results were compared between different age groups, subjects between the age group of 25-35 years showed more awareness among prosthodontic treatments compared to other age groups. There is significantly less awareness of prosthodontic treatments in the general population of the East-Godavari district.

**Conclusion:** Even though with the increase in the number of dental clinics and dentists, there is still a lack of complete awareness about the various kinds of treatments a prosthodontist can perform.

**Corresponding Author:** Dr. G.V.R.S.R. Krishna Teja, *ijdsir*, Volume - 4 Issue - 3, Page No. 532 - 542

## Unconventional dentures – A literature review

Shaik Riyaz Basha<sup>1\*</sup>, M. Sujesh<sup>2</sup>, Sadaf Alvi<sup>3</sup>, Nirban Mitra<sup>4</sup>

<sup>1</sup>Associate Professor, Dept. of Prosthodontics, Malla Reddy Institute of Dental Sciences, Hyderabad, Telangana, <sup>2</sup>Professor, Dept. of Prosthodontics, Mamta Dental College, Khammam, Telangana, <sup>3,4</sup>Senior Lecturer, <sup>3</sup>Dept. of Oral Pathology, <sup>4</sup>Dept. of Prosthodontics, <sup>3,4</sup>Malla Reddy Institute of Dental Sciences, Hyderabad, Telangana, India

**\*Corresponding Author:**

Email: riyazbasha007@gmail.com

### Abstract

Routine complications faced by the dentist include atrophic ridge, microstomia, flabby tissue, xerostomia, bony exostosis, labially inclined premaxilla, esthetic demand, bruxism, systemic disorders, patient's demand for duplicating dentures, etc. Management of these difficulties can be done by proper incorporating of suitable materials and advanced techniques. This article describes the unconventional approaches to various modalities so as to provide ultimate satisfaction for the patient.

**Keywords:** Unconventional dentures, Liquid supported dentures, Xerostomia.

### Introduction

Complete loss of teeth leads to significant psychological trauma, loss of masticatory efficiency, loss of the supporting alveolar bone, reduced vertical dimension, lack of support for the facial musculature and altered jaw functions. Advancing age can lead to exaggerated tissue folds and tissue atrophy, loss of tissue support, increase in the number of creases and folds on the face and loss of tonicity of the muscles and skin.<sup>1</sup> These changes lead to reduced vertical dimension with a collapsed lower third of the face and affects the overall esthetics of the patient. The external appearance of a complete denture patient is characterised by the presence of deep nasolabial folds, lack of lip support as indicated by the loss of vermilion border and dropping of the corner of the lips. Denture esthetics is defined as the effect produced by a dental prosthesis that affects the beauty and attractiveness of the patient.<sup>2</sup> Denture esthetics begins at the first consultation visit of the patient when the esthetic expectations of the patient from the denture need to be assessed and estimated thoroughly. The goal of complete denture prosthodontics is to ensure that the facial musculature is restored of the support and tonicity that has set in due to the complete loss of teeth. This could be achieved either by increasing the thickness of the dentures or by providing the ideal vertical dimension so as to restore the physiologic muscle length and eliminate the pseudoprognathic appearance.<sup>3</sup> The role of a Prosthodontist is to restore the lost function, provide better esthetics and improve the tonicity of the orofacial muscles. Restoring esthetics with dentures by replacing the loss of all these various structures and restoring function can be carried out either with.

1. Conventional dentures
2. Unconventional dentures

Unconventional dentures can be used to provide either lost support of the orofacial muscles or to improve muscle tonicity or for better orofacial functions etc.

**Restoration of Esthetics:** Unconventional dentures have been used for the restoration of esthetics of the buccal musculature by the use of cheek plumpers. Artificial denture cheek plumpers were proposed by Larsen<sup>4</sup> et al in 1976 for the management of patients with specific esthetic concern. He described a technique for the restoration of the lost tonicity of the buccal musculature. The same technique of cheek plumpers was successfully used by Sunil Kumar et al.<sup>5</sup> They described, in their case report, the management of a patient with severe loss of buccal musculature, tonicity of the skin and lack of support from the previous denture. Major concerns of the patient were poor esthetics, unsupported oral musculature and slumped cheeks which were not addressed by the previous dentures. Thus, better esthetic was achieved in the case reported by them by modifying the conventional dentures and including cheek plumpers for restoration of esthetics and function. Thus, denture esthetics has gone beyond the mere selection of teeth size, shape and shade.<sup>6</sup> Cheek plumpers help to achieve better esthetics by providing support to the cheek musculature which has had contour changes as a result of loss of vertical dimension. Loss of elasticity of connective tissue results in the excessive loss of support for the buccal musculature.

### Management of Patients with Xerostomia:

Unconventional dentures have been effectively used in the management of patient suffering from xerostomia. These patients complain of a dry mouth, difficulty in normal oral functions including eating, speaking and swallowing.<sup>7</sup> Extreme discomfort in wearing dentures is a common complaint.<sup>8</sup> Xerostomia can occur due to many possible causes such as in syndromes and diseases associated with reduced salivary flow – Sjogrens syndrome and diseases of the salivary gland; stress; post irradiation sequelae and poor general health of the patient. Management of these patients is routinely done with medication or with gustatory stimulation of the salivary glands by mastication of



## Armamentarium for Reduction of Transmission of COVID-19 Infection in Dental Operatory

Parvathi PSHL<sup>1</sup>, Rao BL<sup>2</sup>, Sruthi YSS<sup>3</sup>, Vinay Kumar P<sup>4</sup>, Chakradhar V<sup>5</sup>.

<sup>1</sup> Postgraduate Student, Department of Prosthodontics, Lenora Institute of Dental Sciences.

<sup>2</sup> Professor & Hod, Department of Prosthodontics, Lenora Institute of Dental Sciences.

<sup>3</sup> Postgraduate Student, Department of Prosthodontics, Lenora Institute of Dental Sciences.

<sup>4</sup> Postgraduate Student, Department of Prosthodontics, Lenora Institute of Dental Sciences.

<sup>5</sup> Postgraduate Student, Department of Prosthodontics, Lenora Institute Of Dental Sciences

### ABSTRACT

The Pandemic of Novel Corona Virus Disease which emerged in December 2019 in WUHAN city is having an overshadowing impact on everyone's life. Its mode of spread is primarily through droplets of saliva or discharge from the nose when an infected person coughs or sneezes. Research labs are joining forces to find a therapy and a preventive vaccine. Preventive and extraordinary safety measures are crucial to reducing the spread of SARS-CoV-2 (severe acute respiratory syndrome coronavirus 2) among health care professionals (HCP). HCP performing or assisting aerosol-generating procedures are classified as 'very high exposure risk' workers. Dentists are one among higher risk HCP as they deal with oral cavity problems. This is because most of the procedures are involved with aerosol production in dentistry and saliva is the best medium for the dwelling of Covid-19. So, along with the use of standard preventive measures in reducing the transmission of COVID -19 it is essential for dental offices to change the operating modes. As we all know 'Prevention is better than cure' In this article, we reviewed auxiliary armamentariums required for prevention of transmission of Covid-19 infection to be used by dental health care professionals while providing urgent dental care to the patients. Currently, in the absence of a rapid diagnostic device with high sensitivity/ specificity and without an effective therapy or vaccine against SARS-CoV2, it is strongly recommended to treat each patient as a COVID-19 positive. So that Appropriate safety measures will protect both dental professionals and patients in transmitting this pandemic disease.

### Key words:

COVID-19 transmission, infection control, armamentarium, sanitizer dispensers, masks.

### Article History:

Received On: 08.04.2020

Revised On: 20.06.2020

Accepted On: 29.06.2020


### \*Corresponding Author

Name: Parvathi PSHL

Email: harika.knp4@gmail.com

DOI: <https://doi.org/10.37022/wjcmpr.vi.146>

This article is licensed under a Creative Commons Attribution-Non Commercial 4.0 International License. Copyright © 2020 Author(s) retain the copyright of this article.



### INTRODUCTION

Corona virus disease 2019 (COVID-19) clinically manifest as the severe acute respiratory syndrome coronavirus 2 (SARS-COV-2) [1]. dental professionals are at greater risk as their treatment deals with oral cavity problems and saliva is the best medium for dwelling of COVID-19 viruses. Dental patients and professionals are at high risk to expose covid -19 infections, because of Dental procedures using drills or ultrasonic devices cause aerosol release, thus, most often exposure to saliva (droplets, aerosols), blood, working position with patients, face to face communication can spread disease and also contaminates the dental clinical environment [1 -6].

The routes of transmission of COVID-19 in dental practice are:

1. airborne spread
2. Contact spread
3. contaminated surface spread

Although many routine precautionary measures to reduce the transmission of COVID-19 infection; there are some other armamentarium required for prevention of transmission of COVID-19 infection. In this article we discussed various

auxiliary armamentarium required for prevention of transmission.

### 1. AUTOMATIC HAND SANITIZER DISPENSERS [7]

Generally, manually operated hand sanitizers were dispensed in dental clinical premises. [Figureure 01] In this type, the risk of contaminated surfaces can be a potential source of corona virus transmission. Therefore, electrically operated with sensor attached automatic hand sanitizer dispensers is more advantageous.



Figure 01

<https://doi.org/10.46344/JBINO.2021.v10i2b.07>

## PROSTHODONTIC MANAGEMENT OF MID- FACIAL DEFECT – A CASE REPORT

Sruthi YSS<sup>1</sup>, Rao BL<sup>2</sup>, Satyanarayana S V Tammlneedi<sup>3</sup>, Pallavi C<sup>4</sup>

1. Postgraduate student, Department of prosthodontics, Lenora institute of dental sciences
2. Professor & Head, Department of prosthodontics, Lenora institute of dental sciences
3. Reader, Department of prosthodontics, Lenora institute of dental sciences
4. Senior Lecturer, Department of Prosthodontics, Sree Sai dental college & research institute.

### ABSTRACT

Any maxillofacial deformity lowers the person's quality of life by affecting them in all grounds of life physically, psychologically, and socially. Rehabilitation of patients with these deformities is of great challenge to the Prosthodontist because it is the esthetics that has to be achieved, giving equal importance in these cases and the function. This case report illustrates maxillofacial prosthetic rehabilitation of significant midfacial defect, including orbit and its contents, zygoma, soft tissues, including half of the nose, cheeks of the right side orofacial communication, which resulted from resection of mucoepidermoid carcinoma. Various retentive aids were utilized, such as ear lobe of spectacles, magnets, adhesives, and acrylic to enhance the retention and provide the near to natural appearance and functioning.

**KEYWORDS:** Facial defect, Facial prosthesis, Silicone, Mucoepidermoid carcinoma, Prosthodontist, Magnets



**Journal of Prosthodontics Dentistry**  
**An Official Publication of Bureau for Health & Education Status Upliftment**  
 (Constitutionally Entitled As Health-Education, Bureau)

## Craft of Choosing A Prime Luting Agent

Parvathi PSHL<sup>1</sup>, Rao BL<sup>2</sup>, Satyanarayana TSV<sup>3</sup>, Sruthi YSS<sup>4</sup>, Padmini D<sup>5</sup>, Chakradhar V<sup>6</sup>

1. Postgraduate Student, Department of Prosthodontics, Lenora Institute of Dental Sciences
2. Professor & HOD, Department of Prosthodontics, Lenora Institute of Dental Sciences
3. Reader, Department of Prosthodontics, Lenora Institute of Dental Sciences
4. Senior lecturer, Department of Prosthodontics, Lenora Institute of Dental Sciences
5. Postgraduate Student, Department of Prosthodontics, Lenora Institute of Dental Sciences
6. Postgraduate Student, Department of Prosthodontics, Lenora Institute of Dental Sciences

**Email Id: [serviceheb@gmail.com](mailto:serviceheb@gmail.com)**

**Abstract:**

The longevity of the fixed partial denture depends on the type of luting cement used. Whereas the selection of the luting agent is dependent on the specific clinical situation, the type of restoration utilized, and the physical, biologic, and handling properties of the luting agent. The primary purpose of the luting procedure is to achieve a durable bond and to have an excellent marginal adaptation of the luting material to the restoration and tooth. There are varieties of luting agents available, from conventional water-based to newest adhesive resin cements. However, no single luting agent is capable of meeting all the stringent requirements. The introduction of adhesive resin systems has completely changed the face of fixed prosthodontic practice leading to increased use of bonded all-ceramic crowns and resin-retained fixed partial dentures. The purpose of the article is to provide a discussion that includes a clinical perspective and type of restoration-based selection of luting agents.

**Keywords:** Dental luting cements, GIC, Luting cements, Provisional and Definitive luting cements, Resin cements, Resin-modified luting cements.

Access this Article Online

Website: <http://heb-nic.in/jopd>

Received on 07/04/2021

Accepted on 22/04/2021 © HEB All rights reserved

Quick Response Code:





**Knowledge, Awareness & Attitude of Dental Personnel Towards Fixed Dental Prosthetic Procedures Amid Covid19 Across India.**

<sup>1</sup>Dr. V. Chakradhar, Postgraduate student, Department of Prosthodontics, Lenora Institute of Dental Sciences.

<sup>2</sup>Dr. B. Lakshmana Rao, Professor & Head, Department of Prosthodontics, Lenora Institute of Dental Sciences.

<sup>3</sup>Dr. Nibha kumari singh, Reader, Department of Prosthodontics, Lenora Institute of Dental Sciences.

<sup>4</sup>Dr. S. Sirisha, Senior Lecturer, Department of Prosthodontics, Lenora Institute of Dental Sciences.

<sup>5</sup>Dr. Y. S. S. Sruthi, Senior Lecturer, Department of Prosthodontics, Lenora Institute of Dental Sciences.

<sup>6</sup>Dr. PSHL Parvathi, Postgraduate student, Department of Prosthodontics, Lenora Institute of Dental Sciences.

**Corresponding Author:** Dr. B. Lakshmana Rao, Professor & Head, Department of Prosthodontics, Lenora Institute of Dental Sciences.

**Citation of this Article:** Dr. V. Chakradhar, Dr. B. Lakshmana Rao, Dr. Nibha kumari singh, Dr. S. Sirisha, Dr. Y. S. S. Sruthi, Dr. PSHL Parvathi, "Knowledge, Awareness & Attitude of Dental Personnel Towards Fixed Dental Prosthetic Procedures Amid Covid19 Across India.", IJDSIR- February - 2021, Vol. – 4, Issue - 1, P. No. 120 – 128.

**Copyright:** © 2021, Dr. B. Lakshmana Rao, et al. This is an open access journal and article distributed under the terms of the creative commons attribution noncommercial License. Which allows others to remix, tweak, and build upon the work non commercially, as long as appropriate credit is given and the new creations are licensed under the identical terms.

**Type of Publication:** Review Article

**Conflicts of Interest:** Nil

**Abstract**

**Objective:** The aim of this study was to assess Knowledge, awareness & Attitude of dental personnel towards aerosol-generating fixed dental prosthetic procedures amid covid19 in India.

**Materials and Methods:** A total of 960 dentists participated in this cross-sectional survey. A self-administered, multiple-choice type questionnaire of 33 questions (verified by a specialist) was administered to obtain information from the subjects. Statistical analysis was done using the Chi-square test.

**Results:** The percentage of subjects who answered correctly regarding the main and primary mode of transmission was 87.5%. A majority of participants don't like to opt for aerosol producing procedures during

COVID 19. 85.4% dentists aware that the fixed prosthetic procedures don't come under emergency treatment. 71.7% dentists advised using rubber dam like isolation protocols during fixed prosthetic procedures. The percentage of dentists disinfecting impressions and stone casts increased from 65.4% to 96.7% during this pandemic.

**Conclusion:** Indian dentists were aware of COVID-19 symptoms, mode of transmission, infection control, and measures in dental clinics. The findings of the present study showed that some notable deficiencies in knowledge existed among dental professionals regarding some vital aspects of COVID-19. Therefore, there is an urgent need for improving dentists' knowledge via health education and training programs.

**Keywords:** Covid -19, SARSCoV-2

**Corresponding Author:** Dr. B. Lakshmana Rao, ijdsir, Volume – 4 Issue - 1, Page No. 120 - 128





## MASTERY ON BALANCED OCCLUSION

Sruthi YSS<sup>1</sup>, Rao BL<sup>2</sup>, Dr. Satyanarayana S V Tammineedi<sup>3</sup>, Chakradhar V<sup>4</sup> and Parvathi PSHL<sup>5</sup>

<sup>1</sup>Postgraduate Student, Department of Prosthodontics, Lenora Institute of Dental Sciences

<sup>2</sup>Professor & Head, Department of Prosthodontics, Lenora Institute of Dental Sciences

<sup>3</sup>Reader, Department of Prosthodontics, Lenora Institute of Dental Sciences

<sup>4</sup>Postgraduate Student, Department of Prosthodontics, Lenora Institute of Dental Sciences

<sup>5</sup>Postgraduate Student, Department of Prosthodontics, Lenora Institute of Dental Sciences

### ARTICLE INFO

#### Article History:

Received 4<sup>th</sup> February, 2020

Received in revised form 25<sup>th</sup>

March, 2020

Accepted 23<sup>rd</sup> April, 2020

Published online 28<sup>th</sup> May, 2020

#### Key words:

occlusion, balanced occlusion, hanau quint, compensating curves, artificial dentition

### ABSTRACT

The success of any prosthesis depends how well it is into function. The function of a prosthesis is to help in mastication, speech, esthetics without effecting the neuromuscular system. Occlusion is the main determinant of the functioning of prosthesis. Occlusion has been, and still is to some extent, a controversy issue in what is now called conventional removable and fixed prosthodontics. The range of opinion in the dental profession as to the importance of occlusion is enormous. The aim of this paper is to bring out the role of balanced occlusion in complete denture and factors influencing it.

Copyright©2020 Sruthi YSS et al. This is an open access article distributed under the Creative Commons Attribution License, which permits unrestricted use, distribution, and reproduction in any medium, provided the original work is properly cited.

### INTRODUCTION

According to GPT-9,<sup>1</sup> Occlusion is defined as the static relationships between the incising or masticating surfaces of maxillary and mandibular teeth or tooth analogues. But teeth either natural or artificial are not immobile so occlusion can never be considered a purely static relationship. The word "Articulation" refers primarily to the dynamic movements of the teeth in relation to each other. It also refers joint relationships, relationships of jaws / casts, the arrangement of teeth and enunciation of speech.<sup>1</sup> Term occlusion is derived from the Latin word, "occlusio" defined as the relationship between all the components of the masticatory system in normal function, dysfunction and parafunction. An ideal occlusion is the perfect interdigitation of the upper and lower teeth, which is a result of developmental process consisting of the three main events, jaw growth, tooth formation and eruption occlusal development can be divided into the following development periods: neo-natal period. (lasts up to 6 months after birth). primary dentition period (from around the 6<sup>th</sup> month to 6 years) mixed dentition period (around 6 years – 12 years) permanent dentition period (12 years onwards).<sup>1,2</sup> Restoring a completely edentulous condition is entirely different from restoring a partially edentulous condition as there are no teeth to guide in completely edentulous state. This difference or difficulty in treating a completely edentulous

patient is because of the differences in the natural and artificial dentition. (Table 1).

**Table 1** Differences between natural and artificial dentition:<sup>3,4,5,6</sup>

Natural dentition	Artificial dentition
Natural teeth function independently & each tooth disperses the occlusal load	Artificial teeth functions as a group & the occlusal loads are not individually managed
Malocclusion can be non-problematic for long time	Malocclusion poses immediate drastic problems
Non-vertical forces are well tolerated	Non-vertical forces damages the supporting tissues
Incising doesnot affect the posterior teeth (chritensens phenomeon)	Incising will lift the posterior part of denture
2 <sup>nd</sup> molar area is the favored area for heavy mastication & better	Heavy mastication over the 2 <sup>nd</sup> molar area can tilt or lift the denture base
Bilateral balance is not necessary and usually considered as hinderance	Bilateral balance is mandatory to stabilize the denture
Proprioceptive impulses to avoid occlusal pre-maturities. This helps patient to have habitual occlusion away from centric relation	There is no feedback and denture rests in centric relation. Any pre-maturities can shift the base.
Forces of mastication 5 to 175 pounds	Incisor area – 9pound Premolar & molar area – 22-24 pounds

#### Concepts of complete denture occlusion (balanced occlusion)

Balanced occlusion is defined as "The bilateral, simultaneous occlusal contact of the anterior and posterior teeth in excursive movements." (GPT- 9)<sup>1</sup>

\*Corresponding author: Sruthi YSS

Postgraduate Student, Department of Prosthodontics, Lenora Institute of Dental Sciences



## KEEPING IN TIME – TILT OF THE CAST : A REVIEW

## Dental Science

<b>Dr. Y. Satya Sai Sruthi</b>	Postgraduate Student, Department Of Prosthodontics, Lenora Institute Of Dental Sciences, Andhra Pradesh
<b>Dr. Lakshmana Rao Bathala*</b>	Professor & Head , Department Of Prosthodontics, Lenora Institute Of Dental Sciences, Andhra Pradesh *Corresponding Author
<b>Dr. R. Narendra Kumar</b>	Professor , Department of prosthodontics, Lenora institute of dental sciences, Andhra Pradesh
<b>Dr. Jibi Joseph</b>	Postgraduate Student, Department Of Prosthodontics, Lenora Institute Of Dental Sciences, Andhra Pradesh
<b>Dr. Nibha Kumari Singh</b>	Reader , Department Of Prosthodontics, Lenora Institute Of Dental Sciences, Andhra Pradesh.

## ABSTRACT

**PURPOSE:** This study was aimed to review the different methods for reproduction of tilt of a cast on a surveyor.

**METHODOLOGY:** An electronic literature search was conducted through Medline via Pubmed, Wiley Online library, Ebscohost, Science Direct, as well as the Google Scholar for article published between October 1973 and March 2016, using the key words, tilt of cast, surveying, path of insertion, preservation of tilt and reproduction of tilt. A total of 20 articles were found out of these 8 were not related to present search and hence were excluded from the study. Finally 12 articles were found to be relevant.

**RESULTS:** All the techniques given by the different authors are having both advantages and disadvantages.

**CONCLUSION:** The path of insertion of a removable partial denture must be determined during treatment planning and permanently recorded on the cast. Literature has suggested several methods for the reproduction of cast tilt on surveyors.

## KEYWORDS

Tilt Of The Cast, Surveying, Preservation Of Tilt, Reproduction Of Tilt, Path Of Insertion.

## MAIN TEXT

## INTRODUCTION:

Removable dental prosthesis (RDP) is still considered a treatment of choice for partially edentulous patients when fixed dental prosthesis or implant supported restorations are not possible because of technical, biologic conditions and financial concerns. Clinician should consider biologic and biomechanical elements in RDP treatment planning. Appropriate analysis of the diagnostic cast is one of the initial and fundamental steps in planning RDP.<sup>1</sup>

Surveying the diagnostic cast allows the clinician to study and design an adequate planning for RDP framework.<sup>1,2</sup> Determining the best path of insertion and removal is an essential step in RDP's planning. The path of insertion is determined with the surveyor regards to height of contours, guiding planes, interferences and esthetics for RDPs.<sup>1,2,3</sup>

The path of insertion should be exactly recorded on the study cast in order to be transferred into definitive cast or working cast. This also allows the dental technician to reposition the casts on the surveyor.<sup>1,2,3</sup>

The tilt of the cast determines at what angle the partial denture will seat over the remaining teeth. This angle is referred to as the path of placement or path of insertion. It may be impossible to achieve the optimum among all factors which affect the path of insertion as one or other may need to be compromised. It is only clinical judgment which finally dictates and may be compromised without sacrificing the quality of service. The four factors that should be considered before final path of placement are retentive undercuts, interferences, aesthetics and guiding planes. The tilt of a cast must be recorded so that it can be easily transferred from the cast holder of the surveyor and subsequently reproduce it in its original position in designing and fabrication of a removable partial denture, so the main purpose of the article is to review the different methods for preservation and reproduction of the cant of the cast in fabrication of Cast Partial Denture (CPD).<sup>1,2</sup>

## METHODOLOGY:

An electronic literature search was conducted through Medline via Pubmed, Wiley Online library, Ebscohost, Science Direct, as well as the Google Scholar for article published between October 1973 and

March 2016, using the key words, tilt of cast, surveying, path of insertion, preservation of tilt and reproduction of tilt. A total of 20 articles were found out of these 8 were not related to present search and hence were excluded from the study. The articles which are published in English language only considered. Finally 12 articles were found to be relevant. Standard textbooks were also referred. All the articles were followed for the technique mentioned and the advantages and disadvantages of the technique.

## RESULTS:

The techniques mentioned are having both the advantages and disadvantages. Some of the methods mentioned are technique sensitive and required special equipment other than the surveyor and the things that are available in the laboratory, and even difficult for the technician to follow. Few methods used the materials that are available in the laboratory but need little time to fabricate them [Table 1].

## DISCUSSION:

The Surveyor plays a cardinal role in the designing of a CPD. The GPT 9 defines a surveyor as a paralleling instrument used in the construction of a dental prosthesis to locate and delineate the contours and relative positions of abutment teeth and associated structures. As per literature a Surveyor is used in the following manner in the designing of a CPD<sup>2</sup>

1. Surveying the diagnostic cast,
2. Contouring wax patterns,
3. Surveying ceramic veneer crowns,
4. Machining cast restorations,
5. Placing intra coronal retainers and internal rest seats,
6. Surveying the master cast.

As the listing reveals tripoding is one important component of surveying. Thus although tripoding is not a component of surveying per se it does play an important role in the overall procedure of surveying as tripoding allows the reorientation of a cast on the tripoding table to a pre-determined path of insertion even after the cast has been moved from the surveying table. This enables multiple users to access the instrument which otherwise would be inaccessible till an individual user has completed the entire design process. This article focused on the variety of methods adopted to perform tripoding obtained from a literature review from [oldest year to current one],

# Smear Layer Removal Efficacy of Custom Made Water Pik Power Flosser as an Irrigant Activating Device

Bhargavi Dhamaraju<sup>1</sup>, Deepa Velagala L<sup>2</sup>, Prem Raj<sup>3</sup>

**Abstract:** *Context:* The aim of the present study is to evaluate and compare the effectiveness of different irrigant activation systems on smear layer removal in the apical third of root canal dentin. Irrigant activation systems used in this study are endoactivator, intra canal brush and modified tip of an interdental waterpik power flosser and conventional syringe irrigation. *Aims:* To evaluate and compare the effectiveness of different irrigant activation systems on smear layer removal in the apical third of root canal dentin. *Methods and Material:* 40 single rooted teeth were used in the study. They were decoronated to a standard length of 15mm and were instrumented up to protaper F2. The samples were divided into 4 groups according to the irrigant activation systems and the final irrigation was done with calsept EDTA. The analysis of the root canal dentin at the apical third was performed with scanning electron microscope. *Statistical analysis used:* The results of this study are statistically significant and pair wise comparison was done using Mann Whitney U-Test. *Results:* Endoactivator significantly removed more smear layer when compared to the other irrigant activation systems. Custom made tip was more or less comparable to endoactivator. Conventional syringe activation failed to remove the smear layer completely. *Conclusions:* Sonic irrigation through endoactivator system and custom made tip of a water pik power flosser resulted in better removal of smear layer when calsept EDTA was used as a final irrigant than the conventional syringe irrigation

**Keywords:** Endoactivator, water pik power flosser, intracanal brush, smear layer

## 1. Introduction

The root canal is shaped with hand and rotary instruments under constant irrigation to remove the inflamed and necrotic tissue, microbes and bio films and other debris from the root canal space [1]. These techniques produce an irregular granular and amorphous layer called the smear layer which covers the root canal dentin. Smear layer removal requires the use of irrigating solutions that can dissolve both organic and inorganic components to eliminate the microorganisms [2] and thus the hermetic sealing of the root canal system. In addition, the smear layer also might decrease the antimicrobial effectiveness of medicaments by inhibiting their effective penetration into the dentinal tubules. Irrigation is an essential part of root canal debridement. It creates a microbe free environment in the root canal by eliminating the smear layer and providing better penetration of the root canal irrigants into the dentinal tubules [3,4, 5]. Many studies have shown that the use of sodium hypochlorite in combination with EDTA is effective in removing the smear layer during the root canal irrigation [2]. For many days irrigation of the root canal space was carried out with a syringe that is, the conventional hand irrigation which was proved to be ineffective in eliminating the smear layer from the apical part of the canal[2]. After conventional needle irrigation inaccessible canal extensions and irregularities are likely to harbor debris and bacteria, thereby making canal debridement difficult [6]. During conventional needle irrigation, replenishment and fluid exchange do not extend much beyond the tip of the irrigating needle [3]. Vapour lock that results in the trapped air in the apical third of the root canals may also hinder the exchange of irrigants and affect their debridement efficacy [3, 7]. Hence mechanical activation of these chemical agents have been developed to improve the penetration and effectiveness of irrigation. Mechanical activation of the irrigant can be done with rotary brushes, continuous irrigation during rotary instrumentation, sonic and ultrasonic activation of the

irrigant and pressure alteration devices. Mechanical activation results in disruption of smear layer and thus helps to increase the flow and distribution of irrigating solutions within the root canal system. The purpose of the present study was to compare different mechanical irrigant agitation devices in eliminating smear layer and analyze it under the scanning electron microscope

## 2. Subjects and Methods

### Sample preparation

Forty single rooted freshly extracted human teeth were used in this study. The specimens were decoronated to obtain a standardised root length of 15mm by using a diamond disk. The working length was determined with a #10 k- file. The biomechanical preparation of the root canal was done with protaper files till F2. The root canal were flushed with 3% of 1ml NaOCl solution between the files by using a plastic syringe with a closed end needle inserted as deep as possible into the root canal without binding

Calsept EDTA was used as the final irrigant and teeth were randomly divided into 4 groups based on the irrigant agitation device used.

Group I: Plastic needle and a syringe

Group II: Intracanal brush

Group III: Endoactivator

Group IV: Modified waterpik power flosser (Custom made activator tip)

### Scanning Electron Microscopy Evaluation

After instrumentation the teeth were grooved vertically on the buccal and lingual surfaces, using water cooled diamond bur and taking care to avoid touching the root canal. Thereafter the teeth were split along their axis in a buccolingual direction using a chisel and a mallet. The specimens were mounted on metallic stubs, and subjected to gold sputtering. Then the samples were examined under

Volume 8 Issue 9, September 2019

[www.ijsr.net](http://www.ijsr.net)

Licensed Under Creative Commons Attribution CC BY

## The Distribution of the ABO and Rh (D) Blood Types in Type II Diabetes Mellitus Patients

Jay Kishore<sup>1</sup>, Tulika Shruti<sup>2</sup>, Radha Kumari<sup>3</sup>, Sudhir Kumar Prasad<sup>4</sup>, Harsha. M<sup>5</sup>

### ABSTRACT

**Introduction:** The etiopathogenesis of diabetes mellitus is multi-factorial & complex and appears to involve interactions of various immunological, genetic and environmental factors. Positive association with blood groups shows increased susceptibility and a negative association shows protection against diabetes mellitus. Present study was conducted to find out a possible association between type II diabetes mellitus (DM) and ABO & Rh blood groups.

**Material and Methods:** The study involved 313 patients who reported to Haematology Laboratory for blood investigations over a period of 5 months. On the basis of Random & Fasting Blood Sugar levels, we made Group I (Diabetic patients) & Group II (Healthy controls). ABO & Rh blood grouping done for both the groups.

**Results:** AB & B blood group showed less common association with diabetes mellitus. Diabetes mellitus (DM) were more associated with Blood group A, as compared to controls. Blood group O has same distribution among both groups. Diabetics has higher percentage than controls had Rh positive blood group (96.55% vs 94.69%), and diabetics showed less percentage of Rh negative blood group (3.44% vs 5.3%). Blood group B, AB and O were positive in higher percentage among diabetics, and it was same in blood group A.

**Conclusion:** According to Results, it has association between DM and Rh positive blood groups and between blood groups B & AB it has negative association.

**Key words:** Diabetes Mellitus, Blood group, ABO, Rh.

### INTRODUCTION

The etiopathogenesis of diabetes mellitus is multi-factorial & complex and appears to involve interactions of various immunological, genetic and environmental factors.<sup>1</sup> To discover a possible association between ABO and Rh blood groups and different diseases so many efforts have been done. Salivary gland tumors, duodenal ulcer, gastric cancer, colorectal cancer, ovarian tumors, thyroid disorders, and coronary heart disease patients have shown association with ABO blood groups.<sup>2-5</sup> Investigators assume that some other diseases might also be associated with ABO and Rh blood groups. Identifying possible susceptibility to diseases by such associations help and adopt preventive measures to decrease the prevalence of disease. Common emerging medical problem worldwide which have morbidity and mortality is diabetes mellitus. The etiopathogenesis of diabetes mellitus is multi-factorial & shows interactions of various immunological, genetic and environmental factors.<sup>1</sup> Genetic and environmental factors both influenced the diabetes mellitus.<sup>6</sup> Type-2 Diabetes Mellitus has

shown well replicated linkage to Chromosome 1q21-q23.<sup>7</sup> At 9q34.2 region ABO blood group genes are mapped.<sup>8</sup> Blood groups genetically predetermined and therefore may have an association with diabetes mellitus. Hence, positive association shows increased susceptibility and a negative association shows protection against diabetes mellitus. Present study was conducted to find out a possible association between type II diabetes mellitus (DM) and ABO & Rh blood groups.

### MATERIAL METHODS

313 Patients reporting for blood investigations over a period of 5 months were included in the study. On the basis of findings of Random Blood Sugar (RBS) levels and Fasting Blood Sugar (FBS) levels two groups were made. Diabetic patients is Group I; RBS > or = 200 mg/dl & FBS > or = 126 mg/dl & Healthy controls is Group II. ABO & Rh blood grouping is checked for both the groups. The blood samples were collected and labeled for determination of blood groups. Slide agglutination method done for ABO and Rh (D) blood grouping. Standard technique and manufacturer's directions were followed. Data was recorded on a proforma and saved for record. Analysis of the findings were done. Statistical analysis was done. Contingency Coefficient (CC) analysis was done to find out any association between DM and ABO-Rh blood groups.

### RESULTS


Among 313 patients reporting to the laboratory, 87 were diabetics (group I) and 226 were healthy individuals (group II). ABO and Rh blood group distribution among diabetic patients and healthy individuals were recorded. Most prevalent group was blood group O in the whole population (36.42%), diabetics (43.67%) and controls (33.62%),

<sup>1</sup>Dentist, Bihar Government, Primary Health Centre, Sahdei Buzurg, Vaishali, Bihar, <sup>2</sup>Senior Lecturer, Vananchal Dental College and Hospital, Garhwa, <sup>3</sup>BDS, Private practitioner, 8L-30, Bahadurpur Housing Colony, P. O - B H Colony, Dist.- Patna, Bihar, <sup>4</sup>Private Practitioner, Mahamada, P.s- Bhagwanpur, Dist- Siwan, Bihar, <sup>5</sup>Senior Lecturer, Department Of Oral Pathology, Lenora Institute of Dental Sciences, Rajahmundry, AP, India

**Corresponding author:** Dr. Tulika Shruti, Flat No- 304 B, Loknath Apartment, Don Bosco School Road HESAG Hatia Ranchi-834003, India

**How to cite this article:** Jay Kishore, Tulika Shruti, Radha Kumari, Sudhir Kumar Prasad, Harsha M. The distribution of the ABO and Rh (D) blood types in type II diabetes mellitus patients. International Journal of Contemporary Medical Research 2020;7(1):A4-A6.

**DOI:** <http://dx.doi.org/10.21276/ijcmr.2020.7.1.45>



## RESEARCH ARTICLE

# Comparative Evaluation of BMI, Dental Age, Salivary Alkaline Phosphatase Levels, and Oral Health Status in Children with $\beta$ Thalassemia Major

Sandipamu T Rani<sup>1</sup>, Eddula R Reddy<sup>2</sup>, Merum Kiranmai<sup>3</sup>, Srujana P Mudusu<sup>4</sup>, Saraswathi Srikanth<sup>5</sup>, Suman Jain<sup>6</sup>

### ABSTRACT

**Purpose:** Thalassemia poses clear systemic and oral health problems. Clinicians must be aware of various dental treatment needs in these patients. This study was undertaken to assess body mass index (BMI), dental age, salivary alkaline phosphatase levels, malocclusion, and treatment needs in children with  $\beta$  thalassemia major.

**Materials and methods:** A total of 100 children within the age group of 2–15 years (50 thalassemic and 50 healthy controls) were included. Dental age, oral health status, malocclusion, and intervention urgency index was recorded. Unstimulated whole saliva samples were collected to assess the salivary alkaline phosphatase levels. The recorded data were statistically analyzed.

**Results:** A significantly greater number of thalassemia children were found to be in the underweight category. A significantly high OHI-S scores and low gingival index scores were observed in thalassemia children. Salivary alkaline phosphatase levels were significantly low in thalassemia children compared to the control group. Intervention urgency index scores were significantly high in thalassemia group of children.

**Conclusion:** Thalassemia children had low BMI, gingival index scores, salivary alkaline phosphatase levels and higher prevalence of malocclusion, and high OHI-S index scores compared to the healthy control group. Intervention urgency index scores revealed greater dental treatment needs in children with thalassemia.

**Keywords:**  $\beta$  thalassemia major, Body mass index, Intervention urgency index, Oral health status, Salivary alkaline phosphatase.

*International Journal of Clinical Pediatric Dentistry* (2019); 10.5005/jp-journals-10005-1641

### INTRODUCTION

Thalassemia is a genetic hemoglobin disorder that is prevalent worldwide, with the highest frequencies observed in South East Asia and Africa.<sup>1</sup> The mean prevalence of thalassemia in India is 3.3%.<sup>2,3</sup> Thalassemia is broadly classified into two types based on the deficient quantitative synthesis of either  $\alpha$  or  $\beta$  chains of hemoglobin.  $\beta$  thalassemia is inherited as an autosomal recessive trait owing to mutations in the HBB gene located on chromosome 11. The severity of the disease depends on the nature and presence of mutations in one or both alleles.<sup>4</sup> The carrier rate of  $\beta$  thalassemia gene varies from 1% to 3% in southern India to 3–15% in Northern India.<sup>3,5</sup>  $\beta$  thalassemia exhibits a wide range of clinical spectrum ranging from severe forms ( $\beta$  thalassemia major), milder forms ( $\beta$  thalassemia intermedia), and till clinically asymptomatic ones ( $\beta$  thalassemia minor).<sup>6</sup>

Signs and symptoms of  $\beta$  thalassemia major appear within 2 years of life. Affected infants present with severe anemia, jaundice, extreme pallor, decrease physical activity, poor feeding, irritability, and increased somnolence. Diarrhea, recurrent fever, spontaneous fractures, bleeding, susceptibility to various infections, hepatosplenomegaly, and growth retardation are some of the commonly presenting symptoms.<sup>4</sup> These thalassemia children are susceptible to various infections because of repeated blood transfusions and become transfusion-dependent throughout life to replenish their diminished red blood cell supply. They are mostly at risk of experiencing oral and facial problems owing to bone marrow hyperplasia.<sup>7</sup> These orofacial abnormalities include wide spacing of teeth, forward drift, and protrusion of maxillary incisors, abnormal anterior open bite, protrusion of maxilla, abnormalities in occlusion, and saddle nose deformity and delayed pneumatization of the maxillary antrum.<sup>8</sup> Several secondary effects include dental caries, pale-colored gums, burning sensation of tongue, painful

<sup>1–5</sup>Department of Pedodontics and Preventive Dentistry, Kamineni Institute of Dental Sciences, Nalgonda, Telangana, India

<sup>6</sup>Thalassemia and Sickle Cell Society, Hyderabad, Telangana, India

**Corresponding Author:** Sandipamu T Rani, Department of Pedodontics and Preventive Dentistry, Kamineni Institute of Dental Sciences, Nalgonda, Telangana, India, Phone: +91 8919134284, e-mail: drstranipedo@gmail.com

**How to cite this article:** Rani ST, Reddy ER, et al. Comparative Evaluation of BMI, Dental Age, Salivary Alkaline Phosphatase Levels, and Oral Health Status in Children with  $\beta$  Thalassemia Major. *Int J Clin Pediatr Dent* 2019;12(4):303–306.

**Source of support:** Nil

**Conflict of interest:** None

swelling of salivary glands and dry mouth, and reduced IgA levels, resulting in reduced salivary protection.<sup>9</sup>

Sialometry and sialochemistry can be used to diagnose systemic illnesses, monitor general health, and is an indicator for diseases' risk in relation to oral and systemic health.<sup>10</sup> Alkaline phosphatase (ALP) is a calcium-phosphorous-binding protein and phosphorhydrolytic enzyme. ALP is important in tooth mineralization.

Hence, the present study was undertaken to evaluate the BMI, dental age, oral health status, and salivary alkaline phosphatase levels in children with  $\beta$  thalassemia major.

### MATERIALS AND METHODS

#### Sample Selection

This study was carried out at the Department of Pedodontics and Preventive dentistry, Kamineni Institute of Dental Sciences,

© The Author(s). 2019 Open Access This article is distributed under the terms of the Creative Commons Attribution 4.0 International License (<https://creativecommons.org/licenses/by-nc/4.0/>), which permits unrestricted use, distribution, and non-commercial reproduction in any medium, provided you give appropriate credit to the original author(s) and the source, provide a link to the Creative Commons license, and indicate if changes were made. The Creative Commons Public Domain Dedication waiver (<http://creativecommons.org/publicdomain/zero/1.0/>) applies to the data made available in this article, unless otherwise stated.

## Original Article

# Evaluation of Styloid Process and Its Anatomical Variations: A Digital Panoramic Study with Systematic Review

Koduri Sridevi<sup>1</sup>, N. Mahesh<sup>2</sup>, B. Krishnaveni<sup>2</sup>, A. D. N. Deepika<sup>3</sup>, V. Thejasri<sup>3</sup>, B. H. David Leninson<sup>3</sup>

<sup>1</sup>Professor, <sup>2</sup>Reader, <sup>3</sup>Senior Lecturer, Department of Oral Medicine and Radiology, Lenora Institute of Dental Sciences, Rajahmundry, Andhra Pradesh, India

ABSTRACT

**Aims and Objectives:** To evaluate the styloid process (SP) and its anatomical variations on digital panoramic radiographs from the database and also to synthesize the current evidence of literature on SP and anatomical variations along with the systematic review of the relevant studies after making the necessary exclusions.

**Materials and Methods:** A total of 500 panoramic radiographs from the database were examined and evaluated for the length of SP using OmniVue software and for the calcification patterns which were categorized into three types as described by Langlais. The obtained values were analyzed using *t*-test and Chi-square tests with a significance level of 0.005 and SPSS version 20.0 software.

**Results and Conclusion:** The mean length of the SP in females was found to be 3.7 cm on the right side and 3.8 cm on the left side. The mean length of the SP in males was found to be 3.4 cm on the right side and 3.3 cm on the left side with significant difference between the genders with the *P* values of 0.0002 and 0.0001, respectively. The length of the SP was significantly longer in females than in males. Type I was the most common SP and was more prevalent in females. The results of the present study along with the wide range of reported incidence of anatomical variations in the form of elongation from the literature extracted through the systematic review suggests the need to reevaluate the range of the normal length of the SP.

**KEYWORDS:** Calcification patterns, digital panoramic radiograph, styloid process

Received : 08-01-19.  
Accepted : 18-02-19.  
Published : 07-06-19.

## INTRODUCTION

Styloid process (SP) is a long slender and pointed bony process projecting downward, forward, and slightly medially from the temporal bone. It arises from the temporal bone immediately in relation to the anteromedial aspect of the stylomastoid foramen. It is located between the internal and external carotid arteries and the internal jugular vein, and it is typically straight and occasionally curved.<sup>[1]</sup>

Styloglossus, stylopharyngeus, and stylohyoid are the muscles attached to the SP from the tongue, pharynx, and hyoid bone, respectively.<sup>[2]</sup> The stylohyoid and stylomandibular ligaments extend from the tip of the SP to the lesser cornua of the hyoid bone and to the angle and posterior border of angle of the mandible between masseter and medial pterygoid, respectively.

These ligaments help to regulate the movements of the mandible, the hyoid bone, the tongue, and the pharynx.<sup>[3]</sup>


Many critical anatomic structures such as facial and hypoglossal nerves, occipital artery, internal jugular vein, internal carotid artery, and posterior belly of the digastric muscle are closely located to the SP and the stylohyoid ligament.<sup>[4-7]</sup> The elongation of SP can frequently be encountered by calcification of stylohyoid and stylomandibular ligaments, being the potentially

*Address for correspondence:* Dr. Koduri Sridevi, Department of Oral Medicine and Radiology, Lenora Institute of Dental Sciences, Rajahmundry, Andhra Pradesh, India. E-mail: srigivi123@gmail.com

This is an open access journal, and articles are distributed under the terms of the Creative Commons Attribution-NonCommercial-ShareAlike 4.0 License, which allows others to remix, tweak, and build upon the work non-commercially, as long as appropriate credit is given and the new creations are licensed under the identical terms.

For reprints contact: reprints@medknow.com

How to cite this article: Sridevi K, Mahesh N, Krishnaveni B, Deepika AD, Thejasri V, Leninson BH. Evaluation of styloid process and its anatomical variations: A digital panoramic study with systematic review. J Int Soc Prevent Communit Dent 2019;9:256-62.

Access this article online	
Quick Response Code: 	Website: <a href="http://www.jispcd.org">www.jispcd.org</a>
	DOI: 10.4103/jispcd.JISPCD_8_19

## Regenerative Capacity of Leukocyte-rich and Platelet-rich Fibrin in Indirect Sinus Elevation Procedure May be Dependent on Model-Specific Modification of the Centrifugation Cycle

### Abstract:

**Context:** To compare optical density (OD) and fibrinogen content of leukocyte-rich and platelet-rich fibrin (L-PRF) generated by standard protocol (2700 rotations per minute [RPM] for 12 min) versus relative centrifugal force (RCF)-adjusted protocol across two widely used laboratory centrifuges with swing-out rotors. **Aims:** Centrifuges for PRF production generate forces in excess of 800 g. The study aimed to evaluate OD, fibrinogen content and effectiveness in bone-added osteotome sinus floor elevation (BAOSFE) of leukocyte-rich and platelet-rich fibrin (L-PRF) generated by the standard protocol (2700 RPM for 12 min) versus a RCF-adjusted protocol to generate precisely 400 g of force across two centrifuges with swing-out rotors. The outcomes were compared to a standard centrifuge configured to generate L-PRF as per the original Choukroun guidelines. **Settings and Design:** Sample size for the present study was calculated using proportional power calculation. A minimum sample size of 8 per group was needed to detect a bone height difference of 2 mm when the power of the test is 0.80 at a significance level of 0.05. **Subjects and Methods:** Based on the centrifuge and protocol used to generate L-PRF, 10 participants were assigned to each of the following groups as follows: D group, fixed angle centrifuge (DUO Quattro\*) at default setting. R-O group: Swing-out centrifuge (Remi 8C\*) + standard protocol. R-A group: Remi 8C\* centrifuge + RCF-adjusted protocol. C-O group: Swing-out centrifuge (Remi C854\*) + standard protocol. and C-A group: Remi C854\* + RCF-adjusted protocol. OD, fibrinogen content, and gain in bone fill and bone height after BAOSFE were the evaluated outcomes. **Statistical Analysis Used:** Data were analyzed using GraphPad Prism\* Software version 6.0 (GraphPad Software Inc., La Jolla, USA) and SAS Software\* version 9.3 versions (SAS, New Delhi, India). Data were summarized by mean  $\pm$  standard deviation for continuous data and median  $\pm$  inter-quartile range for the score data. The comparison between different time points was done by analysis of one-way repeated measures test, followed by *post hoc* test for score data. The comparison between two groups for repeated data was made by analysis of two-way repeated measures test and followed by *post hoc* test. Spearman's Rho correlation test was used to test the correlation between prognosis and the other variables. **Results:** L-PRF from the Remi C854\* centrifuge with RCF-adjusted protocol showed OD ( $P = 0.152$ ) and fibrinogen content ( $P = 0.232$ ) identical to those from the DUO Quattro\* centrifuge. L-PRF from Remi 8C\* centrifuge with the RCF-adjusted protocol resulted in maximum postoperative bone height gain ( $7.01 \pm 1.44$  mm) and bone fill ( $13.50 \pm 4.51$  mm<sup>2</sup>) which was higher than that of the outcomes from the DUO Quattro\* centrifuge ( $6.82 \pm 2.92$  mm and  $12.32 \pm 5.31$  mm<sup>2</sup>). **Conclusions:** A reduction in RCF resulted in a less dense clot and had a positive influence on the regenerative potential of L-PRF in BAOSFE procedure.

**Keywords:** Alveolar ridge augmentations, centrifugation, maxillary ridge augmentations, platelet-rich fibrin

### Introduction

PRF is an autologous, second-generation platelet concentrate and is a healing biomaterial with great potential for the bone- and soft-tissue regeneration without initiating local inflammatory reactions.<sup>[1]</sup> The generation of PRF requires

a centrifugation cycle<sup>[1,2]</sup> which is dependent on the time, rotations per minute (RPM), angulation of the tubes to the axis of the rotor, and the g-force generated by the centrifuge (relative centrifugal force [RCF]).<sup>[1,3]</sup> In these terms, the standard protocol to generate leukocyte-rich and platelet-rich fibrin (L-PRF) is to run a centrifuge at 2700 RPM for 12 min at

This is an open access journal, and articles are distributed under the terms of the Creative Commons Attribution-NonCommercial-ShareAlike 4.0 License, which allows others to remix, tweak, and build upon the work non-commercially, as long as appropriate credit is given and the new creations are licensed under the identical terms.

For reprints contact: [reprints@medknow.com](mailto:reprints@medknow.com)

**How to cite this article:** Chandra RV, Vaishnavi V, S. Chakravarthy YS. Regenerative capacity of leukocyte-rich and platelet-rich fibrin in indirect sinus elevation procedure may be dependent on model-specific modification of the centrifugation cycle. *Contemp Clin Dent* 2019;10:433-9.

Rampalli Viswa  
Chandra,  
Varanasi Vaishnavi,  
Y. S. H. S.  
Chakravarthy

Department of Periodontics,  
SVS Institute of Dental Sciences,  
Mahbubnagar, Telangana, India

### Address for correspondence:

Dr. Y. S. H. S. Chakravarthy,  
Department of Periodontics,  
SVS Institute of Dental Sciences,  
Mahbubnagar - 509 002,  
Telangana, India.  
E-mail: [yshschakri@gmail.com](mailto:yshschakri@gmail.com)

### Access this article online

Website:  
[www.contempclindent.org](http://www.contempclindent.org)

DOI: 10.4103/ccd.ccd\_715\_18

### Quick Response Code:



# Applications of Diode Lasers in Periodontics: A Case Series

Shanmukha Srinivas Manikanta Kumar Tirumalasetty<sup>1</sup>, Gummadi Anusha<sup>1</sup>, Masapu Anupama<sup>1</sup>, Bharathi Devi Jonnalagadda<sup>1</sup>, Shyam Sunder Salavadhi<sup>2\*</sup> and Kotya Naik Maloth<sup>3</sup>

<sup>1</sup>Department of Periodontics, GSL Dental College, Andhra Pradesh, India; <sup>2</sup>Department of Periodontics, Mamata Dental College, Khammam, Telangana, India; <sup>3</sup>Department of Oral Medicine and Radiology, Mamata Dental College, Khammam, Telangana, India

Corresponding author:  
Dr. Shyam Sunder Salavadhi,  
Department of Periodontics,  
Mamata Dental College,  
Khammam, Telangana, India,  
Tel: 9959713715  
E-mail: dr.samsunder@gmail.com

## Abstract

Now-a-days, almost every specialty area of dentistry is utilizing the powers of laser energy for therapeutic purposes. The diode laser is the most popular soft tissue laser and commonly used in dentistry. A diode laser with wavelengths ranging from 810 to 980 nm in a continuous or pulsed mode is used as a possible instrument for soft tissue surgery in the oral cavity. The 810 nm devices predominate in dentistry, whereas 810 nm is specific for hemoglobin absorption. Diode lasers have many advantages over traditional surgical and therapeutic techniques in addition to providing bloodless surgical and post-surgical course with minimal swelling, scarring, and others things noted are less pain, excellent hemostasis, rapid wound healing and bactericidal action with the minimally invasive procedure. In the present paper, we discuss various uses of the diode laser such as esthetic crown lengthening procedure, excisional biopsy of pyogenic granuloma and gingival pigmentation in dentistry.

**Keywords:** Diode laser; Depigmentation; Pyogenic granuloma

## Introduction

Laser is an acronym for "Light Amplification by Stimulated Emission of Radiation." Laser is a Monochromatic, uni-directional and coherent beam of radiation that is produced by stimulated emission, a state where there are more excited atoms (i.e., more atoms in upper of two energy levels than in lower level), a condition called population inversion to obtain a radiation output greater than the incident radiation.<sup>[1]</sup> Many lasers with different active media were introduced since the advent of Maiman's ruby laser.<sup>[1,2]</sup> Diode lasers are most commonly used lasers in dentistry for soft tissue procedures. The aim of this paper is to highlight the various uses of diode lasers in periodontal surgical procedures.

## Clinical Applications of Diode Lasers

### Case 1: Esthetic crown lengthening

A 26-year-old male patient was presented with a chief complaint of gummy smile. [Figure 1a] On examination there was compromised smile esthetics because of excessive gingival display on smiling, the smile line was standard, and there is no vertical maxillary excess. The patient is systemically healthy and is not under any medication. A diagnosis of altered passive eruption type 1 sub-group A was made after periodontal examination according to Coslet et al.<sup>[3]</sup> Esthetic crown lengthening using diode lasers were done using the following settings [Figures 1b, 1c and 1d].

The parameters used are:

Pulsed mode – 50  $\mu$  sec pulse duration with a 100  $\mu$  sec pulse interval

Wavelength – 970  $\pm$  15 nm (Fiona Dental Laser)

Fiber diameter – 400  $\mu$ m

Power – 5 W

Mean Power – 1.67 W

### Case 2: Depigmentation

An 18-year-old female patient was reported with a chief complaint

of dark gums in both the jaws. [Figure 2a] On examination gingival pigmentation was displayed while smiling. Dummett–Gupta Oral Pigmentation Index (DOPI): Dummett<sup>[4]</sup> score was three which is moderate gingival pigmentation. Laser depigmentation was carried out for both maxillary and mandibular arches using the following settings [Figures 2b, 2c and 2d].

The parameters used are:

Pulsed mode – 50  $\mu$ sec pulse duration with 100  $\mu$ sec pulse interval

Wavelength – 810  $\pm$  10 nm (Denlase Dental Laser)

Fiber diameter – 400  $\mu$ m

Power – 4 W

Mean Power – 1.34 W

### Case 3: Pyogenic granuloma

A 29-year-old female patient reported with a chief complaint of swollen gums in the lower front tooth region, the lesion gradually increased in size throughout three months and said occasional bleeding while brushing. [Figures 3a] The patient was systemically healthy and was not using any drugs. Intraoral examination revealed a solitary, sessile lobulated gingival overgrowth extending on lingual surfaces of 42 and 43. It was reddish pink in color with white patches and was approximately 20 mm  $\times$  11 mm in size. Oval in shape with overlying surface was smooth. Radiographs like intraoral periapical radiograph showed no abnormalities, and a provisional diagnosis of pyogenic granuloma was made with a differential diagnosis of fibroma, peripheral

This is an open access article distributed under the terms of the Creative Commons Attribution-NonCommercial-ShareAlike 3.0 License, which allows others to remix, tweak, and build upon the work non-commercially, as long as the author is credited and the new creations are licensed under the identical terms.

How to Cite this Article: Kumar MSST, et al. Applications of Diode Lasers in Periodontics: A Case Series. Ann Med Health Sci Res. 2019;9:426-429

© 2019 Annals of Medical and Health Sciences Research



# VELOPHARYNGEAL DEFECTS AND THEIR PROSTHODONTIC MANAGEMENT – A REVIEW

\*Shreshta Sathish

\*Consultant Prosthodontist, Cochin | Corresponding author: Dr Shreshta Sathish, E mail: drshreshtasathish@gmail.com

## Introduction

Maxillofacial prosthetics is the branch of prosthodontics concerned with the restoration and/or replacement of stomatognathic and craniofacial structures with prostheses that may or may not be removed on a regular or elective basis.<sup>1</sup>

-GPT 9

Maxillofacial prosthesis is any prosthesis used to replace part or all of any stomatognathic and/or craniofacial structures.<sup>1</sup>

-GPT 9

Success in maxillofacial prosthetics depends on the full cognizance of the principles that underlie facial harmony, anchorage and retention, weight bearing and leverage, durability, tissue compatibility and tolerance.

The velopharynx is a dynamic anatomic structure which is essential for normal breathing, eating and speech. The soft palate acts as a separator between the oral and nasal cavities. Impairment of velopharyngeal function can be caused by either insufficiency or incompetency.

## Definitions

1. **Speech aid prosthesis-** a removable maxillofacial prosthesis used to restore an acquired or congenital defect of the soft palate with a portion extending into the pharynx to

separate the oropharynx and nasopharynx during phonation and deglutition, thereby completing the palatopharyngeal sphincter. (GPT9)<sup>1</sup>

2. **Palatal lift prosthesis** - a maxillofacial prosthesis that elevates the soft palate superiorly and aids in restoration of soft palate functions that may be lost because of an acquired, congenital or developmental defect.

*Definitive palatal lift prosthesis-* is usually made for patients whose experience with a diagnostic palatal lift has been successful, especially if surgical alterations are deemed unwarranted.

*Interim palatal lift prosthesis-* is usually made as a diagnostic aid to assess the level of possible improvement in speech intelligibility. (GPT 9)<sup>1</sup>

3. **Obturator** - a maxillofacial prosthesis used to close a congenital or acquired tissue opening, primarily of the hard palate and/or contiguous alveolar/soft tissue structures (GPT-7)<sup>2</sup>

## Speech

Speech, as formulated, executed, perceived and decoded, is unique to humans. The production of speech requires the selective modification and control of an outgoing airstream through the complex and skilled coordination of more than 100 muscles within the respiratory, laryngeal, velopharyngeal and oral mechanisms. This intricate process begins within the CNS, but also relies on PNS.

# A Multidisciplinary Outlook in Prosthodontics

V Chakradhar<sup>1</sup>, B Lakshmana Rao<sup>2</sup>, Satyanarayana S V Tammineedi<sup>3</sup>, Y S S Sruthi<sup>1</sup>, P S H L Parvathi<sup>1</sup>

<sup>1</sup>Postgraduate Student, Department of Prosthodontics, Lenora Institute of Dental Sciences, Rajahmundry, Andhra Pradesh, India, <sup>2</sup>Professor and Head, Department of Prosthodontics, Lenora Institute of Dental Sciences, Rajahmundry, Andhra Pradesh, India, <sup>3</sup>Reader, Department of Prosthodontics, Lenora Institute of Dental Sciences, Rajahmundry, Andhra Pradesh, India

## Abstract

Prosthodontic research needs to cover all aspects that can contribute to the clinical outcomes. Without a strong interdisciplinary relationship between other disciplines of dentistry and prosthodontics, the esthetic, functional, and/or biological outcome may be compromised and necessitate extensive and expensive retreatment. Through this paper, we would like to review the outline of the areas that overlap between prosthodontics and other branches of modern dentistry that dictates the interdisciplinary treatment.

**Key words:** Multidisciplinary prosthodontics, Oral radiology, Oral surgery, Orthodontics, Pedodontics, Periodontics

## INTRODUCTION

“Multidisciplinary” signifies the juxtaposition of disciplines. Interdisciplinary research has been gaining prominence across all domains of science, engineering, and social sciences. In the contemporary advanced period of dentistry, there is a need for the multidisciplinary approach to achieve biologically acceptable, esthetic, functional, and patient satisfactory treatment outcomes. For a patient overall rehabilitation process, there is a need of involving various specialties either for removing the pathologically active tissues or modifying the anatomically defective sites before the start of the prosthetic part of treatment.<sup>[1]</sup>

Prosthodontics is a branch of modern dentistry that deals mainly to restore the lost form, function, and the esthetics of the patients. Rehabilitation of the orofacial defects in accordance with the surrounding anatomical, physiological, and biological tissues requires the intervention of various disciplines starting from the diagnosis to better treatment outcomes such as oral radiology, periodontics, endodontics, orthodontics, and pedodontics. This article aims to outline the areas of overlap between prosthodontics and

other branches of modern dentistry that dictates the interdisciplinary treatment.

## WHAT'S MULTIDISCIPLINARY APPROACH?

Multidisciplinary dentistry refers to dental treatment that uses more than 1 type of dental strategy. This type of multilevel care occurs where there are various complex steps in treatment planning. The key is to build a team of likeminded, dedicated professionals who share a common goal of providing ideal oral health care to patients [Figure 1].

## BENEFITS

### For Clinician [Figure 2]


Improved patient care and outcome through the development of an agreed treatment plan, improved coordination of care, streamlined treatment pathways, and reduction in duplication of services.

### For Patient

Gets the most appropriate treatment decision made by a team of experts and improved satisfaction with treatment and care.

## ORAL RADIOLOGY

In the era of modern medicine and dentistry, the diagnostic pathway leads to the treatment planning phase

Access this article online	
 www.ijss-sn.com	Month of Submission : 06-2020
	Month of Peer Review : 06-2020
	Month of Acceptance : 07-2020
	Month of Publishing : 07-2020

Corresponding Author: Dr. V Chakradhar, Department of Prosthodontics, Lenora Institute of Dental Sciences, Rajahmundry - 533 294, Andhra Pradesh, India.

# A Novel Approach in Implant Dentistry - LIGAPLANTS

Jibi J<sup>1</sup>, Rao BL<sup>2</sup>, YSS Sruthi<sup>3</sup>, Pratyusha T<sup>4</sup>, Chitra C<sup>5</sup>

<sup>1,3,4,5</sup>Postgraduate Student, Department of Prosthodontics, Lenora Institute of Dental Sciences, NTR University, Andhra Pradesh  
<sup>2</sup>Professor & Head, Department of Prosthodontics, Lenora Institute of Dental Sciences, NTR University, Andhra Pradesh

**Abstract:** *In this modern era, implants have outmatched fixed and removable partial dentures for replacing missing teeth. Implants are now in currently use because of their long term survival rate. Still, problems exist with these implants as they lack periodontal ligament. Any inflammation around these implants may cause bone loss than does the inflammation around the natural tooth with periodontal ligament. This can be solved if implants with PDL (periodontal ligament) are developed and can be achieved by Ligaplants which are nothing but a combination of PDL cells with implant biomaterial. Hence this review article aimed to discuss the benefits of periodontio-integrated implants over osseointegrated implants.*

**Keywords:** Periodontal ligament, Osseointegration, Implant, Periodontium

## 1. Introduction

Dental implants have become a popular and effective way to replace missing teeth and have changed the face of dentistry over the last 25 years.<sup>1</sup> The boom in implant dentistry is attributed to a combination of various reasons like prolonged life span of aging individuals, failures associated with removable and fixed prostheses, advantages and predictable outcomes associated with use of implants.<sup>2</sup>

The **periodontal ligament**, commonly abbreviated as the **PDL**, is a group of specialized connective tissue fibers that essentially attach a tooth to the alveolar bone within which it sits. Periodontal ligament is also known as desmodont, gomphosis, pericementum, dental-periosteum, alveolodental ligament, periodontal membrane. Apart from anchoring of tooth, PDL progenitor cells help in alveolar bone formation and remodeling.<sup>3</sup>

Implants are retained in oral cavity by virtue of osseointegration i.e direct contact between living bone and the surface of a load carrying implant at histological level.<sup>1</sup> Osseointegrated implants are the ones which are currently in use because of their long term survival rate but they too poses problems as they lack periodontal ligament. Many<sup>2</sup> strategies have been experimented to improve the<sup>3</sup> osseointegrative property of the implant for example surface modification to improve the mechanical, physical, and<sup>4</sup> chemical characteristics of the implant, modification of<sup>5</sup> shape and design of implant, alteration of surface<sup>6</sup> topography, nanostructured surface coatings or addition of<sup>7</sup> growth factors to implant surface.<sup>2,4</sup>

To overcome these problems recent scientific research developed an implant with PDL, achieved by combination of the PDL cells with implant biomaterial and named it as **LIGAPLANTS**.<sup>2</sup> There is very less literature available on Ligaplants. Keeping this in mind we reviewed the properties, procedure of obtaining ligaplants, advantages and disadvantages.

### Ligaplants

Implants with PDL are placed in the extraction socket of the missing tooth, thereby facilitating the surgical procedure.

Natural implant anchoring might also be compatible with further growth and development of the alveolar bone housing, and it may allow tooth movements during orthodontic therapy. Ligaplants have the capacity to induce the formation of the new bone, when placed in sites associated with large periodontal defects.<sup>2,3</sup> [ Figure 1 ]

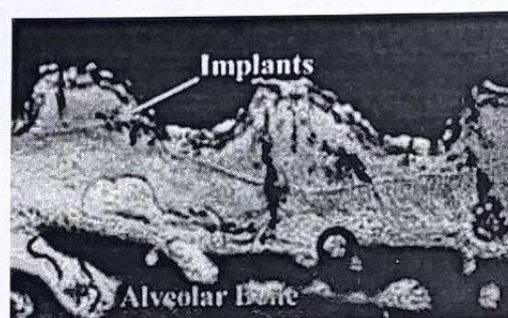


Figure 1: Ligaplants<sup>2</sup>

### Properties of ligaplants

PDL cells distributes forces, elicited during masticatory function and other contact movements to the alveolar process via the alveolar bone proper.<sup>2</sup>

It gives the tooth some movement in the socket by acting as a shock absorber.<sup>2</sup>

Proprioception is also provided by ligaplants.<sup>2</sup>

It also homes vital cells such as osteoblasts, osteoclasts, fibroblasts, cementoblasts, and most importantly undifferentiated stem cells which are osteoconductive in nature.<sup>2</sup>

### Procedure of obtaining Ligaplants

Transplantation of tooth with double PDL stimulation is one of the best examples of its healing capacity. The donor tooth is extracted and immediately replanted in its original alveolus, 14 days before transplantation. Cell proliferation and differentiation is seen as this deliberate trauma triggers a healing process within the PDL. The transplantation of the tooth can be performed with millions of cells full activity

Volume 8 Issue 3, March 2019

[www.ijsr.net](http://www.ijsr.net)

Licensed Under Creative Commons Attribution CC BY



**EFFECT OF DISINFECTION ON LINEAR DIMENSIONAL CHANGES AND SURFACE DETAIL REPRODUCTION OF VINYL SILOXANE ETHER (VINYL POLY ETHER SILICONE) V/S POLY VINYL SILOXANE AND POLYETHER - A COMPARATIVE IN VITRO STUDY**

**Sirisha G, Lakshmanarao Bathala\*, Nibhakumari Singh, Narendrakumar Rachuri, Karthik P and Hemanth kumar SVN**

Department of Prosthodontics, Lenora Institute of Dental Sciences, Rajanagaram, Rajamahendravaram, Andhra Pradesh, India

**ARTICLE INFO**

**Article History:**

Received 4<sup>th</sup> September, 2019

Received in revised form 25<sup>th</sup>

October, 2019

Accepted 23<sup>rd</sup> November, 2019

Published online 28<sup>th</sup> December, 2019

**Key words:**

Vinyl siloxane ether; Disinfection; Dimensional changes; Surface detail reproduction; Metal die, Impression, Polvinylsiloxane, Polyether.

**ABSTRACT**

**Introduction:** VinylSiloxaneEther, a novel impression material introduced recently was claimed to be better than the currently trending materials. No studies were conducted till now regarding the effect of disinfectants, Glutaraldehyde and Sodium hypochlorite on few properties of new material.

**Aim:** To evaluate effect of disinfectants on dimensional accuracy and surface detail reproduction of Vinyl Siloxane Ether (VSE) versus Poly Vinyl Siloxane (PVS) and Polyether (PE).

**Methodology and results:** A total of 120 impressions were made from a metal die (ADA no.19), grouped as A, B and C based on the impression material and further sub grouped as AG,AH;BG,BH;CG,CH based on disinfectant used. Measurements were taken to evaluate linear dimensional changes and surface detail reproduction; formulated with one way ANOVA statistical analysis and executed with the help of IBM SPSS 21.0 software. Value of  $p < 0.05$  was considered to be significant. More dimensional changes occurred in Group-A,PVS(0.0114mm), followed by Group-C,VSE(0.0110mm) and then by Group-B,PE(0.0090mm). Dimensional changes caused by glutaraldehyde is less than that of by Sodiumhypochlorite. Regarding surface detail reproduction, PE showed better results than PVS and VSE materials.

**Conclusion:** PE presented better dimensional accuracy and produced good surface details comparatively. VSE showed significant expansion after disinfection. Sodium hypochlorite caused more dimensional changes than glutaraldehyde, however statistically and clinically insignificant.

Copyright©2019 Sirisha G et al. This is an open access article distributed under the Creative Commons Attribution License, which permits unrestricted use, distribution, and reproduction in any medium, provided the original work is properly cited.

**INTRODUCTION**

Dimensional accuracy and surface detail reproduction are some of the indispensable qualities for best possible impressions [19] (Stober T *et al.*,2010). Besides transferring the required information; these traditional impressions also act as a remarkable source for cross contamination of various microbial organisms from infected saliva and blood to which they have been exposed. Set impressions are a supply of reservoir of pathogens which contain micro-organisms like bacteria, fungi and viruses following their removal from patient's mouth and while the models are being poured, these microorganisms are transmitted onto dental plaster and stone. Such models embody a potential chance of disease transmission to dental health care workers and laboratory employees through indirect contact [24, 8](Thota K K *et al.*,2014; Khan A *et al.*,2015).

\*Corresponding author: **Lakshmanarao Bathala**

Department of Prosthodontics, Lenora Institute of Dental Sciences, Rajanagaram, Rajamahendravaram, Andhra Pradesh, India

Simply washing with water or rinsing under tap water does not completely eliminate these contaminating microbes from the impression surface [14](Melilli D *et al.*,2008). Therefore, pursuing a suitable infection control protocol before and after impression making is a must to get clear of cross contamination and the risk of disease transmission[24] (Thota K K *et al.*,2014).

Disinfecting the impressions with appropriate disinfectants before they are delivered to the lab may reduce the risk. Disinfection procedure can be done either by immersion method or by spray method. Immersion disinfection is appreciated to be more potent, effective and authentic rather than disinfection by spray method [8](Khan A *et al.*,2015). In the present days, Elastomers are the widely used impression materials because of their excellent dimensional stability, detailed reproduction and their ability to retain the properties even after the disinfection procedures. Very recently, a new material has been developed based on 'Best of both Worlds' concept, Vinyl Siloxane Ether (VSE)[9](Kronstrom M H *et*



## RATIONALITY OF RIDGE MAPPING TO ASSESS THE BUCCO-LINGUAL WIDTH OF THE ALVEOLAR BONE – A REVIEW.

### Dental Science

<b>Dr. Lakshmanarao Bathala*</b>	Prof & HOD, Department of Prosthodontics, Lenora Institute of Dental Sciences, Rajanagaram, Rajahmundry, A.P. *Corresponding Author
<b>Dr. Kotaiah Teruru</b>	Prof & HOD, Department of Pedodontics, Govt. Dental College and Hospital, Vijayawada, A.P.
<b>Dr. Satyanarayana T. S. V</b>	Reader, Department of Prosthodontics, Lenora Institute of Dental Sciences, Rajanagaram, Rajahmundry, A.P.
<b>Dr. Nibha kumari Singh</b>	Reader, Department of Prosthodontics, Lenora Institute of Dental Sciences, Rajanagaram, Rajahmundry, A.P.
<b>Dr. Sirisha G</b>	Senior Lecturer, Department of Prosthodontics, Lenora Institute of Dental Sciences, Rajanagaram, Rajahmundry, A.P.

### ABSTRACT

**Aim:** To review the validity of Ridge Mapping technique as reliable method to assess the bucco-lingual ridge width prior to implant placement.  
**Materials and Method:** The literature search was done electronically and also hand searched with the terms such as Ridge Mapping, Alveolar Ridge Width, Implants and Bucco-Lingual Width. The search was limited to full text articles which are published in English language only. The search was performed through Medline and Google. A total of 85 articles were found and out of these 66 were not related to present search and hence were excluded from the study. Finally 19 articles were found to be relevant.  
**Results:** All the techniques having some advantages and disadvantages with reliable results.  
**Conclusion:** The results of the study showed that, the Ridge Mapping is a reliable, simple and easy to perform at chair side technique to assess the bucco-lingual width of the alveolar ridge.

### KEYWORDS

Alveolar Ridge Width; Implants; Ridge Mapping; Bucco-Lingual Width.

### INTRODUCTION:

Accurate evaluation of alveolar ridge dimensions is necessary for the long term success of the implant. At least 1mm bone width should be available adjacent to the implant, whereas in the esthetic region 3mm of bone should be required throughout the osseogingival relationship, to reduce gingival recession.<sup>1</sup> Different authors described different methods for assessing the alveolar ridge width prior to implant placement, such as CBCT, Linear Tomography, Ultrasonography, IOPA in Occlusal Projection, Ridge Mapping (RM) and Gold standard Direct Surgical Exposure technique (G.S.D.S).<sup>2,3,4,5,6,7,8,9</sup>

The edentulous ridge site having 3 dimensions, they are length, width and depth. The mesio-distal dimension is the length, the Bucco-lingual is the width and from the crest of the ridge to the adjacent limiting anatomic landmark is the depth. To keep soft tissue level stable, the bone width should be greater than 1mm present on either side of the implant facio lingually, especially in the facial side problem of bone resorption may lead to esthetically unacceptable condition. In an ideal situation the implant width at least 3mm less than the bucco-lingual dimension of the bone. Knowing the physical measurements of the existing alveolar bone prior to implant surgery is a key aspect in the treatment planning.<sup>10</sup> The IOPA and Panoramic radiographs are 2-D in nature, and will not divulge the details on the sagittal bone morphology.<sup>8,11,12</sup>, whereas with three-dimensional imaging evaluation of both quantity and quality of bone as well as important anatomical structures, but having some disadvantages like radiation, image production time, images of metallic tooth restorations distorts and economic burden to the patient.<sup>8</sup>

The CBCT can be more helpful in the area where the vestibular depth is insufficient and ridge mapping is not practicable, where the ridge height is less, anterior ridge concavities present in the maxillary anterior region and high lingual frenum present. But CBCT having some disadvantages like if any metal restorations present, then it is completely not dependable method, also if any tiny change in the width of the alveolus may not display notable on the scan. The CT scan is more useful in restricting the bucco-lingual position of the inferior

dental nerve.

Contrarily to get control of the constraints of the conventional radiography, alternative clinical techniques have been invented to calculate transversal alveolar bone such as Ridge mapping technique.<sup>6,7,8</sup> Ridge mapping can assess the bucco-lingual dimension of the ridge. It can provide immediate details and is a chair side procedure. Wilson DJ et al.,<sup>9</sup> and Traxler et al.,<sup>4</sup> advocated the technique of measuring the ridge width with specially designed caliper. The proponents of Ridge Mapping technique claimed that, this is an authenticated procedure for evaluating appropriability of probable site for implant. Having some drawback that, if the overlying mucosa is extremely thick then the results may vary and manual error of applying the uniform pressure while measuring may also be considered.<sup>4</sup> RM is uncomplicated and useful method to assess the thickness of the bone, RM required LA but it is not a factor for most patients.<sup>6</sup> The direct surgical exposure method is a 'gold standard' because the actual measurements of the bone can be made with calipers after exposure of the mucoperiosteum.<sup>7,8</sup> In the literature different studies mentioned different techniques to assess the width of the alveolar bone prior to implant placement along with some disadvantages. Out of all the techniques the proponents of RM technique claimed that it is a simple, chair side and reliable technique with fewer complications. Hence the aim of this research study is to furnish upfront information regarding the rationality of RM for the determination of edentulous ridge measurements for pre surgical implant treatment procedure.

### Methodology:

The literature search was done electronically and also hand searched with the terms such as Ridge Mapping, Alveolar Ridge Width, Implants and Bucco-Lingual Width. The search was limited to full text articles which are published in English language only. The relevant papers and identified articles from the reference list were also assessed. The search was performed through Medline and Google between January 2016 and March 2019. A total of 85 articles were found and out of these 66 were not related to present search and hence were excluded from the study. Finally 19 articles were found to be relevant. The strategy of search is mentioned in flow chart.



**ORIGINAL RESEARCH PAPER**

**Prosthodontics**

**NEOTERIC SINUS ELEVATION : A SMART LIFT – DIVA IMPLANTS**

**KEY WORDS:** Dental Implant; Maxillary Sinus Floor Lifting; Bone Augmentation; Dynamic Implant Valve Approach (DIVA) implants

<b>Sruthi YSS</b>	PG Student Department of Prosthodontics, Lenora Institute of Dental Sciences, Rajanagaram, Rajamahendravaram, Andhra Pradesh, India.
<b>Rao BL*</b>	Professor and HOD Department of Prosthodontics, Lenora Institute of Dental Sciences, Rajanagaram, Rajamahendravaram, Andhra Pradesh, India. *Corresponding Author
<b>Jibi J</b>	PG Student Department of Prosthodontics, Lenora Institute of Dental Sciences, Rajanagaram, Rajamahendravaram, Andhra Pradesh, India.
<b>Pallavi C</b>	PG Student Department of Prosthodontics, Lenora Institute of Dental Sciences, Rajanagaram, Rajamahendravaram, Andhra Pradesh, India.

**ABSTRACT**

Contemporary dentistry started appreciating the importance of anatomy of the maxillary sinus and the bone quality of maxillary bone when the restorations began shifting from tooth supported fixed prosthesis to the implant supported prosthesis. The low position of floor of sinus posed problems for the implant placement, literature suggesting many procedures for sinus floor lifting with different augmentation substitutes. Complications are still unavoidable and may lead to implant failure. The main goal of the implantology is to increase the longevity of implants by exact implant placement into bone of sufficient density. It is known that maxillary bone exhibits significantly lower bone mineral density than the mandible. Bone augmentation with bone substitutes has become the common procedure in increasing the density of the maxillary bone. New stimulus has been gained by the dental implantology by the introduction of the Dynamic Implant Valve Approach (DIVA) implants.

**INTRODUCTION**

The maxillary sinus, largest of paranasal sinuses is pyramidal in shape with its base parallel to lateral nasal wall and apex pointing towards zygoma. The size of the maxillary sinus remains insignificant until the permanent dentition fully erupts. The average dimensions of adult sinus are 2.5 to 3.5 cm in width, 3.6 to 4.5 cm in length and 3.8 to 4.5 cm in depth. The size of sinus will increase with age if the area is edentulous. Also, pneumatization varies from person to person. It has an estimated volume of approximately 12 to 15 cm<sup>3</sup>. The inner lining of the maxillary sinus is lined by pseudo-stratified ciliated epithelium known as Schneiderian membrane with an average thickness of 0.8mm and is continuous with nasal epithelium through the ostium in middle meatus. The superior wall is formed by the floor of the orbit, anterior wall constituted by facial portion of maxillary bone, posterolateral wall constituted by zygomatic bone and greater wing of sphenoid and floor is constituted by the alveolar process and the palatal process of maxilla. It extends between adjacent teeth or individual roots, creating elevations of the antral surface, commonly referred to as 'hillocks'. Because of the implications, this can have on surgical procedures; it is essential for the clinicians to be aware of the exact relationship between the roots of the maxillary teeth and the maxillary sinus floor<sup>2,3,4</sup>.

When patients present with advanced ridge resorption, it could complicate the procedure of implant surgery. This problem is magnified in the posterior maxilla where ridge resorption and sinus pneumatization, compounded with a poor quality of bone, are often encountered<sup>4,5</sup>. The procedure of choice to restore this anatomic deficiency is maxillary sinus floor elevation. Maxillary sinus floor elevation (SFE) was initially described by Tatum at an Alabama implant conference in 1976 and subsequently published by Boyne in 1980. The procedure is one of the most common pre-prosthetic surgeries performed in dentistry today. Numerous articles have been published in this field regarding different grafting materials and modification to the classic technique<sup>6</sup>. Field of implantology always haunts for the new technique and the new material to overcome the demerits of the techniques that are already present. Keeping this in mind through this review, we would like to bring up the new technique for sinus floor lifting and implant placement using DIVA implants.

**SINUS LIFT PROCEDURE:-**

The insertion of the implants in posterior Maxilla is often complicated due to the inadequate bone quantity and quality.

- For the placement of an implant the height of the ridge should be at least 5-6mm (summers 1994)<sup>6</sup>
- If it is less than 5mm then the sinus floor is elevated and grafting is performed to maintain the height<sup>6</sup>.
- It is performed mainly by 2 techniques<sup>6</sup>:-
  - a) direct sinus lift
  - b) indirect sinus lift Based on the implant placement after sinus lift<sup>6</sup>:-
    - a) immediate placement of an implant
    - b) delayed placement of an implant

**SINUS LIFT PROCEDURES**

There are many procedures available in the literature on sinus lift. Some of them are<sup>6</sup>:

1. Transcrestal Approach (tSFE):
2. Lateral Window Approach (LatW)
3. Piezoelectric Surgery (PS)
4. Balloon elevation technique
5. Hydraulic Sinus Lift Technique (HySiLift)
6. Osteotome Technique (OstSFE)
7. Nasal suction technique

**COMPLICATIONS:**

The surgical procedures may have some of the following complications<sup>6,7</sup>:-

**IMMEDIATE INTRA OPERATIVE:**

- Membrane perforation
- Haemorrhage from vessels
- Mechanical obstruction to the ostium
- Infraorbital nerve injury

**EARLY POST OPERATIVE:**

- Wound dehiscence
- Acute graft infection
- Haemorrhage
- Exposure to the bone graft

**DELAYED POST OPERATIVE:**

- Chronic sinusitis
- Exposure to the bone graft

**LATE COMPLICATION:**

- Intra cranial abscess
- Blindness



Available online at  
**ScienceDirect**  
www.sciencedirect.com

Elsevier Masson France  
**EM|consulte**  
www.em-consulte.com/en



Original article

## Predictability and Feasibility of Total Alloplastic Temporomandibular Joint Reconstruction using DARSN TM Joint Prosthesis for patients in Indian subcontinent—A prospective clinical study

D. Bhargava<sup>a,\*</sup>, R.S. Neelakandan<sup>b</sup>, Y. Sharma<sup>c</sup>, V. Dalsingh<sup>d</sup>, S. Beena<sup>a</sup>, P. Gurjar<sup>a</sup>

<sup>a</sup>Department of Oral and Maxillofacial Surgery, People's College of Dental Sciences and Research Center, People's University, 462037 Bhanpur, Bhopal, Madhya Pradesh, India

<sup>b</sup>MAHER, Department of Oral and Maxillofacial Surgery, Meenakshi Ammal Dental College and Hospital, Chennai, Tamil Nadu, India

<sup>c</sup>Department of Oral and Maxillofacial Surgery, People's Dental Academy, People's University, 462037 Bhanpur, Bhopal, Madhya Pradesh, India

<sup>d</sup>Department of Oral and Maxillofacial Surgery, Lenora Institute of Dental Sciences, Rajahmundry, Andhra Pradesh, India

### ARTICLE INFO

**Article history:**  
Received 9 April 2019  
Accepted 18 June 2019

**Keywords:**  
Temporomandibular joint disorder  
Ankylosis  
Arthroplasty  
Prosthesis and Implants  
Quality of life  
Joint replacement

### ABSTRACT

**Purpose:** The aim of this study was to investigate the feasibility of a custom made alloplastic Temporomandibular Joint (TMJ) device design in patients undergoing temporomandibular (TM) Total Joint Reconstruction (TJR).

**Objective:** TMJ disease with functional and anatomic distortion dictates the need for TJR. There are various materials to reconstruct a TMJ. However, various factors, such as cost, availability of prosthetic joint, limit its use to tertiary health care center. Hence, we have investigated the feasibility and efficacy of the custom made alloplastic TMJ prosthesis (DARSN TM Joint Prosthesis) with the advantage of being acceptable financially and the overall Quality of life (QoL) diagnosed with TMJ ankylosis and End Stage Joint Disease (ESJD) selected from the study population.

**Materials and methods:** The study group comprised of 20 patients with TMJ ankylosis or End Stage Joint Disease (ESJD) who needed TM TJR of which few subjects in the study population had history of failed previous surgery to the TMJ region. The patients underwent resection of the joint followed by TJR using the custom made alloplastic TMJ prosthesis. Various subjective and objective variables were evaluated such as the Jaw Function (JF), Inter-incisal opening (IO), Diet intake (DI), Quality of Life (QoL) using a Psychometric Modified Likert Scale and nutritional status of the patient using the Mid-Upper Arm Circumference (MUAC) as reference.

**Results:** All the subjective and objective variables showed significant improvement in the postoperative period as compared to the preoperative period. The JF score increased with a mean score of 6.25 ( $P < 0.00001$ ). Postoperative mean DI score was 3.15 ( $P < 0.00001$ ) and IO increased up to 29–38 mm in 95% of the study population. The study population exhibited an improved overall QoL and nutritional status post-operatively. Follow up period of 1 year showed significant functional improvement among the study population.

**Conclusion:** The results shows that the custom made alloplastic joint replacement is safe and effective and reliable alternative to treat patients with TMJ disease which restricts the normal function to a greater degree requiring TM TJR.

© 2019 Elsevier Masson SAS. All rights reserved.

### 1. Introduction

Alloplastic total temporomandibular joint (TMJ) reconstruction restores function and form of the TMJ and it is indicated in patients diagnosed with wide range of joint pathologies such as

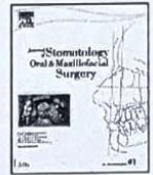ankylosis, neoplasia that may require extensive resection of the TMJ, failed autogenous graft, and mutilative joint disease among the few. Temporomandibular disorders related pain has a significant psychosocial impact on patients with strong female predilection. [1] With the increasing evidence of success of alloplastic prosthesis in orthopedic literature and the growing need to provide a definitive treatment for TMJ disorders, the various artificial TMJs are being investigated and some of them are in use.

\* Corresponding author. Private Practise, H-3/2, BDA Colony, Nayapura, Lal Ghati, Airport Road, Bhopal, 462001, Madhya Pradesh, India  
E-mail address: emaildarpan@gmail.com (D. Bhargava).



Available online at  
**ScienceDirect**  
www.sciencedirect.com

Elsevier Masson France  
**EM|consulte**  
www.em-consulte.com/en



Original article

## Comparison of latency and efficacy of twin mix and modified twin mix in impacted mandibular third molar surgery – A Preliminary Randomized Triple Blind Split Mouth Clinical Study

S. Beena<sup>a</sup>, D. Bhargava<sup>a,\*</sup>, P. Gurjar<sup>a</sup>, S. Shrivastava<sup>a</sup>, V. Dalsingh<sup>b</sup>, G. Koneru<sup>c</sup>

<sup>a</sup> Department of Oral and Maxillofacial Surgery, People's College of Dental Sciences and Research Center, People's University, H-3/2, B.D.A Colony, Nayapura, Lal Ghati, Airport Road, 462037 Bhanpur, Bhopal, MP, India

<sup>b</sup> Head, Department of Oral and Maxillofacial Surgery, Lenora Institute of Dental Sciences, 533294 Rajahmundry, AP, India

<sup>c</sup> Sibar Institute of Dental Sciences and Research Center, Department of Oral and Maxillofacial Surgery, 522509 Vijayawada, AP, India

### ARTICLE INFO

**Article history:**  
Received 30 January 2019  
Accepted 12 July 2019

**Keywords:**  
Local Anesthesia  
Twin Mix  
Pain  
Dexamethasone  
Lidocaine  
Third molar  
Dexamethasonized Local anesthesia

### ABSTRACT

**Introduction:** Intra-space drug administration have recently gained popularity in the clinical practice posing several advantages over the conventional routes of drug administration. A preliminary prospective randomized triple blind clinical study was conducted to compare the latency and duration of anesthesia with twin mix (1.8 ml 2% lignocaine with 1:200,000 epinephrine and 1 ml/4 mg dexamethasone) and modified twin mix (1.7 ml of 4% articaine with 1:100,000 epinephrine and 1 ml/4 mg dexamethasone) to two conventional local anesthesia solutions along with co-relation of clinical effects in the postoperative phase in patients undergoing extraction of impacted mandibular third molars in terms of patients comfort post-surgery.

**Materials and Methods:** The study was conducted among 20 patients with bilateral impacted mandibular third molars who were randomly allotted to two groups, Group A and B. Each patients in both the groups was allotted with study and control site. Among Group A, patients were further divided into Sub-group L (Control) and Sub-group TM (Twin Mix). Group B patients were divided as Sub-group A (Control) and sub-group MTM (Modified Twin Mix). Sub-group L patients received 1.8 ml of 2% lignocaine with 1:200,000 adrenaline and sub-group TM received twin mix. Sub-group A received 1.7 ml of 4% articaine with 1:100,000 adrenaline and sub-group MTM received modified twin mix solution. All the procedure was performed by a single operator with a gap of 1 month between the two interventions among both the groups. Various subjective and objective parameters were measured pre-operatively and postoperatively to assess the latency and efficacy of various anesthesia solutions used in this study for third molar removal.

**Results:** Mean ( $\pm$ SD) VAS scores for sting on injection and pain were found to be less in TM and MTM sub-group with a score of 2.3 ( $\pm$ 0.768) and 2.7 ( $\pm$ 0.065) respectively. The anesthetic latency was significantly less in sub-group TM, with a mean ( $\pm$ SD) of 52.4 ( $\pm$ 28.3) seconds. Sub-groups A and MTM had longer latency of anesthesia when compared with L and TM sub-groups. The duration of soft tissue anesthesia was maximum in sub-group MTM as compared to the other sub-groups. Patients from control sub-groups among both the groups had increased swelling, post-surgical pain and trismus postoperatively.

**Discussion:** Intra-space administration of twin mix and modified twin mix is clinically efficacious in impacted mandibular third molars surgery with better clinical outcomes postoperatively. We observed one significant difference between TM and MTM that the latter solution provided a prolonged duration of anesthesia increasing the patient's comfort postoperatively after surgical removal of mandibular third molars.

© 2019 Elsevier Masson SAS. All rights reserved.

\* Corresponding author. TMJ Consultancy Services (South East Asia), H-3/2, B.D.A Colony, Nayapura, Lal Ghati, Airport Road, 462 001 Bhopal, Madhya Pradesh, India  
E-mail address: emaildarpan@gmail.com (D. Bhargava).



# Evaluation of the Clinical and Radiological Outcomes of Pulpotomized Primary Molars Treated with Three Different Materials: Mineral Trioxide Aggregate, Biodentine, and Pulpotec. An In-vivo Study

Raparla Mythraiye <sup>1</sup>, VV Rao <sup>1</sup>, MS Minor Babu <sup>1</sup>, Martha Satyam <sup>1</sup>, Punithavathy R. <sup>2</sup>, Chandrika Paravada <sup>1</sup>

1. Pedodontics and Preventive Dentistry, Lenora Institute of Dental Sciences, Rajahmundry, IND 2. Pedodontics and Preventive Dentistry, Lenora Institute of Dental Sciences, Rajahmundry, IND

✉ Corresponding author: Raparla Mythraiye, drmythi@gmail.com

Disclosures can be found in Additional Information at the end of the article

---

## Abstract

### Introduction

The main treatment objective of pediatric dentistry lies in maintaining the integrity of the arches. The loss of primary teeth at an early age causes malocclusion. Primary teeth are considered the best space maintainers in the arch. Hence, every effort should be directed to preserve these teeth as far as possible. One of the most important goals of pediatric dentistry is the restoration of carious primary teeth and the maintenance of optimal oral health.

### Aim

The aim of this study is to compare and evaluate different pulpotomy materials like mineral trioxide aggregate (MTA), Biodentine, and Pulpotec in primary molars.

### Materials and methods

In the present study, 84 primary molars were selected for the pulpotomy procedure and randomly assigned to one of the three groups of MTA, Biodentine, and Pulpotec, allocating 28 primary molars to each group. The pulpotomy procedure was performed on all selected teeth and followed by permanent restoration with stainless steel crowns. All the molars were evaluated, both clinically and radiographically, at an interval of one, three, and six months.

### Results

At the end of the first month, there were no adverse clinical and radiographical findings observed in all three groups. At the end of the third month, Group I showed 96% clinical and radiographical success, Group II showed 100% clinical and 96% radiographical success, and Group III showed 100% clinical and radiographical success. At the end of the sixth month, Group I showed 96% clinical and radiographical success, Group II showed 100% clinical and 90% radiographical success and Group III showed 100% clinical and radiographical success. The observations were subjected to statistical analysis using Fisher's exact test and the Chi-square test.

### Conclusion

#### How to cite this article

Mythraiye R, Rao V, Minor Babu M, et al. (June 02, 2019) Evaluation of the Clinical and Radiological Outcomes of Pulpotomized Primary Molars Treated with Three Different Materials: Mineral Trioxide Aggregate, Biodentine, and Pulpotec. An In-vivo Study. Cureus 11(6): e4803. DOI 10.7759/cureus.4803

Received 04/21/2019  
Review began 05/09/2019  
Review ended 05/13/2019  
Published 06/02/2019

© Copyright 2019  
Mythraiye et al. This is an open access article distributed under the terms of the Creative Commons Attribution License CC-BY 3.0., which permits unrestricted use, distribution, and reproduction in any medium, provided the original author and source are credited.

# Dental Professionals as a Counsellor for Tobacco Cessation: A Survey

Vijay Chandar Vinod, Lavina Taneja, Palkin Mehta, Sridevi Koduri<sup>1</sup>

Department of Oral Medicine and Radiology, Faculty of Dental Sciences, SGT University, Gurgaon, Haryana, <sup>1</sup>Department of Oral Medicine and Radiology, Lenora Institute of Dental Sciences, Rajanagaram, Andhra Pradesh, India

## Abstract

**Aim:** To evaluate the role of oral physicians as a counsellor in tobacco cessation. **Materials and Methods:** A questionnaire was designed and distributed among 110 randomly selected participants, i.e., students (interns) and dental professionals. The questions were meant to assess the level of the knowledge, attitude, and effectiveness of dental students and professionals towards tobacco cessation. **Result:** A total of 100 participants responded to the survey, thus the response rate was 90.9%. A total of 77.4% were comfortable handling patients with tobacco dependence, 78.6% stressed on history pertaining to tobacco, and 87.6% did counselling habitually. Only 5.4% had received additional training for the same and only 5% thought training received was sufficient. Majority of dentists were doing counselling by asking and advising, and limited participants were using nicotine replacement therapy and other pharmacological and behavioural therapies, and only 24.7% were referring patients of high dependence to psychiatrists. **Conclusion:** The present study concluded that though dentists had a positive attitude towards tobacco cessation and were stressing on history and warning and advising to quit, more emphasis on pharmacological and behavioral therapies should be given. This can be achieved through alteration in the curriculum and attending more continuing dental education (CDE) programmes to update the knowledge regarding tobacco cessation intervention means and referring patients with heavy dependence to psychiatrists.

**Keywords:** Cessation, counsellor, dentist, dependence

## INTRODUCTION

Globally, one of the greatest health challenges of today is tobacco epidemic. Tobacco-related mortality in India alone is among the highest in the world, with about 700,000 annual deaths attributable to smoking alone.<sup>[1]</sup> Data from the global adult tobacco survey (GATS) India (2010) revealed that more than one out of three adults in India (35%) use tobacco in one form or the other.<sup>[2]</sup> India's tobacco-related problem is unique in its own way due to its acceptance both culturally and traditionally. Moreover, use of smokeless tobacco is typically high in India and South East Asian countries. Both smoked and smokeless forms of tobacco contain nicotine, a highly addictive chemical, making it difficult for habituated tobacco users to quit.<sup>[3,4]</sup> Over time, users become dependent on nicotine and suddenly stopping produces physical as well as psychological withdrawal symptoms.<sup>[5-7]</sup>

Tobacco dependence is a chronic condition that often requires repeated interventions.<sup>[8,9]</sup> Involvement of health professionals in the tobacco epidemic is an essential way to combat it. Since

oral physicians are the first to note any changes that can occur in the oral cavity, they can play a major role in prevention and intervention of this deleterious habit. Hence, the present study was designed to evaluate the role of dental professionals towards motivation for tobacco cessation. The objectives of the study were to assess if the dental practitioner is able to educate, motivate, and counsel the patient with tobacco dependence and to assess the level of the knowledge, attitude, and effectiveness of dental students and professionals towards tobacco cessation.

## MATERIALS AND METHODS

A printed survey proforma was distributed to a total 110 dental students and professionals including interns, postgraduate

Address for correspondence: Dr. Lavina Taneja,  
A 150 Second Floor, Lok Vihar Pitampura, New Delhi, India.  
E-mail: [aryalavina@gmail.com](mailto:aryalavina@gmail.com)

This is an open access article distributed under the terms of the Creative Commons Attribution-NonCommercial-ShareAlike 3.0 License, which allows others to remix, tweak, and build upon the work non-commercially, as long as the author is credited and the new creations are licensed under the identical terms.

For reprints contact: [reprints@medknow.com](mailto:reprints@medknow.com)

How to cite this article: Vinod VC, Taneja L, Mehta P, Koduri S. Dental professionals as a counsellor for tobacco cessation: A survey. *J Indian Acad Oral Med Radiol* 2017;29:209-12.

Received: 28-01-2017 Accepted: 05-11-2017 Published: 20-11-2017

### Access this article online

Quick Response Code:



Website:  
[www.jiaomr.in](http://www.jiaomr.in)

DOI:  
10.4103/jiaomr.JIAOMR\_44\_16

# Proposed Mechanism of Action for Twin Mix Anaesthesia When Used as Intra-space Pterygomandibular Injection for Inferior Alveolar Nerve Block with Emphasis on Effects of Perineural Injection of Dexamethasone

Darpan Bhargava, Ganesh Koneru<sup>1</sup>, Ashwini Deshpande<sup>2</sup>, Khushboo Desai<sup>3</sup>, V Dalsingh<sup>4</sup>

Department of Oral and Maxillofacial Surgery, People's College of Dental Sciences and Research Center, People's University, <sup>2</sup>Department of Oral Medicine and Radiology, People's Dental Academy, People's University, Bhopal, Madhya Pradesh, <sup>1</sup>Department of Oral and Maxillofacial Surgery, Sibar Institute of Dental Sciences, Guntur, <sup>4</sup>Department of Oral and Maxillofacial Surgery, Lenora Institute of Dental Sciences, Rajahmundry, Andhra Pradesh, <sup>3</sup>Department of Periodontics, Karnavati School of Dentistry, Ahmedabad, Gujarat, India

## Abstract

There has been recent research on the use of dexamethasone as an adjunct to local anaesthetics to enhance the block characteristics and improve post-operative pain outcomes. Numerous studies have shown that perineural dexamethasone improves post-operative analgesia, along with other clinical benefits. Intra-space pterygomandibular twin mix anaesthesia is a novel technique for inferior alveolar nerve block used for mandibular anaesthesia. Twin mix anaesthesia has its advantages in shortening the latency and prolonging the duration of the soft tissue anaesthesia, along with improving the quality of life in the post-operative period after mandibular oral surgical procedures. The concern regarding the use of perineural dexamethasone has been discussed.

**Keywords:** Anaesthesia, dental anaesthesia, dexamethasone, inferior alveolar nerve block, lignocaine, local anaesthesia, mandible, twin mix

## INTRODUCTION

Co-administration of steroid and local anaesthetics (LAs) has shown some clinical benefits in the recent research. Perineural dexamethasone injection improves post-operative pain outcomes when given as an adjunct to LA blocks with no clinical evidence of persistent neural damage or functional alteration after perineural administration of the drug.<sup>[1]</sup> Authors had proposed the co-administration of 2% lignocaine with 1:200,000 epinephrine and 4 mg dexamethasone (twin mix) as intra-space pterygomandibular injection for inferior alveolar nerve blocks for surgical removal of impacted mandibular third molars.<sup>[2]</sup> Twin mix intra-space pterygomandibular anaesthesia has its advantages in shortening the latency and prolonging the duration of the soft tissue anaesthesia, along with improving the quality of life in the post-operative period after surgical extraction of mandibular third molars. Patients who receive a mixture of 2% lignocaine with 1:200,000 epinephrine and

4 mg dexamethasone show lesser swelling and better mouth opening in the post-operative period when compared to patients who receive lignocaine with epinephrine blocks. This review discusses the possible mechanisms involved in the action of this mixture when used for inferior alveolar nerve block.

## CURRENT CLINICAL EVIDENCE

Evidence-based practice backs the use of twin mix for inferior alveolar nerve blocks specifically in cases where

Address for correspondence: Dr. Darpan Bhargava, H-3/2, B.D.A Colony, Nayapura, Lalghati, Airport Road, Bhopal - 462 001, Madhya Pradesh, India. E-mail: [emaildarpan@gmail.com](mailto:emaildarpan@gmail.com)

This is an open access journal, and articles are distributed under the terms of the Creative Commons Attribution-NonCommercial-ShareAlike 4.0 License, which allows others to remix, tweak, and build upon the work non-commercially, as long as appropriate credit is given and the new creations are licensed under the identical terms.

For reprints contact: [reprints@medknow.com](mailto:reprints@medknow.com)

How to cite this article: Bhargava D, Koneru G, Deshpande A, Desai K, Dalsingh V. Proposed mechanism of action for twin mix anaesthesia when used as intra-space pterygomandibular injection for inferior alveolar nerve block with emphasis on effects of perineural injection of dexamethasone. *Adv Hum Biol* 2018;8:50-3.

Access this article online	
Quick Response Code: 	Website: <a href="http://www.aihbonline.com">www.aihbonline.com</a>
	DOI: 10.4103/AIHB.AIHB_33_17



**ORIGINAL RESEARCH PAPER**

**Prosthodontics**

**EVOLUTION OF OCCLUSAL ANALYSIS METHODS: FROM ARTICULATING PAPERS TO T-SCAN**

**KEY WORDS:** Occlusal contact marks, Occlusion indicators, T-SCAN, Occlusion recording materials.

<b>Chitra C</b>	Postgraduate student, Department of prosthodontics, Lenora institute of dental sciences, NTR University, Andhra Pradesh
<b>Rao BL*</b>	Professor & Head , Department of prosthodontics, Lenora institute of dental sciences, NTR University, Andhra Pradesh *Corresponding Author
<b>Sruthi T</b>	Postgraduate student, Department of prosthodontics, Lenora institute of dental sciences, NTR University, Andhra Pradesh
<b>Jibi J</b>	Postgraduate student, Department of prosthodontics, Lenora institute of dental sciences, NTR University, Andhra Pradesh
<b>Vathsalya G</b>	Postgraduate student, Department of prosthodontics, Lenora institute of dental sciences, NTR University, Andhra Pradesh

**ABSTRACT**

It is important not only to examine the occlusion, but to be able to record, store, and transfer the information in prosthetic dentistry. The articulation of the teeth/prosthesis with respect to simultaneous contacts, biting time and biting force should be assessed by the clinicians as required by the disciplines. However, measuring dental occlusal forces has been an inexact science, often requiring complex and subjective decisions. Dysfunctions like temporomandibular pain can be caused even if smallest high spots measuring just a few microns are present. In the fitting of prosthetic devices, occlusal indicators are widely used to obtain information on tooth contacts during occlusion. A wide range of indicators exist ranging from articulating papers through to the T-Scan pressure measurement system. These devices differ not only in their measurement characteristics but also in their material properties such as thickness and plasticity. The aim of this article is to provide an insight to various occlusal indicators available, their advantages and disadvantages in the clinical world of prosthodontics and T-SCAN in particular.

**INTRODUCTION**

Occlusal contacts are defined and located with the help of occlusal indicators. Traditional concepts of traumatic occlusal interferences involve a single anterior or posterior tooth, which is in "supracontact" during maximum intercuspation or on excursive jaw movement which are collectively called occlusal interferences. The patient will probably not bite on the new prosthesis but rather move his lower jaw into a physiologically unsound position to avoid any unpleasant sensation. The new bite of convenience causes irregular muscle activity which can eventually lead to temporomandibular joint pain and myalgia. Achieving occlusal markings on moist occlusal surfaces over some restorations such as gold, metal alloys and ceramics has been a real challenge. It is important to understand the patterns of tooth contact, properties of materials and methods used to record these tooth contacts for an accurate examination of occlusion in prosthodontic treatment.<sup>1</sup>

**Occlusion indicating materials and techniques used in the past and present**

There are various materials that have been used in the past and present to detect the occlusal contact points.<sup>1</sup>

- 1) Articulating paper
- 2) Foils
- 3) Occlusal sprays
- 4) Silicone impression material
- 5) Polyether rubber impression bites
- 6) Transparent acetate sheets
- 7) Mylar paper strip/Shim stock films
- 8) Pressure indicating paste
- 9) Modelling wax
- 10) Silk strips
- 11) Typewriter ribbon
- 12) Occlusal sonography
- 13) Photo occlusion
- 14) Pressure sensitive films
- 15) T-Scan

**Discussion**

**ARTICULATING PAPER:**

To detect high spots, articulating papers are commonly used. The width, thickness and dye type of the articulating paper enables it to leave a mark of either a point or a surface. The color coating of

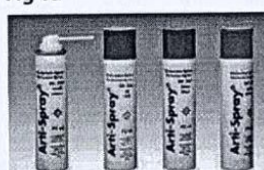
many articulating papers consists of pigments, waxes, and oils, a hydrophobic mixture which repels saliva (hydrophilic) consisting mainly of water.<sup>2</sup> High spots can be detected easily as dark marks and contacts as light marks. They are supplied in the form of strips and horse shoe shaped sheets (Bausch articulating paper Inc, Nashua, NH, USA). Only dark colored spots should be ground when grinding selectively. The major disadvantages of articulating papers have been that they can be easily ruined by saliva, are thick, and they have a relatively inflexible base material; all of these factors result in a greater number of pseudo contact markings<sup>2,3</sup>[Fig-1a]



**Fig 1a**



**Fig 1b**



**Fig 1c**



**Fig 1d**

**FOILS:**

Foils are the thinnest indicator materials which give more accurate readings than paper and silk. On glossy surfaces and under reduced pressure, their marking capacity is less evident which means that greater pressure must be applied for the clinical use of foils<sup>4</sup>[Fig-1b]

**OCCLUSAL SPRAYS:**

Occlusal sprays are universal color indicator to test occlusal contacts and are easy to administer (Anti-Spray) and leaves a thin colored film which can easily be removed with water, leaving no trace of residues. They are applied at a distance of 3-5 cm onto the

# A Novel Approach in Implant Dentistry - LIGAPLANTS

Jibi J<sup>1</sup>, Rao BL<sup>2</sup>, YSS Sruthi<sup>3</sup>, Pratyusha T<sup>4</sup>, Chitra C<sup>5</sup>

<sup>1,3,4,5</sup>Postgraduate Student, Department of Prosthodontics, Lenora Institute of Dental Sciences, NTR University, Andhra Pradesh

<sup>2</sup>Professor & Head, Department of Prosthodontics, Lenora Institute of Dental Sciences, NTR University, Andhra Pradesh

**Abstract:** *In this modern era, implants have outmatched fixed and removable partial dentures for replacing missing teeth. Implants are now in currently use because of their long term survival rate. Still, problems exist with these implants as they lack periodontal ligament. Any inflammation around these implants may cause bone loss than does the inflammation around the natural tooth with periodontal ligament. This can be solved if implants with PDL (periodontal ligament) are developed and can be achieved by Ligaplants which are nothing but a combination of PDL cells with implant biomaterial. Hence this review article aimed to discuss the benefits of periodontio-integrated implants over osseointegrated implants.*

**Keywords:** Periodontal ligament, Osseointegration, Implant, Periodontium

## 1. Introduction

Dental implants have become a popular and effective way to replace missing teeth and have changed the face of dentistry over the last 25 years.<sup>1</sup> The boom in implant dentistry is attributed to a combination of various reasons like prolonged life span of aging individuals, failures associated with removable and fixed prostheses, advantages and predictable outcomes associated with use of implants.<sup>2</sup>

The **periodontal ligament**, commonly abbreviated as the **PDL**, is a group of specialized connective tissue fibers that essentially attach a tooth to the alveolar bone within which it sits. Periodontal ligament is also known as desmodont, gomphosis, pericementum, dental-periosteum, alveolodental ligament, periodontal membrane. Apart from anchoring of tooth, PDL progenitor cells help in alveolar bone formation and remodeling.<sup>3</sup>

Implants are retained in oral cavity by virtue of osseointegration i.e direct contact between living bone and the surface of a load carrying implant at histological level.<sup>1</sup> Osseointegrated implants are the ones which are currently in use because of their long term survival rate but they too poses problems as they lack periodontal ligament. Many<sup>2</sup> strategies have been experimented to improve the<sup>3</sup> osseointegrative property of the implant for example surface modification to improve the mechanical, physical, and<sup>4</sup> chemical characteristics of the implant, modification of<sup>5</sup> shape and design of implant, alteration of surface<sup>6</sup> topography, nanostructured surface coatings or addition of<sup>7</sup> growth factors to implant surface.<sup>2,4</sup>

To overcome these problems recent scientific research developed an implant with PDL, achieved by combination of the PDL cells with implant biomaterial and named it as **LIGAPLANTS**.<sup>2</sup> There is very less literature available on Ligaplants. Keeping this in mind we reviewed the properties, procedure of obtaining ligaplants, advantages and disadvantages.

### Ligaplants

Implants with PDL are placed in the extraction socket of the missing tooth, thereby facilitating the surgical procedure.

Natural implant anchoring might also be compatible with further growth and development of the alveolar bone housing, and it may allow tooth movements during orthodontic therapy. Ligaplants have the capacity to induce the formation of the new bone, when placed in sites associated with large periodontal defects.<sup>2,3</sup> [Figure 1]

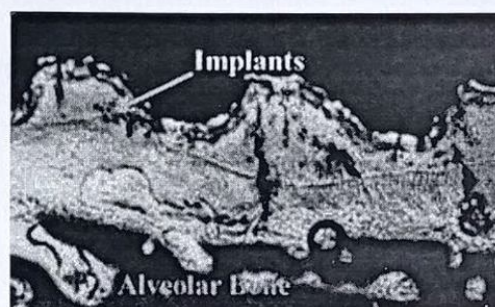


Figure 1: Ligaplants<sup>2</sup>

### Properties of ligaplants

PDL cells distributes forces, elicited during masticatory function and other contact movements to the alveolar process via the alveolar bone proper.<sup>2</sup>

It gives the tooth some movement in the socket by acting as a shock absorber.<sup>2</sup>

Proprioception is also provided by ligaplants.<sup>2</sup>

It also homes vital cells such as osteoblasts, osteoclasts, fibroblasts, cementoblasts, and most importantly undifferentiated stem cells which are osteoconductive in nature.<sup>2</sup>

### Procedure of obtaining Ligaplants

Transplantation of tooth with double PDL stimulation is one of the best examples of its healing capacity. The donor tooth is extracted and immediately replanted in its original alveolus, 14 days before transplantation. Cell proliferation and differentiation is seen as this deliberate trauma triggers a healing process within the PDL. The transplantation of the tooth can be performed with millions of cells full activity

Volume 8 Issue 3, March 2019

[www.ijsr.net](http://www.ijsr.net)

Licensed Under Creative Commons Attribution CC BY



## Total Alloplastic Temporomandibular Joint: Proposal for a Total Titanium Condylar Prosthesis with UHMWPE Joint Fossa Design (DARSN TM Joint Prosthesis)

Darpan Bhargava<sup>1\*</sup>, RS Neelakandan<sup>2</sup>, V Dal Singh<sup>3</sup> and Yogesh Sharma<sup>4</sup>

<sup>1</sup>Associate Professor, Department of Oral and Maxillofacial Surgery, Peoples College of Dental Sciences and Research Centre, People's University, Bhopal, India

<sup>2</sup>Vice-Chancellor, MAHER Professor and Head of the Department, Department of Oral and Maxillofacial Surgery, Meenakshi Ammal Dental College and Hospital, Chennai, India

<sup>3</sup>Vice-Principal and Head of the Department, Department of Oral and Maxillofacial Surgery, Lenora Institute of Dental Sciences, Rajahmundry, India

<sup>4</sup>Professor, Department of Oral and Maxillofacial Surgery Peoples Dental Academy, Bhopal, India

\*Corresponding Author: Darpan Bhargava, Associate Professor, Department of Oral and Maxillofacial Surgery, Peoples College of Dental Sciences and Research Centre, People's University, Bhopal, India.

Received: September 17, 2018; Published: September 28, 2018

### Abstract

After the reports of successful orthopaedic total joint replacement surgeries, total alloplastic temporomandibular joint (TMJ) replacement holds promise for patients with end-stage temporomandibular joint disorder, temporomandibular joint ankylosis or any other disorder/anomaly mandating joint reconstruction/replacement. Although currently available, alloplastic temporomandibular joint designs cannot simulate a natural joint completely, it manages to provide a reasonable answer to the patients' problems with evidence of improvement in the post replacement quality of life in a majority of these patients. The concern remains the affordability of such joint replacement surgeries. We propose stock total titanium condylar prosthesis with ultra-high molecular weight polyethylene (UHMWPE) joint fossa design that could provide an acceptable and affordable solution for the masses needing total alloplastic temporomandibular joint replacement in the developing countries.

Keywords: Temporomandibular Joint Ankylosis; Total Alloplastic Temporomandibular Joint; Prosthesis; TMJ

### Introduction

It is proposed by various authors that 'temporomandibular disorders related pain' has a significant psychosocial impact on patients. It affects 12% of general population with strong female predilection [1]. With the increasing evidence of success of alloplastic prosthesis in orthopaedic literature and the growing need to provide a definitive treatment for temporomandibular joint (TMJ) disorders, the various artificial temporomandibular are being investigated and some of them are in use. The possible challenges faced to replace a natural temporomandibular joint with total alloplastic temporomandibular prosthesis include:

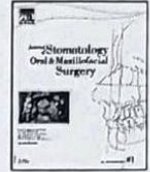1. Financial aspect involved, especially for patients in developing country like ours (India).
2. It has bilateral synovial articulation between the mandible and temporal bone which works in synchrony.
3. Ginglymoarthrodial joint - only joint in the body that has rotation and translator movements.
4. Presence of intervening disc.
5. Intervening fibrocartilaginous disc is dynamic with its movements controlled by lateral pterygoid muscle.
6. Temporomandibular joint and its function is influenced by the stomatognathic system (Occlusion, surrounding muscles) and requires harmony for its function.
7. Important joint for vital functions like speech, mastication.
8. Local surgical anatomy for surgical access to the temporomandibular joint involves vital structures like facial nerve, which require special training for open joint surgeries.
9. Acts as a growth centre and demonstrates structural changes in the joint per se with age.
10. Harmony in function between the intervening disc, osseous joint and the muscles controlling the movement.

Citation: Darpan Bhargava, et al. "Total Alloplastic Temporomandibular Joint: Proposal for a Total Titanium Condylar Prosthesis with UHMWPE Joint Fossa Design (DARSN TM Joint Prosthesis)". *Acta Scientific Orthopaedics* 1.1 (2018): 22-27.



Available online at  
**ScienceDirect**  
www.sciencedirect.com

Elsevier Masson France  
**EM|consulte**  
www.em-consulte.com/en



Original article

## Comparison of latency and efficacy of twin mix and modified twin mix in impacted mandibular third molar surgery – A Preliminary Randomized Triple Blind Split Mouth Clinical Study

S. Beena<sup>a</sup>, D. Bhargava<sup>a,\*</sup>, P. Gurjar<sup>a</sup>, S. Shrivastava<sup>a</sup>, V. Dalsingh<sup>b</sup>, G. Koneru<sup>c</sup>

<sup>a</sup> Department of Oral and Maxillofacial Surgery, People's College of Dental Sciences and Research Center, People's University, H-3/2, B.D.A Colony, Nayapura, Lal Ghati, Airport Road, 462037 Bhanpur, Bhopal, MP, India

<sup>b</sup> Head, Department of Oral and Maxillofacial Surgery, Lenora Institute of Dental Sciences, 533294 Rajahmundry, AP, India

<sup>c</sup> Sibar Institute of Dental Sciences and Research Center, Department of Oral and Maxillofacial Surgery, 522509 Vijayawada, AP, India

### ARTICLE INFO

#### Article history:

Received 30 January 2019

Accepted 12 July 2019

#### Keywords:

Local Anesthesia  
Twin Mix  
Pain  
Dexamethasone  
Lidocaine  
Third molar  
Dexamethasonized Local anesthesia

### ABSTRACT

**Introduction:** Intra-space drug administration have recently gained popularity in the clinical practice posing several advantages over the conventional routes of drug administration. A preliminary prospective randomized triple blind clinical study was conducted to compare the latency and duration of anesthesia with twin mix (1.8 ml 2% lignocaine with 1:200,000 epinephrine and 1 ml/4 mg dexamethasone) and modified twin mix (1.7 ml of 4% articaine with 1:100,000 epinephrine and 1 ml/4 mg dexamethasone) to two conventional local anesthesia solutions along with co-relation of clinical effects in the postoperative phase in patients undergoing extraction of impacted mandibular third molars in terms of patients comfort post-surgery.

**Materials and Methods:** The study was conducted among 20 patients with bilateral impacted mandibular third molars who were randomly allotted to two groups, Group A and B. Each patients in both the groups was allotted with study and control site. Among Group A, patients were further divided into Sub-group L (Control) and Sub-group TM (Twin Mix). Group B patients were divided as Sub-group A (Control) and sub-group MTM (Modified Twin Mix). Sub-group L patients received 1.8 ml of 2% lignocaine with 1:200,000 adrenaline and sub-group TM received twin mix. Sub-group A received 1.7 ml of 4% articaine with 1:100,000 adrenaline and sub-group MTM received modified twin mix solution. All the procedure was performed by a single operator with a gap of 1 month between the two interventions among both the groups. Various subjective and objective parameters were measured pre-operatively and postoperatively to assess the latency and efficacy of various anesthesia solutions used in this study for third molar removal.

**Results:** Mean ( $\pm$ SD) VAS scores for sting on injection and pain were found to be less in TM and MTM sub-group with a score of 2.3 ( $\pm$ 0.768) and 2.7 ( $\pm$ 0.065) respectively. The anesthetic latency was significantly less in sub-group TM, with a mean ( $\pm$ SD) of 52.4 ( $\pm$ 28.3) seconds. Sub-groups A and MTM had longer latency of anesthesia when compared with L and TM sub-groups. The duration of soft tissue anesthesia was maximum in sub-group MTM as compared to the other sub-groups. Patients from control sub-groups among both the groups had increased swelling, post-surgical pain and trismus postoperatively.

**Discussion:** Intra-space administration of twin mix and modified twin mix is clinically efficacious in impacted mandibular third molars surgery with better clinical outcomes postoperatively. We observed one significant difference between TM and MTM that the latter solution provided a prolonged duration of anesthesia increasing the patient's comfort postoperatively after surgical removal of mandibular third molars.

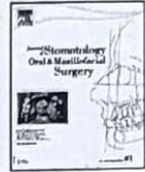
© 2019 Elsevier Masson SAS. All rights reserved.

\* Corresponding author. TMJ Consultancy Services (South East Asia), H-3/2, B.D.A Colony, Nayapura, Lal Ghati, Airport Road, 462 001 Bhopal, Madhya Pradesh, India  
E-mail address: emaildarpan@gmail.com (D. Bhargava).



Available online at  
**ScienceDirect**  
www.sciencedirect.com

Elsevier Masson France  
**EM|consulte**  
www.em-consulte.com/en



Original article

## Predictability and Feasibility of Total Alloplastic Temporomandibular Joint Reconstruction using DARSN TM Joint Prosthesis for patients in Indian subcontinent—A prospective clinical study

D. Bhargava<sup>a,\*</sup>, R.S. Neelakandan<sup>b</sup>, Y. Sharma<sup>c</sup>, V. Dalsingh<sup>d</sup>, S. Beena<sup>a</sup>, P. Gurjar<sup>a</sup>

<sup>a</sup> Department of Oral and Maxillofacial Surgery, People's College of Dental Sciences and Research Center, People's University, 462037 Bhanpur, Bhopal, Madhya Pradesh, India

<sup>b</sup> MAHER, Department of Oral and Maxillofacial Surgery, Meenakshi Ammal Dental College and Hospital, Chennai, Tamil Nadu, India

<sup>c</sup> Department of Oral and Maxillofacial Surgery, People's Dental Academy, People's University, 462037 Bhanpur, Bhopal, Madhya Pradesh, India

<sup>d</sup> Department of Oral and Maxillofacial Surgery, Lenora Institute of Dental Sciences, Rajahmundry, Andhra Pradesh, India

### ARTICLE INFO

#### Article history:

Received 9 April 2019

Accepted 18 June 2019

#### Keywords:

Temporomandibular joint disorder

Ankylosis

Arthroplasty

Prosthesis and Implants

Quality of life

Joint replacement

### ABSTRACT

**Purpose:** The aim of this study was to investigate the feasibility of a custom made alloplastic Temporomandibular Joint (TMJ) device design in patients undergoing temporomandibular (TM) Total Joint Reconstruction (TJR).

**Objective:** TMJ disease with functional and anatomic distortion dictates the need for TJR. There are various materials to reconstruct a TMJ. However, various factors, such as cost, availability of prosthetic joint, limit its use to tertiary health care center. Hence, we have investigated the feasibility and efficacy of the custom made alloplastic TMJ prosthesis (DARSN TM Joint Prosthesis) with the advantage of being acceptable financially and the overall Quality of life (QoL) diagnosed with TMJ ankylosis and End Stage Joint Disease (ESJD) selected from the study population.

**Materials and methods:** The study group comprised of 20 patients with TMJ ankylosis or End Stage Joint Disease (ESJD) who needed TM TJR of which few subjects in the study population had history of failed previous surgery to the TMJ region. The patients underwent resection of the joint followed by TJR using the custom made alloplastic TMJ prosthesis. Various subjective and objective variables were evaluated such as the Jaw Function (JF), Inter-incisal opening (IO), Diet intake (DI), Quality of Life (QoL) using a Psychometric Modified Likert Scale and nutritional status of the patient using the Mid-Upper Arm Circumference (MUAC) as reference.

**Results:** All the subjective and objective variables showed significant improvement in the postoperative period as compared to the preoperative period. The JF score increased with a mean score of 6.25 ( $P < 0.00001$ ). Postoperative mean DI score was 3.15 ( $P < 0.00001$ ) and IO increased up to 29–38 mm in 95% of the study population. The study population exhibited an improved overall QoL and nutritional status post-operatively. Follow up period of 1 year showed significant functional improvement among the study population.

**Conclusion:** The results shows that the custom made alloplastic joint replacement is safe and effective and reliable alternative to treat patients with TMJ disease which restricts the normal function to a greater degree requiring TM TJR.

© 2019 Elsevier Masson SAS. All rights reserved.

### 1. Introduction

Alloplastic total temporomandibular joint (TMJ) reconstruction restores function and form of the TMJ and it is indicated in patients diagnosed with wide range of joint pathologies such as

ankylosis, neoplasia that may require extensive resection of the TMJ, failed autogenous graft, and mutilative joint disease among the few. Temporomandibular disorders related pain has a significant psychosocial impact on patients with strong female predilection. [1] With the increasing evidence of success of alloplastic prosthesis in orthopedic literature and the growing need to provide a definitive treatment for TMJ disorders, the various artificial TMJs are being investigated and some of them are in use.

\* Corresponding author. Private Practise, H-3/2, BDA Colony, Nayapura, Lal Ghati, Airport Road, Bhopal, 462001, Madhya Pradesh, India  
E-mail address: emaildarpan@gmail.com (D. Bhargava).



# An In-vitro Comparison of the Shear Bond Strength of Three Different Composite Materials with Three Different Etchants for the Bonding of Orthodontic Brackets

Sharat Megh<sup>1</sup>, VV Rao<sup>1</sup>, MS Minor Babu<sup>1</sup>, Punithavathy R.<sup>2</sup>, Martha Satyam<sup>1</sup>, Akhil Pallepati<sup>3</sup>, Raparla Mythraiye<sup>1</sup>, Chandrika Paravada<sup>1</sup>

1. Pedodontics and Preventive Dentistry, Lenora Institute of Dental Sciences, Rajahmundry, IND 2. Pedodontics and Preventive Dentistry, Lenora Institute of Dental Sciences, Rajahmundry, IND 3. Public Health Dentistry, Lenora Institute of Dental Sciences, Rajahmundry, IND

✉ **Corresponding author:** Sharat Megh, dr.sharat.pedo@gmail.com

Disclosures can be found in Additional Information at the end of the article

---

## Abstract

### Introduction

Esthetics, being the major concern of today's treatments, has led to numerous innovations, including composites, for different treatment options. Esthetic orthodontics requires the use of composites for bonding orthodontic brackets to the teeth.

### Aims

To identify which combination of composites has the highest shear bond strength at the tooth-bracket interface.

### Materials and methods

Three different composite kits were selected for each group (n=42) and were further divided into three subgroups (n=14), where the bonding agents and/or primer were interchanged to find the best combination.

### Results

Sub-group B2 (Orthofix + Eazetch + Universal Bond) showed the highest shear bond strength (10.74 ± 3.45 MPa), which was highly significant at  $p = /<0.0001$ .

### Conclusion

The highest shear bond strength was found with the combination of 37% phosphoric acid (Eazetch), GC Universal Bond (GC Corporation, Tokyo, Japan), and Orthofix composite material (Anabond Stedman, Chennai, India). As this study is an in-vitro study, we need longitudinal in-vivo studies to establish the best combination for the bonding of orthodontic brackets.

---

**Categories:** Miscellaneous, Other

**Keywords:** shear bond strength, orthodontic brackets, composites, etchants

### How to cite this article

Megh S, Rao V, Minor Babu M, et al. (June 19, 2019) An In-vitro Comparison of the Shear Bond Strength of Three Different Composite Materials with Three Different Etchants for the Bonding of Orthodontic Brackets. *Cureus* 11(6): e4944. DOI 10.7759/cureus.4944

Received 04/22/2019


Review began 04/29/2019

Review ended 06/13/2019

Published 06/19/2019

© Copyright 2019

Megh et al. This is an open access article distributed under the terms of the Creative Commons Attribution License CC-BY 3.0., which permits unrestricted use, distribution, and reproduction in any medium, provided the original author and source are credited.



KNOWLEDGE, ATTITUDE AND PRACTICES OF SCHOOL TEACHERS TOWARDS ORAL HEALTH IN MANIPUR, INDIA

Dental Science

<b>Thokchom Ushakiran*</b>	Post Graduate Student Lenora Institute Of Dental Sciences Department of Public Health Dentistry, Lenora Institute of Dental Sciences, NH- 16, Rajanagaram, Andhra Pradesh - 533294* Corresponding Author
<b>Naveen Kumar Bopanna</b>	MDS Professor and Head of Department of Public Health Dentistry Lenora Institute of Dental Sciences Department of Public Health Dentistry, Lenora Institute of Dental Sciences, NH- 16, Rajanagaram, Andhra Pradesh - 533294
<b>Narayana Rao Vinnakota</b>	MDS Reader Department of Public Health Dentistry Lenora Institute of Dental Sciences Department of Public Health Dentistry, Lenora Institute of Dental Sciences, NH- 16, Rajanagaram, Andhra Pradesh - 533294
<b>Burri Kiran Karthik</b>	Post Graduate Student Lenora Institute of Dental Sciences Department of Public Health Dentistry, Lenora Institute of Dental Sciences, NH- 16, Rajanagaram, Andhra Pradesh - 533294
<b>Anvesh. G</b>	Post Graduate Student. Lenora Institute Of Dental Sciences Department of Public Health Dentistry, Lenora Institute of Dental Sciences, NH- 16, Rajanagaram, Andhra Pradesh - 533294
<b>Akhil Pallepati</b>	MDS Senior Lecturer Lenora Institute of Dental Sciences Department of Public Health Dentistry, Lenora Institute of Dental Sciences, NH- 16, Rajanagaram, Andhra Pradesh - 533294

ABSTRACT

**Introduction:** Schools provide an effective platform for promoting oral health as they reach over 1 billion children worldwide. Education of school children on oral health is most important because healthy oral habits are developed early in life. The teachers, by virtue of being trained persons and because of their proximity to the children have a determining role in disseminating knowledge on oral health. **Aims:** To assess Knowledge, Attitude and Practices regarding oral health among school teachers in Manipur. **Materials and Method:** A total of 143 school teachers working in 3 government and 3 private schools were included in this study. A pre-tested questionnaire having 31 questions pertaining to Knowledge, Attitude, Practices along with demographic details were distributed to the teachers and then collected after 30mins. The data was analyzed using the Statistical Package for Social Science version 22.0. Chi square test was done in order to test for group difference among the variables. **Results:** The participants' oral hygiene habits were found to be regular and also showed good knowledge on oral health along with recognizing its importance. They did incorporate the importance of oral health in educating children. But, not all teachers are involved effectively. **Conclusion:** Therefore, the teachers should be trained comprehensively regarding importance of oral health and creating awareness on oral health promotion for their students in combination with health care personnel.

KEYWORDS

oral health, knowledge, attitude, practices, school teachers

INTRODUCTION

Despite great achievements in oral health globally, problems still remain in many communities all over the world, particularly among under-privileged groups in developed and developing countries.<sup>1</sup> The significant role of socio-behavioral and environmental factors in oral disease and health is evidenced in an extensive number of epidemiological surveys.<sup>2</sup>

In India, The National Oral Health Survey was able to cover 19 states and union territories and the details were listed separately in their report. It was originally planned to cover all states and union territories in India.<sup>3</sup> However, this could not be achieved as some of the state authorities, such as North Eastern States, had expressed their inability to participate due to lack of dental colleges in their states, manpower and other resources and Manipur is one such state.<sup>3</sup>

Due to scarcity of oral health status information,<sup>4</sup> oral health programmes in the state has not been implemented on a large scale. There is a demanding need for planning and evaluating oral health promotional programs. Moreover, there is paucity of literature regarding data of oral health awareness, attitude and knowledge among the people in Manipur. Due to this lacuna, there is an increasing need to assess the status of oral health.

As a preliminary level, assessing the knowledge, attitude and practice on oral health is mandatory to plan for promoting oral health programs in the state. As, children are one of the most vulnerable victims of oral diseases, programs aimed at improving the school dental health are of

great importance for promoting oral health of the community.<sup>5</sup> This could be achieved through oral health education. School teachers can play a foremost task in imparting knowledge of the causes and prevention of common oral diseases.<sup>6</sup> But this could be achieved only when the teachers have a concrete knowledge, a good attitude and practice on oral health. Teachers are considered as role models to transmit values of life. Children can be reached at a time when their health habits are forming including those who may not have access to other sources of health information.<sup>7</sup> Thus, this study was conducted with an aim to assess the knowledge, attitude and practice of oral health among school teachers in rural and urban areas of Manipur.

MATERIALS AND METHODS:

A cross sectional study was conducted among 3 government and 3 private school teachers in Manipur. A sample size of 143 school teachers were randomly selected from government and private schools in Manipur after taking consent from the respected school head master / principal and from the individuals. This study was approved by the Institutional Review Board and Ethical Committee of Lenora Institute Of Dental Sciences, Rajanagaram. A cluster of six schools were selected. Only those teachers who gave the consent were included in the study. There were 44 government and 99 private school teachers who were included in the study.

A pre-tested questionnaire consisting of 31 closed ended questionnaire were distributed among the school teachers wherein a brief explanation about the questionnaire were given. The participants were informed about the importance of answering honestly. The



## ASSESSMENT OF ATTITUDE AND IMPLEMENTATION OF ECO-FRIENDLY DENTAL OFFICE STRATEGIES AMONG DENTAL PRACTITIONERS IN A CITY PRACTICE AREA OF SOUTH INDIAN STATE

### Dental Science

<b>Praneetha Kallakuri*</b>	Public Health Dentistry, Lenora Institute of Dental Sciences. *Corresponding Author
<b>Boppana Naveen Kumar</b>	Public Health Dentistry, Lenora Institute of Dental Sciences.
<b>Vinnakota Narayana Rao</b>	Public Health Dentistry, Lenora Institute of Dental Sciences.
<b>Yeluripati Sai Nirupama</b>	Public Health Dentistry, Lenora Institute of Dental Sciences.
<b>Avinash Velamala</b>	Public Health Dentistry, Lenora Institute of Dental Sciences.
<b>Th. Ushakiran</b>	Public Health Dentistry, Lenora Institute of Dental Sciences.

### ABSTRACT

**Aim:** To assess the attitude and implementation of eco-friendly dental office strategies among dental practitioners in Rajahmundry city.

**Methodology:** A cross-sectional study was conducted over a period of 2 months from September to November 2017 among registered dental practitioners of Rajahmundry city. A pre tested, pre designed questionnaire was used and collected after one day so that sufficient time will be provided for practitioners to answer it.

**Results:** 90% of practitioners agreed that green practices can play a role in environment and 80% practitioners agreed that green practices has many long term benefits of which both were found to be statistically significant. 63.3% of practitioners found that green dentistry can be compatible with previous standard and new features to be influential.

**Conclusion:** Current study suggests that implementation strategies of eco-friendly dental practices among the dental practitioners of Rajahmundry is not adequate.

### KEYWORDS

green dentistry, eco-friendly practices, dental practitioners

### INTRODUCTION:

The modern global issue is the preservation of the environment<sup>1</sup>. Global warming owing to environmental pollution is disturbing the balance of nature and inflicting chaos everywhere around the globe. Human health is extremely affected by the significant adverse effects of climate change<sup>2</sup>. As stated by World Health Organization a total of about 35,000 tons of healthcare waste annually and about 1000 tons daily is produced by SEARO, the 11 South Asian countries<sup>3</sup>. The dentist uses a wide range of materials and instruments to enhance dental health and overall wellbeing. Dental health care is devoted to endorse and enhance oral health and well-being and to achieve such goals, dentists use a diversity of materials and instruments. Unfortunately, particular materials that are currently in use include heavy metals as well as biomedical waste, offer impending challenges to the ecological stability<sup>4</sup>. It is the duty of the dental professionals to safeguard the natural resources and to decrease the influence of lethal waste generated from the practices of nature<sup>1</sup>. "Eco-Dentistry or Green Dentistry" has been recognized which has taken dentistry beyond the point of preventing pollution to a place of promoting sustainability<sup>4</sup>. The eco-dentistry association (EDA), and educational and membership association had developed a model for green dental professionals.

Green Dentistry is defined as a high-tech approach that reduces the environmental impact of dental practices and encompasses a service model for dentistry that supports and maintains wellness by the Eco-Dentistry Association (EDA)<sup>5</sup>. The key concepts of eco dentistry include the strategic ideas of eco-dentistry include water and energy, reduction of waste, practice of non-toxic products, reducing waste and eliminating lethal toxins<sup>6</sup>. To determine the financial advantages of eco-friendly dentistry an extended investigation has to be done<sup>7</sup>. It is the time for the dentist's to become environmentally conscious and to create their dental practices eco-friendly and there is scarcity in the literature the present study was conducted with the aim to assess the attitude and implementation of eco-friendly dental office strategies among dental practitioners in Rajahmundry city.

### MATERIALS AND METHODS:

A cross-sectional study was conducted over a period of 2 months from September to November 2017 among registered dental practitioners of Rajahmundry city. Prior ethical clearance was obtained from the Institutional Ethical Committee (IEC) in full accordance with the World Medical Association Declaration of Helsinki. Only private practitioners were considered for this study as public sector dentists does not have the choice for eco-friendly policies and procedures. List of private dental practitioners was obtained from the District Medical and Health Office (DMHO), East Godavari district and before starting the study, informed written consent was obtained from the participants. A pre tested, pre designed questionnaire was used. It consists of two sessions: Demographic data and questions regarding attitude, and implementation. The questionnaire was distributed and collected after one day so that sufficient time will be provided for practitioners to answer it. A pilot study was done to determine the feasibility of the survey. From the lists obtained, a total of 150 private dental practitioners were approached to participate in the survey. Participants who were not willing to participate in the study or who were absent during three consecutive visits were excluded from the study. The final sample consisted of 120 dentists.

### Statistical Analysis:

Data was entered into the Microsoft Word Excel Sheet 2010 version and was analyzed using the Statistical Package for the Social Sciences version 23.0 software (SPSS Inc., Chicago, IL, USA). Descriptive analysis for demographic variables, knowledge, attitude and implementation of eco-friendly dental office strategies were computed. Further, chi-square test was applied.  $P \leq 0.05$  was considered statistically significant.

### RESULTS:

**Table 1 shows the distribution of study participants according to qualification and gender:**

It was observed that maximum of the study participants were males [n=102 (85%)]. Majority of the study subjects were Master of Dental Surgery qualified (MDS) [n=64 (91.4%)].

## Pulp Stones as Risk Predictors for Coronary Artery Disease

## Abstract

**Background:** Coronary artery disease (CAD) has been the leading cause of morbidity and mortality worldwide. Studies indicate that patients with CAD show higher degree of pulp calcifications. Localized pulp calcifications are microscopically apparent in more than half of the teeth in young adolescents. However, pulp stones extending to the entire dentition are infrequent and need further evaluation to predict the risk of other probabilities of associated diseases. The present study was planned to estimate the prevalence of pulp stones in patients diagnosed with or, undergoing treatment for CAD. **Methods:** The present study consisted of 300 subjects within an age range of 20-55 years who were divided into the study group consisting of 150 patients including 108 males and 42 females as well as 150 age- and sex-matched healthy controls. Pulp stones were imaged using bitewing radiographs using paralleling technique under standard conditions. **Statistical Analysis Used:** The statistical analysis was performed using IBM SPSS statistics 20 Core system software (SPSS Inc., Chicago, IL, USA) while Chi-square test was used to check the prevalence of pulp stones in patients with CAD in addition to their arch-wise and region-wise distribution. *P* value <0.05 was considered statistically significant. **Results:** The present study revealed 100% prevalence of pulp stones in the study group while 90% of the subjects in the control group were also afflicted with pulp stones, though the total number of pulp calcifications observed were lesser in number in the control group compared to the study group (*P* < 0.05). No significant difference was found, although in the gender predilection for the development of pulp stones in the study group while the control group revealed a definite male predilection with around 96.24% of the males afflicted with pulp stones (*P* < 0.05). Furthermore, maxillary teeth had a statistically significant predilection for the development of pulp stones in both the study as well as the control groups (*P* < 0.05). **Conclusions:** The patients with CAD have high chance of being affected with pulp stones. Higher prevalence of this entity in multiple teeth may warrant such an individual, in the presence of other compounding risk factors, as a candidate for CAD to be ruled out.

**Keywords:** Coronary artery disease, pulp stones, risk predictors

## Introduction

Coronary artery disease (CAD) is caused by atherosclerosis of the coronary arteries leading to a reduction in blood flow to the heart. It is one of the leading causes of death worldwide.<sup>[1,2]</sup> Ischemic heart diseases (IHDs) which ranked fifth as the cause of mortality in 1990 has been proposed as they would be leading cause of mortality in 2020. This shows the significance this set of diseases carries demanding a comprehensive revision of the preventive and treatment programs to put a check on the leading cause of morbidity in the future.<sup>[3]</sup> Zachariah *et al.*<sup>[2]</sup> reported that 11% of population in urban India and 7% in rural parts are afflicted by this disease.

Pulp stones or, denticles are nodular, calcified masses appearing within the pulp of the healthy, diseased and even the unerupted teeth.<sup>[4]</sup> Various theories regarding the etiological factors behind the occurrence of pulp stones have been put forth including age, genetic susceptibility, pulpal degeneration, circulatory derangements in the pulp, inductive interaction between the pulpal tissue and the epithelium and orthodontic tooth movements apart from a plethora of other factors and the unidentified, idiopathic ones.<sup>[5]</sup>

Osteopontin, a new constituent of atherosclerotic plaque, apparently plays a role in plaque calcification. Just as osteopontin produced by macrophages plays the chief role in the production of calcification centers within the necrotic

Suresh Babu J.,  
Swarnalatha C.,  
Amit Rao P.<sup>1</sup>,  
Barun Kumar B.<sup>2</sup>,  
Balagangadhar  
Tilak P.<sup>1</sup>,  
Ramesh Naidu B.<sup>3</sup>,  
Abhishek Singh  
Nayyar<sup>4</sup>

Department of Preventive  
Dental Sciences, Division  
of Periodontology, College  
of Dentistry, University of  
Ha'il, Ha'il, Kingdom of  
Saudi Arabia, <sup>1</sup>Department  
of Oral and Maxillofacial  
Surgery, Dr.Hedgewar  
Smruti Rugna Seva Mandal's  
Dental College and Hospital,  
Hingoli, Maharashtra, India,  
<sup>2</sup>Department of Oral Medicine  
and Radiology, Saraswati  
Dhanwantari Dental College  
and Hospital and Post-  
graduate Research Institute,  
Parbhani, Maharashtra, India,  
<sup>3</sup>Department of Oral and  
Maxillofacial Surgery, Bharati  
Vidyapeeth (Deemed to be  
University) Dental College and  
Hospital, Sangli, Maharashtra,  
India, <sup>4</sup>Department of Oral and  
Maxillofacial Surgery, Sri Sai  
Dental College, Srikakulam,  
Andhra Pradesh, India

## Address for correspondence:

Dr. Suresh Babu J.,  
Department of Preventive  
Dental Sciences, Division of  
Periodontology, College of  
Dentistry, University of Ha'il,  
Ha'il, Kingdom of Saudi Arabia.  
E-mail: sureshbabuj@gmail.com

## Access this article online

Website:  
[www.ijpvmjournal.net/www.ijpvm.net](http://www.ijpvmjournal.net/www.ijpvm.net)  
DOI:  
10.4103/ijpvm.IJPVM\_68\_19

## Quick Response Code:



How to cite this article: Babu SJ, Swarnalatha C, Rao AP, Kumar BB, Tilak BP, Naidu RB, *et al.* Pulp stones as risk predictors for coronary artery disease. *Int J Prev Med* 2020;11:7.

This is an open access journal, and articles are distributed under the terms of the Creative Commons Attribution-NonCommercial-ShareAlike 4.0 License, which allows others to remix, tweak, and build upon the work non-commercially, as long as appropriate credit is given and the new creations are licensed under the identical terms.

For reprints contact: reprints@medknow.com



## ORIGINAL RESEARCH PAPER

Prosthodontics

## INFUNDIBULAR DENTURE FOR HIGHLY RESORBED RIDGE – A CASE REPORT

**KEY WORDS:** Resorbed ridge management, Cocktail impression, Neutral zone, Hollow denture.

<b>Pratyusha</b>	PG Students Department of Prosthodontics, Lenora Institute of Dental Sciences, Rajanagaram, Rajamahendravaram, Andhra Pradesh, India.
<b>Rao BI*</b>	Professor and HOD Department of Prosthodontics, Lenora Institute of Dental Sciences, Rajanagaram, Rajamahendravaram, Andhra Pradesh, India. *Corresponding Author
<b>Sirisha G</b>	Senior Lecturer, Lenora Institute of Dental Sciences, Rajanagaram, Rajamahendravaram, Andhra Pradesh, India.
<b>Pallavi C</b>	PG Students, Lenora Institute of Dental Sciences, Rajanagaram, Rajamahendravaram, Andhra Pradesh, India.
<b>Sruthi T</b>	PG Students, Lenora Institute of Dental Sciences, Rajanagaram, Rajamahendravaram, Andhra Pradesh, India.

## ABSTRACT

The success of a complete denture relies on the principles of retention, stability and support. The prosthodontist skill lies in applying these principles efficiently in critical situations. Severely resorbed mandibular edentulous ridges that are narrow and constricted with increased inter ridge space provide decreased support, retention and stability. The consequent weight of the processed denture compromises them further. This article describes a case report of an edentulous patient with resorbed ridges where a simplified technique of fabricating a hollow mandibular complete denture using wax was used for preservation of denture bearing areas. The hollowing of the denture reduces the weight of the denture, thereby enhancing stability and retention, reducing the further resorption of the jaws.

## INTRODUCTION:

Prosthetic rehabilitation of severely resorbed ridges has been a major problem in dentistry since ages. The resorbed or atrophied ridges pose a clinical challenge to the clinician to fabricate a successful prosthesis with optimal retention, stability and support. The success of a complete denture relies on the principles of retention, stability and support. The prosthodontist skill lies in applying these principles efficiently in critical situations [1]. Although the resorption process is generally a more serious clinical problem in the mandibular arch, significant loss of alveolar bone in the maxillae can prove equally problematic [2]. After dental extractions, the residual alveolar bone undergoes a period of accelerated resorption for about 10 weeks, followed by a slower, but progressive resorption [3]. Residual ridge resorption is a complex biophysical process affected by various anatomic, prosthetic, functional, and metabolic factors. The various problems posed by resorbed ridges are narrower, more constricted ridge as resorption progresses, decreased denture bearing area and in turn effecting retention, stability and support of the final denture. Apart from effecting these major requirements, excessive ridge resorption also results in a large restorative space between the residual ridges [4]. Restoration of lost vertical dimension results in fabrication of a heavy complete denture that may compound the poor denture bearing ability of the tissues and lead to decreased retention and resistance [5].

To increase the retention and stability of such a heavy prosthesis, various methods like use of undercuts, modifications in impression techniques [6], use of magnets [7], use of implants [8], use of intramucosal inserts [9,10] incorporation of suction disks [10] and fabrication of lightweight dentures [2,4,11,12] have been tried. Numerous methods and materials have been used to fabricate a lightweight denture, allowing for restoration of esthetics and function such as mastication, deglutition, and speech. Weight reduction approaches have been achieved using a solid 3D spacer, including dental stone, cellophane-wrapped asbestos [13] silicone putty [4,14] modeling clay, and thermocol [15], lost salt technique [16] during laboratory processing to exclude denture base material from the planned hollow cavity of the prosthesis. Alternately, fabrication of multiple and separate pieces of the prosthesis either individually or around a 3D spacer has also been described [1,4]

The present article is a case report of an edentulous female patient with severely resorbed mandibular ridge and increased inter-ridge space who has undergone resorbed ridge management since impression making for the fabrication of an optimal prosthesis.

## CASE REPORT:

A 60 year old female patient (Fig:1A) walked into the Department of Prosthodontics, Lenora Institute of Dental Sciences with a chief complaint of looseness of both upper and lower dentures and desired the replacement of the same. Her history revealed that, she had been edentulous and had been wearing dentures for 25 years.

On examination, it was found that the maxillary edentulous ridge is well formed (Fig:1B) and the mandibular edentulous ridge is severely resorbed (Fig:1C). Patient's medical and dental histories were carefully evaluated, intraoral and extraoral examination was carefully made. After radiographic evaluation and based on patient's clinical conditions, various treatment options have been explained to the patient. The various treatments discussed with the patient were Conventional Complete dentures and Complete dentures with resorbed ridge management. The patient opted for the complete dentures with resorbed ridge management as she was explained that it would be more stable compared to conventional complete dentures.

As the mandibular ridge is severely resorbed, rather than conventional secondary impression with zoe paste, an impression is made in Cocktail impression technique. As a consequence of resorption, it had also been noticed an increased inter ridge space for which a hollow denture was planned for either of the arches or both based on the vertical height of the occlusal rim. To aid in more stability to the mandibular prosthesis, teeth arrangement in the neutral zone is planned.

## TECHNIQUE:

1. A conventional primary impression of both the arches is made with impression compound (DPI).
2. Maxillary secondary impression is made in the standard technique with green stick border molding and zinc oxide eugenol paste impression. Mandibular ridge being severely atrophied had been recorded in Cocktail impression

## Finite element analysis of stress concentration between surface coated implants and non surface coated implants - An *in vitro* study

Tammineedi SV. Satyanarayana <sup>1</sup>, Rathika Rai <sup>2</sup>, E. Subramanyam <sup>3</sup>, T. Illango <sup>4</sup>, Vishwabharathi Mutyala <sup>5</sup>, Rajesh Akula <sup>6</sup>

<sup>1</sup> MDS (Prosthodontics), Reader, Lenora institute of dental sciences, Rajahmundry-533103

<sup>2</sup> MDS (Prosthodontics), Principal, HOD Dept of prosthodontics, Thaimoogam bigai Dental college, Chennai

<sup>3</sup> MDS (Prosthodontics), Ex HOD Dept of prosthodontics, Thaimoogam bigai Dental college, Chennai

<sup>4</sup> MDS (Prosthodontics), Ex Prof. Dept of prosthodontics, Thaimoogam bigai Dental college, Chennai

<sup>5</sup> SBS Ayurvedic Medical College, Mundurgi

<sup>6</sup> MDS (Prosthodontics), Dental officer, Ex-servicemen Contributory Health Scheme, Srikakulam

### Correspondence:

Lenora institute of dental sciences, Rajahmundry  
satya0112t@gmail.com

Received: 23/05/2019  
Accepted: 26/06/2019

Satyanarayana TSV, Rai R, Subramanyam E, Illango T, Mutyala V, Akula R. Finite element analysis of stress concentration between surface coated implants and non surface coated implants - An *in vitro* study. J Clin Exp Dent. 2019;11(8):e713-20.  
http://www.medicinaoral.com/odo/volumenes/v11i8/jcedv11i8p713.pdf

Article Number: 55915 <http://www.medicinaoral.com/odo/indice.htm>  
© Medicina Oral S. L. C.I.F. B 96689336 - eISSN: 1989-5488  
eMail: [jced@jced.es](mailto:jced@jced.es)  
Indexed in:  
PubMed  
PubMed Central® (PMC)  
Scopus  
DOI® System

### Abstract

**Background:** To determine qualitative comparison in stress distribution between surface coated implants and non surface coated implants using 2 different lengths and vertical, oblique, and lateral forces.

**Material and Methods:** 3 dimensional finite element study was carried out at first molar site with 4 surface coated and 4 non surface coated implants using mimic 8.11, solid edge 2004, hypermesh 9.0, and ansys12.1 software.

**Results:** The pattern of stress distribution was almost similar between vertical and oblique loading but varied with lateral loads between surface coated and non surface coated implants. As the length of the implants increased stress concentration had no significant variation between surface coated and non surface coated implants, but had a tendency to increase at the abutment and abutment screw on all 3 forces.

**Conclusions:** Among the surface coated and non surface implants the pattern of stress distribution was similar signifying that surface coating of implants had no significant role in stress distribution using 3d finite element analysis and within the limitations of this study.

**Key words:** Surface coating, non surface coating, implants, stress and bone.

### Introduction

Significant progress has been made in the clinical use of oral and maxillofacial implants over the past three decades. Statistics on the use of dental implants reveals about 100,000 to 300,00 dental implants are placed per year

as the aging population increases larger number of individuals are being defined as partially edentulous, using dental implants as a recent standard care (1).

Biomechanical optimization is an important objective in the design of dental implants. Although the success

## Role of Immunological Alterations in Oral Submucous Fibrosis

Sarada Malempati, Vamshi Krishna Guttikonda<sup>1</sup>, Thejasri Vishnubhatla<sup>1</sup>, Mahesh Neerupakam<sup>1</sup>, Sridevi Koduri<sup>1</sup>, Krishnaveni Buduru<sup>1</sup>

Department of Oral Medicine and Radiology, GSL Dental College, <sup>1</sup>Department of Oral Medicine and Radiology, Lenora Institute of Dental Sciences, Rajahmundry, Andhra Pradesh, India

### Abstract

**Background:** Oral Submucous fibrosis (OSMF) is a premalignant condition affecting the oral mucosa. It is observed to have a multifactorial etiology including genetic predisposition and autoimmune origin. This study aimed to study the etiological role of immunological factors in OSMF. **Settings and Design:** It was a prospective study carried out in the Department of Oral Medicine and Radiology at Lenora Institute of Dental Sciences, Rajahmundry. **Aims and Objective:** To estimate and compare the serum IgG and IgA between the OSMF subjects and controls. To assess the statistical significance of the difference in the levels of albumin, globulin, total protein, IgG and IgA between study group and control group if any. **Materials and Methods:** It was an observational study in which the serum albumin, serum globulin, total protein, IgG and IgA were evaluated in a total of 60 patients who gave consent to participate in the study. **Results and Discussion:** Increase of IgG was observed in 9 (30%) subjects of the OSMF group and in 4 (13.2%) of the control group. IgA level was increased in 2 (6.6%) subjects of OSMF group and in 5 (16.6%) subjects of the control group. However, this difference was not statistically significant. **Conclusion:** The findings from the study indicated an alteration in the immunoglobulin level in patients with OSMF. However, the association was not significant. Therefore, further and larger studies are advocated to verify the immunological association with OSMF. One important observation made in the study was a positive association between the duration of exposure and stage of OSMF. This implies that interventions which modify the arecanut chewing habits can bring about a reduction in OSMF and in turn oral cancer.

**Keywords:** Arecanut, IgA, IgG, immunoglobulin, oral submucous fibrosis

### INTRODUCTION

Oral Submucous fibrosis (OSMF) is a premalignant condition that affects the oral mucosa and is linked to arecanut (betel nut) chewing. It is predominantly seen in Southeast Asians but off late is found among Europeans and North Americans. It can cause morbidity status post-transformation into squamous cell carcinoma (SCC).<sup>[1]</sup> OSMF has been described as early as 2500–3000 B.C. by Sushruta in his ancient book as “vidari” a condition which resembles OSMF.<sup>[2]</sup> Schwartz in 1952 described it as atrophic idiopathic mucosa oris. It was given the term oral submucous fibrosis by Joshi in 1953.<sup>[3]</sup>

OSMF initially starts as oral mucosal stiffness that may lead to trismus and difficulty while eating.<sup>[4]</sup> Clinically it might present as difficulty in mouth opening, tongue protrusion, difficulty in phonetics, and deglutition.<sup>[5]</sup>

Consumption of arecanut is believed to be one of the important causes of OSMF. However, the exact etiology is still obscure. Intake of other irritants such as capsaicin in chillies, vitamin

deficiency, and streptococcal infection are also believed to play a role in OSMF.<sup>[6]</sup> OSMF was found to show changes similar to that seen in collagen disorders such as rheumatoid arthritis and scleroderma, etc.,. This was further supported by the fact that alkaloids and tannins present in arecanut have the potential to increase the collagen activity. However, the one draw-back of this theory is that the presence of lupus erythematosus (LE) cells has not been shown in OSMF.<sup>[6]</sup>

The pathological changes in OSMF are, an initial juxtaepithelial inflammatory reaction followed by fibroelastic changes in the submucosa and epithelial atrophy manifesting as the stiffness of the oral mucosa and trismus.<sup>[7]</sup>


Address for correspondence: Dr. Sarada Malempati,  
Department of Oral Medicine and Radiology, GSL Dental College,  
Rajahmundry - 533 294, Andhra Pradesh, India.  
E-mail: saradadent@gmail.com

This is an open access journal, and articles are distributed under the terms of the Creative Commons Attribution-NonCommercial-ShareAlike 4.0 License, which allows others to remix, tweak, and build upon the work non-commercially, as long as appropriate credit is given and the new creations are licensed under the identical terms.

For reprints contact: [reprints@medknow.com](mailto:reprints@medknow.com)

How to cite this article: Malempati S, Guttikonda VK, Vishnubhatla T, Neerupakam M, Koduri S, Buduru K. Role of immunological alterations in oral submucous fibrosis. *J Indian Acad Oral Med Radiol* 2019;31:24-8.

Received: 27-10-2018 Accepted: 28-02-2019 Published: 23-04-2019

Access this article online	
Quick Response Code: 	Website: <a href="http://www.jiaomr.in">www.jiaomr.in</a>
	DOI: 10.4103/jiaomr.jiaomr_181_18

# Assessment of Musculoskeletal Disorders and Associated Risk Factors among Dentists in Rajahmundry City: A Cross-Sectional Study

Anvesh Gandham, Naveen Kumar Boppana, Narayana Rao Vinnakota, Kiran Karthik Burri, Usha Kiran Th, Akhil Pallepalli  
Department of Public Health Dentistry, Lenora Institute of Dental Sciences, Rajahmundry, Andhra Pradesh, India

## Abstract

**Background:** Like any other profession, dentistry is also plagued by many occupational health hazards (OHHs). Musculoskeletal disorders (MSDs) are one of the most common OHHs witnessed among dental practitioners. **Aim:** This study aimed to assess the prevalence and associated risk factors for MSDs among dental practitioners. **Material and Methods:** A prevalidated questionnaire was distributed among 150 dentists practicing in Rajahmundry city. The questionnaire was designed to procure information on demographic details and associated risk factors of MSDs experienced by them in the last 6 months. Chi-square test and multivariate regression analysis were employed to find significance among the study parameters and associated risk factors. Statistical analysis was performed using SPSS software (version 23.0, IBM, Chicago, IL, USA), and  $P < 0.05$  was considered to be statistically significant. **Results:** Among the 150 respondents, 62.7% were males and 37.3% were females. The prevalence of MSD was observed as 58.7% and showed higher rates of pain in the neck (24%) followed by lower back region (20%) and upper back (14.7%). The associated risk factors were found to be number of working hours, number of cases treated per day, posture, and repetitive shoulder and hand movements ( $P < 0.05$ ). **Conclusion:** This study revealed a relatively high prevalence of musculoskeletal pain among dentists, and there is a need to implement and practice preventive measures in order to minimize the problem.

**Keywords:** Dental practitioner, musculoskeletal disorders, risk factors

## INTRODUCTION

The World Health Organization has characterized “work-related diseases” as multifactorial to indicate that a number of risk factors (e.g., physical, work organizational, psychological, psychosocial, individual, and sociocultural) contribute to these diseases. Musculoskeletal disorders (MSDs) are defined as a group of disorders that affect various organs of the musculoskeletal system. The term musculoskeletal disorders refers to conditions that involve nerves, tendons, muscles, and supporting structures of the body.<sup>[1]</sup> They may be caused by an interplay of specific risk factors acting during work-related activities, such as repetitive motions, obstinate or static positions, forceful movements, exposure to vibration (Raynaud’s disease), and mechanical stress. When these factors exist simultaneously, the risk of developing MSDs increases significantly. Inappropriate work area design, insufficient equipment, direct injuries, repetitive movements in

working areas with dental instruments, and sitting for extended time with a flexed and twisted back are contributing factors to various neck and low-back ailments.<sup>[2]</sup>

Dental professionals are commonly exposed to a variety of occupational risks such as chemical, mechanical, biological, and ergonomic issues, which create MSDs. The overall prevalence of MSDs in dentistry ranges from 63% to 93% worldwide.<sup>[3]</sup> As a result, they commonly experience musculoskeletal pain during the course of their careers and often have to limit or even abandon their professional activities. This has a negative impact on their finance and even on their healthy life.<sup>[2]</sup>

**Address for correspondence:** Dr. Anvesh Gandham,  
Department of Public Health Dentistry, Lenora Institute of Dental Sciences,  
NH-16, Rajanagaram, Rajahmundry - 533 294, Andhra Pradesh, India.  
E-mail: [gan.anvesh89@gmail.com](mailto:gan.anvesh89@gmail.com)

Received: 25-01-2019 Accepted: 27-04-2019

Access this article online	
Quick Response Code: 	Website: <a href="http://www.jiaphd.org">www.jiaphd.org</a>
	DOI: 10.4103/jiaphd.jiaphd_9_19

This is an open access journal, and articles are distributed under the terms of the Creative Commons Attribution-NonCommercial-ShareAlike 4.0 License, which allows others to remix, tweak, and build upon the work non-commercially, as long as appropriate credit is given and the new creations are licensed under the identical terms.

For reprints contact: [reprints@medknow.com](mailto:reprints@medknow.com)

**How to cite this article:** Gandham A, Boppana NK, Vinnakota NR, Burri KK, Kiran Th U, Pallepalli A. Assessment of musculoskeletal disorders and associated risk factors among dentists in Rajahmundry City: A cross-sectional study. *J Indian Assoc Public Health Dent* 2019;17:114-8.



## Original Article

# Evaluation of Styloid Process and Its Anatomical Variations: A Digital Panoramic Study with Systematic Review

Koduri Sridevi<sup>1</sup>, N. Mahesh<sup>2</sup>, B. Krishnaveni<sup>2</sup>, A. D. N. Deepika<sup>3</sup>, V. Thejasri<sup>3</sup>, B. H. David Leninson<sup>3</sup>

<sup>1</sup>Professor, <sup>2</sup>Reader, <sup>3</sup>Senior Lecturer, Department of Oral Medicine and Radiology, Lenora Institute of Dental Sciences, Rajahmundry, Andhra Pradesh, India

ABSTRACT

**Aims and Objectives:** To evaluate the styloid process (SP) and its anatomical variations on digital panoramic radiographs from the database and also to synthesize the current evidence of literature on SP and anatomical variations along with the systematic review of the relevant studies after making the necessary exclusions.

**Materials and Methods:** A total of 500 panoramic radiographs from the database were examined and evaluated for the length of SP using OmniVue software and for the calcification patterns which were categorized into three types as described by Langlais. The obtained values were analyzed using *t*-test and Chi-square tests with a significance level of 0.005 and SPSS version 20.0 software.

**Results and Conclusion:** The mean length of the SP in females was found to be 3.7 cm on the right side and 3.8 cm on the left side. The mean length of the SP in males was found to be 3.4 cm on the right side and 3.3 cm on the left side with significant difference between the genders with the *P* values of 0.0002 and 0.0001, respectively. The length of the SP was significantly longer in females than in males. Type I was the most common SP and was more prevalent in females. The results of the present study along with the wide range of reported incidence of anatomical variations in the form of elongation from the literature extracted through the systematic review suggests the need to reevaluate the range of the normal length of the SP.

**KEYWORDS:** Calcification patterns, digital panoramic radiograph, styloid process

Received : 08-01-19.  
Accepted : 18-02-19.  
Published : 07-06-19.

## INTRODUCTION

Styloid process (SP) is a long slender and pointed bony process projecting downward, forward, and slightly medially from the temporal bone. It arises from the temporal bone immediately in relation to the anteromedial aspect of the stylomastoid foramen. It is located between the internal and external carotid arteries and the internal jugular vein, and it is typically straight and occasionally curved.<sup>[1]</sup>

Styloglossus, stylopharyngeus, and stylohyoid are the muscles attached to the SP from the tongue, pharynx, and hyoid bone, respectively.<sup>[2]</sup> The stylohyoid and stylomandibular ligaments extend from the tip of the SP to the lesser cornua of the hyoid bone and to the angle and posterior border of angle of the mandible between masseter and medial pterygoid, respectively.

These ligaments help to regulate the movements of the mandible, the hyoid bone, the tongue, and the pharynx.<sup>[3]</sup>


Many critical anatomic structures such as facial and hypoglossal nerves, occipital artery, internal jugular vein, internal carotid artery, and posterior belly of the digastric muscle are closely located to the SP and the stylohyoid ligament.<sup>[4-7]</sup> The elongation of SP can frequently be encountered by calcification of stylohyoid and stylomandibular ligaments, being the potentially

*Address for correspondence:* Dr. Koduri Sridevi, Department of Oral Medicine and Radiology, Lenora Institute of Dental Sciences, Rajahmundry, Andhra Pradesh, India. E-mail: srigivi123@gmail.com

This is an open access journal, and articles are distributed under the terms of the Creative Commons Attribution-NonCommercial-ShareAlike 4.0 License, which allows others to remix, tweak, and build upon the work non-commercially, as long as appropriate credit is given and the new creations are licensed under the identical terms.

For reprints contact: reprints@medknow.com

How to cite this article: Sridevi K, Mahesh N, Krishnaveni B, Deepika AD, Thejasri V, Leninson BH. Evaluation of styloid process and its anatomical variations: A digital panoramic study with systematic review. J Int Soc Prevent Communit Dent 2019;9:256-62.

Access this article online	
Quick Response Code: 	Website: www.jispcd.org
	DOI: 10.4103/jispcd.JISPCD_8_19

## Review Article

# Recent Advances of Pacemakers in Treatment of Xerostomia: A Systematic Review

Rayapati Srinivasa Rao<sup>1</sup>, Rajesh Akula<sup>2</sup>, Tammineedi S. V. Satyanarayana<sup>3</sup>, Venkatagiri Indugu<sup>4</sup>

<sup>1</sup>Department of Prosthodontics, Teerthanker Mahaveer University Dental College and Research Centre, Moradabad, Uttar Pradesh, India, <sup>2</sup>Dental department, Ex-servicemen contributory health Scheme, Srikakulam, Andhra Pradesh, India, <sup>3</sup>Department of Prosthodontics and Crown and Bridge, KLR's Lenora Institute of Dental Sciences, Rajahmundry, Andhra Pradesh, India, <sup>4</sup>Department of Orthodontics and Dentofacial Orthopedics, St. Joseph Dental College, Eluru, Andhra Pradesh, India

Received : 07-11-18.  
Accepted : 01-05-19.  
Published : 06-08-19.

### ABSTRACT

**Objectives:** Treatment of dry mouth is the most common clinical challenge in the dental field. Although some remedies have been used to improve the signs and symptoms of xerostomia, none of them are absolutely satisfactory for the patients who have this alteration. In the current years, non-pharmacological treatments based on neuro-electro-stimulation for the treatment of xerostomia were developed. This review aimed at presenting recent developments for the treatment of xerostomia, applying neuro-electro-stimulation by miniaturized intraoral electrostimulators. **Materials and Methods:** A thorough literature search between 1986 and 2018 was carried out using PubMed Central, Scopus, National Science Library, ProQuest, and Google Scholar databases; the results were reviewed, prioritized, and the findings were compiled. Twenty-two studies were evaluated for the review. **Results:** This tool increases salivary secretion and improves xerostomia symptoms. Scientific trials have been carried out, which have revealed the wetting effect of the method described in this text. **Conclusion:** Neuro-electro-stimulation of the salivary gland plays an important role in the stimulation of saliva in patients who need further therapy and have poor quality of life. Intraoral electrostimulator offers a new non-pharmacological method for treating dry mouth.

**KEYWORDS:** Device and stimuli, electrostimulation, saliva, xerostomia

## INTRODUCTION

Sreebny (1988) defined xerostomia as the subjective feeling of oral dryness and it is the result of salivary gland hypofunction. These symptoms are more typical of older people but are not caused by aging. Unstimulated/resting saliva flow is 0.3 mL/min, whereas the flow rate in sleep is 0.1 mL/min and increases to 4.0–5.0 mL/min during chewing.<sup>[1]</sup> Prevalence has been estimated to range from 14% to 35% and has become increasingly common in developed countries.<sup>[2]</sup> Although it is more likely that treatment will take place in the middle to the end of life, xerostomia can occur in adolescent people, but less common in children.<sup>[3,4]</sup>

Saliva has many important functions, including mechanical cleansing action, solubilization of food,

detritus dilution, bolus, oral cavity lubrication, remineralization, and maintaining the integrity of the oral mucosa formed. Saliva provides antimicrobial activity and a buffer that protects teeth from decay.<sup>[5,6]</sup> People with xerostomia often complain of eating, talking, swallowing, and wearing dentures. Prosthetic users may have problems with prosthetic retention, oral mucositis, and the tongue attached to the palate. Patients with xerostomia often complain about dysgeusia, glossodynia, and the increased thirst, especially at night. Xerostomia can cause a significant increase in

*Address for correspondence:* Dr. Rajesh Akula, Dental Officer, Ex-servicemen contributory health Scheme, Seepannaidu peta, Srikakulam 532410, Andhra Pradesh, India.  
E-mail: rajeshakula1703@gmail.com

Access this article online	
Quick Response Code: 	Website: <a href="http://www.jispcd.org">www.jispcd.org</a>
	DOI: 10.4103/jispcd.JISPCD_389_18

This is an open access journal, and articles are distributed under the terms of the Creative Commons Attribution-NonCommercial-ShareAlike 4.0 License, which allows others to remix, tweak, and build upon the work non-commercially, as long as appropriate credit is given and the new creations are licensed under the identical terms.

For reprints contact: [reprints@medknow.com](mailto:reprints@medknow.com)

How to cite this article: Rao RS, Akula R, Satyanarayana TS, Indugu V. Recent advances of pacemakers in treatment of xerostomia: A systematic review. J Int Soc Prevent Communit Dent 2019;9:311-5.

## The Role of Polyether Ether Ketone (Peek) in Dentistry – A Review

Lakshmana Bathala<sup>1</sup>, Vaishnavi Majeti<sup>2</sup>, Narendra Rachuri<sup>1</sup>, Nibha Singh<sup>1</sup>, Sirisha Gedela<sup>1</sup>

1. Department of Prosthodontics, Lenora Institute of Dental Sciences, Rajahmundry, India

2. Department of Oral & Maxillofacial Surgery, Lenora Institute of Dental Sciences, Rajahmundry, India

---

### Corresponding Author:

Lakshmana Bathala

Professor & HOD, Department of Prosthodontics,  
Lenora Institute of Dental Sciences, Rajahmundry, A.P.,  
India Postal Code: 533294

Tel.: +919618652723 E-mail: kushulubathala@gmail.com

Received: January 10th, 2019 – Accepted: February 21st, 2019

### Abstract

This study is aimed to review the applications of Polyether Ether Ketone (PEEK) in dentistry. The increased demand for aesthetics, legislation in some developed countries, few drawbacks with existing materials and clinicians shifting their paradigms towards metal free restorations led space for the metal-free restorations in today's dental practice. An electronic literature search was conducted through Medline via PubMed, Wiley Online library, EBSCOhost, Science Direct, as well as the Google Scholar between January 2010 and March 2018 using the keywords: PEEK, modified PEEK, PEEK and Dental, advantages of PEEK, applications of PEEK in dentistry and PEEK Implants. A total of 103 articles were found in the literature search and out of these, 18 were not related to our study and hence were excluded. Finally, 85 articles were found to be relevant. PEEK has been explained for a number of applications in dental practice. The literature showed that the PEEK material has superior mechanical properties with different uses in various specialties of dentistry.

**Keywords:** Polyether Ether Ketone (PEEK), PEEK Implants, Modified PEEK polymer, Carbon Fiber Reinforced -Poly Ether Ether Ketone (CFR-PEEK), Telescopic Crowns, Obturator

**Abbreviations:** PEEK - Polyether Ether Ketone; CFR - PEEK- Carbon Fiber Reinforced - Polyether Ether Ketone; RPD-Removable Partial Denture; FPD - Fixed Partial Denture; MFP - Maxillofacial Prosthesis.

### Introduction

The long term success of dental implant depends mainly on minimizing the amount of marginal bone loss on functional loading. Titanium and its alloys and Zirconium are predominant in the field of implant materials in today's dental practice. Studies have already proven that these materials are biocompatible, but even these have some short comes, one of them being the elastic modulus. The elastic modulus of titanium and zirconia are 110 and 210 GPa respectively which is 5-14 times greater than that of compact bone having 15 GPa [1, 2]. Due to the gradient difference in the elastic modulus of a titanium implant to its surrounding bone, it may cause stress in the implant-bone interface during load transfer resulting in peri-implant bone loss [2]. This phenomenon is referred to as stress shielding, and it may be one of the important causes of long term failure of dental implants. Titanium implants are also known to cause image distortions in MRI scans [3]. Few studies also claimed that titanium is prone to hypersensitivity reactions [4]. Titanium can cause aesthetic problems due

to its lack of light transmission [5]. This can provoke a dark shimmer of the peri-implant soft tissue in cases of thin biotype mucosa and mucosa recession around the implant [6]. The existing materials despite having superior qualities have certain drawbacks like attrition of the natural teeth and bulkiness which may lead to a compromise in the retention of the prosthesis as well as patient satisfaction. The dental profession always thrives for better materials which can fulfill the pitfalls of the existing materials. PEEK is the latest inventory of dentistry and is claimed to have better properties in parallel with existing materials. Therefore, keeping all these in mind, in this review, we aimed to focus exclusively on the mechanical properties, advantages, modifications of the PEEK material and different uses of PEEK in various specialties of dentistry.

### Materials and Methods

An electronic literature search was conducted through Medline via PubMed, Wiley Online library, EBSCOhost,

## Case Report

# Seckel syndrome: A case report of the rare syndrome

N. Mahesh, Sivan Sathish, Lakshmayya Naidu, Sanjay Reddy, J. Rajesh K. Reddy<sup>2</sup>, Pavan Kancherla<sup>1</sup>

Departments of Oral Medicine and Radiology, <sup>1</sup>Orthodontics and Dentofacial Orthopedics and <sup>2</sup>Prosthodontics, K.L.R's Lenora Institute of Dental Sciences, Rajanagaram, Andhra Pradesh, India

### ABSTRACT

Seckel syndrome is a rare genetic disorder characterized by marked intra-uterine growth retardation (primordial dwarfism) and post natal dwarfism, microcephaly, mental retardation and typical facial features with a 'bird-headed' appearance. The syndrome has autosomal recessive inheritance with equal male and female sex occurrence. Here is an interesting case of a nineteen years old male patient, presented with various clinical manifestations, typical radiographic features and characteristic dental manifestations correlated with the literature. A thorough knowledge aids in better diagnosis, proper management and prevention of disastrous complications arising from this extremely rare inherited disorder, the Seckel syndrome.

**Key words:** Apertognathia, "Bird - like" facies, micrognathia, mental retardation

### INTRODUCTION

Seckel syndrome or microcephalic primordial dwarfism (also known as bird-headed dwarfism, Harper's syndrome, Virchow-Seckel dwarfism, and Bird-headed dwarf of Seckel)<sup>[1]</sup> is an extremely rare congenital autosomic disorder.

The syndrome is named after an American physician, Helmut Paul George Seckel.<sup>[2]</sup> Harper's syndrome, a term often used as a synonym for the Seckel syndrome, was named after Rita G. Harper.<sup>[3]</sup> The term "bird-headed dwarf" was initially introduced by Rudolf Virchow. The Seckel syndrome is a rare, congenital heterogenous autosomic rare disorder with an incidence of 1:10,000 in live born children,<sup>[4,5]</sup> presenting at birth.

#### Address for correspondence:

Dr. N. Mahesh, Department of Oral Medicine and Radiology, K.L.R's Lenora Institute of Dental Sciences, Rajanagaram, Andhra Pradesh - 533 294, India.  
E-mail: [dr.mahesh26@gmail.com](mailto:dr.mahesh26@gmail.com)

This syndrome is characterized by intrauterine growth retardation and postnatal dwarfism, with severe microcephaly, "bird-headed" appearance (beaked nose, receding forehead, prominent eyes, and micrognathia), and mental retardation.<sup>[6]</sup> Various other facial and skeletal abnormalities noted are low-set ears with hypoplastic ear lobules, premature closure of cranial sutures, fifth finger clinodactyly (permanent deviation or deflection of one or more fingers), dislocation of radial heads (pelvis and elbows), and 11 pairs of ribs.<sup>[7]</sup> The significant dental alteration in this syndrome is defective hypoplastic enamel.


### CASE REPORT

A young male patient aged 26 years reported department of oral medicine and radiology, with the chief complaint of pain in his decayed lower left back tooth for the past 2 weeks. His postnatal history revealed abnormal speech and stunted growth for the

This is an open access journal, and articles are distributed under the terms of the Creative Commons Attribution-NonCommercial-ShareAlike 4.0 License, which allows others to remix, tweak, and build upon the work non-commercially, as long as appropriate credit is given and the new creations are licensed under the identical terms.

**For reprints contact:** [reprints@medknow.com](mailto:reprints@medknow.com)

**How to cite this article:** Mahesh N, Sathish S, Naidu L, Reddy S, Reddy JR, Kancherla P. Seckel syndrome: A case report of the rare syndrome. *J NTR Univ Health Sci* 2018;7:223-7.

Access this article online	
Quick Response Code: 	Website: <a href="http://www.jdmtruhs.org">www.jdmtruhs.org</a>
	DOI: 10.4103/JDRNTRUHS.JDRNTRUHS_100_14

## Original Article

# Implications of Overprescription of Antibiotics: A Cross-Sectional Study

Punithavathy Ramachandran, Narendra Kumar Rachuri<sup>1</sup>, Satyam Martha, Rekha Shakhiv<sup>2</sup>, Anusha Gundala<sup>3</sup>, Thilak Sravan Battu

Departments of Pedodontics and Preventive Dentistry, <sup>1</sup>Prosthodontics and Crown and Bridge, Lenora Institute of Dental Sciences, Rajahmundry, Andhra Pradesh, <sup>2</sup>Department of Oral Pathology and Microbiology, Thai Moogambigai Dental College and Hospital, Chennai, Tamil Nadu, <sup>3</sup>Department of Periodontics, GSL Dental College, Rajahmundry, Andhra Pradesh, India

### ABSTRACT

**Introduction:** The use of antibiotics in recent years has become more aggressive and more common. The inappropriate use, to be more precise, the abuse of these prescriptions, is the root cause for increasing bacterial resistance and adverse outcomes. Antisepsis can be suggested as an appropriate alternative to antibiotics, to control the increasing antibiotic resistance among individuals. **Objective:** The objective of this study was to compare the awareness of antibiotic prescription and resistance among BDS and MDS practitioners and students. **Materials and Methods:** A total of 361 dental professionals were included in this study. Each of them was given a questionnaire containing questions pertaining to antibiotic prescription and awareness. **Results:** Most of the participants prescribed antibiotics as pre and post treatment management of all the oral diseases during their routine interaction with the patients. Overprescription of antibiotics, amoxicillin being the most common, was significantly more among the BDS practitioners than the MDS practitioners. BDS practitioners (78%) preferred a 3-day antibiotic prescription whereas MDS practitioners (80%) prescribed a 5-day course, which was statistically significant. Mindfulness with respect to antimicrobial prophylaxis and antibiotic resistance was observed to be satisfactory in both the groups. However, there was a general absence of mindfulness with respect to the rules for antibiotic prescription recommendations in both the groups. **Conclusion:** Antibiotic prescription should be given with care to prevent its resistance, an upcoming iatrogenic health hazard.

**KEYWORDS:** Amoxicillin, antibiotics, antibiotic resistance

## INTRODUCTION

The therapy of bacterial infections has seen a significant rise in the recent years characterized by several developments in the treatment of bacterial infections. Recent years have seen a sharp rise in the incidence of several bacterial infections that are resistant to antibiotics. The increased prescription of antibiotics may contribute to the bacterial resistance to antibiotics. The measures to control antibiotic resistance became the need of the hour and several measures were taken up to control the same.<sup>[1,2]</sup>

However, the overuse of antibiotics is now being observed as a major health challenge worldwide due to the increase in the spread of resistant pathogens in various health-care settings. The interests of both, the doctor

and the patient, contribute to the unnecessary antibiotic prescription, where the doctor feels pressured and succumbs to the patient's treatment preferences.<sup>[3]</sup> Thus, the increase in the bacterial resistance can be the result of inappropriate selection of the antibiotic, abuse/overuse of the availability of drugs over the counter, and subsequent development of less virulent or resistant strains.

In lieu of the increased bacterial resistance and approach in the dental practice, this study was conducted. Prophylactic antibiotics can be used in invasive dental

**Address for correspondence:** Dr. Punithavathy Ramachandran, Department of Pedodontics and Preventive Dentistry, Lenora Institute of Dental Sciences, NH-16, Rajanagaram, Rajahmundry 533294, East Godavari District, Andhra Pradesh, India. E-mail: [punithanaren@gmail.com](mailto:punithanaren@gmail.com)

Access this article online	
Quick Response Code: 	Website: <a href="http://www.jpbonline.org">www.jpbonline.org</a>
	DOI: 10.4103/jpbs.JPBS_62_19

This is an open access journal, and articles are distributed under the terms of the Creative Commons Attribution-NonCommercial-ShareAlike 4.0 License, which allows others to remix, tweak, and build upon the work non-commercially, as long as appropriate credit is given and the new creations are licensed under the identical terms.

For reprints contact: [reprints@medknow.com](mailto:reprints@medknow.com)

How to cite this article: Ramachandran P, Rachuri NK, Martha S, Shakhiv R, Gundala A, Battu TS. Implications of Overprescription of Antibiotics: A Cross-Sectional Study. J Pharm Bioall Sci 2019;11:5434-7.



ISSN: 0975-833X

Available online at <http://www.journalcra.com>

International Journal of Current Research  
Vol. 9, Issue, 11, pp.60701-60706, November, 2017

INTERNATIONAL JOURNAL  
OF CURRENT RESEARCH

## RESEARCH ARTICLE

### STEER A SHIP KNOWING THE DESTINATION"- A SURVEY TO ASSESS THE KNOWLEDGE & ATTITUDES OF DENTAL PERSONNEL TOWARDS BIOMEDICAL WASTE MANAGEMENT IN GODAVARI DISTRICTS OF ANDHRAPRADESH, INDIA

<sup>1</sup>Dr. Lakshmanarao Bathala, <sup>\*,2</sup> Dr. Rachuri Narendra Kumar, <sup>3</sup>Dr. Nibha Kumari Singh, <sup>4</sup>Dr. Dal Singh, V., <sup>5</sup> Dr. Rayapati Srinivasarao and <sup>6</sup>Dr. Mirna Garhnayak

<sup>1,2,3,4</sup>Lenora Institute of Dental Sciences, Rajahmundry, A.P., India, <sup>5</sup>Teerthanker Mahaveer Dental College and Research Centre, Moradabad, U.P. <sup>6</sup> Institute of Dental Sciences, SOA University, Bhubaneswar

#### ARTICLE INFO

##### Article History:

Received 28<sup>th</sup> August, 2017  
Received in revised form  
17<sup>th</sup> September, 2017  
Accepted 26<sup>th</sup> October, 2017  
Published online 30<sup>th</sup> November, 2017

##### Key words:

Bio-Medical Waste (BMW), Segregation, Colour coding, Biohazard.

#### ABSTRACT

Stern public health effects and a notable influence on the environment may be seen due to Indecorous and scanty handling of biomedical waste. A number of bio-medical waste materials generated by the dental set up are problematic, which includes, scrap amalgam, photochemical waste (developer and fixer), lead foil from traditional X-ray packets, blood-soaked materials, human tissue, and disinfectant solutions. If the hazardous and non hazardous wastes are mixed, the entire mixture must be consider and should be treated as hazardous waste. With indigent waste management, there may be a peril risk of nosocomial infections, and the unprofessional waste management can steer to spread of antibiotic resistance too. The dental fraternity in many countries is not following the ideal bio-medical waste execution diligently, hence this survey aimed at the knowledge of the dental personnel towards the biomedical waste and its secured disposal ways in Godavari districts of Andhrapradesh, India.

Copyright©2017, Dr. Lakshmanarao Bathala et al. This is an open access article distributed under the Creative Commons Attribution License, which permits unrestricted use, distribution, and reproduction in any medium, provided the original work is properly cited.

Citation: Dr. Lakshmanarao Bathala, Dr. Rachuri Narendra Kumar, Dr. Nibha Kumari Singh et al. 2017. "Steer a ship knowing the destination"- a survey to assess the knowledge & attitudes of dental personnel towards biomedical waste management in godavari districts of Andhrapradesh, India", *International Journal of Current Research*, 9, (11), 60701-60706.

#### INTRODUCTION

The segregation, disinfection, and dispose of bio-medical waste in an eco-friendly manner, was made mandatory by Bio-medical waste (management and handling) rules 1998 in India (Gazette of India, 1998). The waste can be treated according to the peril of the waste and it is possible only by means of segregation system, which is the duty of every waste generator to follow correct segregation system (Department for Environment, Food and Rural Affairs, 2012), (Thota et al., 2014). Having similar risks of different bio-medical waste groups combine in one main group by means of fixed colour and according to the hazardous nature, to identify easily the different waste groups have different colour for the containers/bags (Thota et al., 2014), with this segregation and disposal will become easy. To avoid the amalgam waste delivered in to the sewer through drains, the clinicians should install amalgam separators in the dental chairs. It is inevitable to protect the general public and environment from this infectious biomedical waste material. During therapeutic and diagnostic procedures as well as handling the waste, all the dental personnel should follow ubiquitous safety measures and appropriate protective measures. Nonregulated waste like used masks, gloves and gowns can be added to the regular trash.

\*Corresponding author: Lakshmanarao Bathala,  
Lenora Institute of Dental Sciences, Rajahmundry, A.P., India.

Before sending for the final disposal, the waste should be noninfectious, hence the waste should be disinfected. It is the duty of the generator to assess, whether that is dangerous waste or not. If not the entire waste will be considered as unsafe (ABCs of Dental Waste, 2012).

#### MATERIALS AND METHODS

The present study was a descriptive cross sectional study. The study location was at Godavi Districts of Andhrapradesh, India. A pre-tested self administered questionnaire was developed after literature search and review [Appendix-1]. The questionnaire was distributed to a total of 456 dental personnel includes 54 faculty, 86 post graduate students, 148 interns & Clinical Students and 168 practicing dental surgeons in two Godavari Districts of Andhrapradesh, for a period of 5 months from April 2017 to August 2017. A total 407 people responded. 11 faculty members, 3 post graduate students and 19 practicing Dental Surgeons were rejected the forms, 7 interns responded after 5 months, and 9 incomplete questionnaires from under graduate clinical students, which were excluded from the study.

#### Statistical Analysis

The data collected was entered in Microsoft Excel 2007 and data analysis was done using Statistical Package for Social



## Awareness of Dental Personnel of Two Dental Colleges in A.P, on the Role of Soft Skills in Dentistry- A Survey

Kotaiah Theruru<sup>1</sup>, Lakshmana Rao Bathala<sup>2\*</sup>, Murali Mohan Thota<sup>3</sup>, Madhuri V Songa<sup>3</sup>, Jyotsna M<sup>4</sup>, Dal Singh V<sup>4</sup> and Roopa Sri Gundala<sup>5</sup>

<sup>1</sup>Department of Pedodontics, Government Dental College and Hospital, Vijayawada, A.P, India

<sup>2</sup>Department of Prosthodontics, Lenora Institute of Dental Sciences, Rajahmundry, A.P, India

<sup>3</sup>Department of Conservative Dentistry, Government Dental College and Hospital, Vijayawada, A.P, India

<sup>4</sup>Department of Oral Pathology, Government Dental College and Hospital, Vijayawada, A.P, India

<sup>5</sup>Department of Periodontics, Lenora Institute of Dental Sciences, Rajahmundry, A.P, India

### Abstract

**Introduction:** Dental curriculum concentrated on hard skills which include theoretical and clinical knowledge only. Today the world realized the need for extra skills to have a competitive edge, which includes soft skills. They improve the performance and productivity. No dental teaching in India teaches soft skills to their under graduate students. To attain those skills one has to attend some extra training or course.

**Aims/Objectives:** There are very few documented studies are available on the role of soft skills in dentistry. The present study was undertaken to assess the awareness of the knowledge, attitude and behaviour of dental personnel in 2 teaching dental institutes in Andhra Pradesh, towards role of Soft skills in Dentistry.

**Materials and Methods:** A cross-sectional descriptive study was conducted. Over a period 4 months from Oct 2016 to Jan 2017. A pre-tested self-administered questionnaire was given to a total of 431 dental personnel includes faculty, post graduate students, interns and undergraduate clinical students (both 3<sup>rd</sup> & 4<sup>th</sup> B.D.S). Statistics was analysed by SPSS software 19 version. Frequencies and percentages were calculated.

**Results:** The survey forms were distributed in two dental teaching institutes to a total of 407 dental personnel, including 43 faculty, 83 post graduate students, 132 interns and 149 under graduate clinical students (3<sup>rd</sup> & 4<sup>th</sup> BDS). Statistical analysis is done by SPSS software. Majority of the dental personnel were aware of hard skills but only few are really knows about soft skills.

**Conclusion:** Due to the scientific nature of the curriculum, the technical skills are more focused in Dentistry. Many of the dental personnel's including faculty not aware of the soft skills. All the dental teaching institutes need to incorporate the soft skills in their under graduate teaching curriculum. Regularly all the dental personnel need to attend some soft skills training.

**Keywords:** Hard skills; Emotional intelligence quotient (EQ); Domain skills; Communication skills; Positive attitude; Role model

### Introduction

Dental curriculum concentrated on hard skills which include theoretical and clinical knowledge only. Today the world realized the need for extra skills to have a competitive edge, which includes soft skills. They improve the performance and productivity. Hard skills are the technical abilities which are required to perform a job and are also called as technical skills. These are object oriented, requires high IQ and Clinical skills [1]. Whereas communicative skills, positive attitude and leadership qualities comes under soft skills, and are also known as life skills [2]. These are people oriented and require high EQ (Emotional Intelligence Quotient) [3,4].

Soft skills will not be considered as alternative to the hard skills but they can be treated as additional qualities [2]. For the successful journey of dental practice, one needs both hard and soft skills in equal proportions. By adopting these skills, the academicians, practitioners as well as the student community will acquire best learning experience.

### Materials and Methods

The present study was a descriptive cross sectional study. The study location was at Lenora Institute of Dental Sciences, Rajahmundry, Andhra Pradesh and Government Dental College and Hospital, Vijayawada, Andhra Pradesh. Proper permissions were obtained from the Institutional Ethical Committee. A pre-tested self-administered questionnaire was developed after literature search and review

(Appendix-1). The questionnaire was distributed to a total of 431 dental personnel includes 54 faculty, 86 post graduate students, 137 interns and 154 under graduate clinical students (both 3<sup>rd</sup> & 4<sup>th</sup> B.D.S) in two dental teaching institutions in Andhra Pradesh, for a period of 4 months from October 2016 to January 2017. A total 407 people responded. 11 faculty members and 3 post graduate students were rejected the forms, 5 interns responded after 4 months, and 5 incomplete questionnaires from under graduate students were excluded from the study.

### Statistical Analysis

The data collected was entered in Microsoft Excel 2007 and data analysis was done using SPSS (Statistical Package of Social Sciences) software 19 version. Descriptive statistics were done to assess frequency and percentage for responses of the participants. Categorical data was

**\*Corresponding author:** Lakshmana Rao Bathala, Professor and HOD, Department of Prosthodontics, Lenora Institute of Dental Sciences, Rajahmundry, A.P, India, Tel: + 09618652723; E-mail: kushlubathala@gmail.com

Received March 29, 2017; Accepted May 25, 2017; Published June 01, 2017

**Citation:** Theruru K, Bathala LR, Thota MM, Songa MV, Jyotsna M, et al. (2017) Awareness of Dental Personnel of Two Dental Colleges in A.P, on the Role of Soft Skills in Dentistry- A Survey. J Clin Diagn Res 5: 139. doi: 10.4172/2376-0311.1000139

**Copyright:** © 2017 Theruru K, et al. This is an open-access article distributed under the terms of the Creative Commons Attribution License, which permits unrestricted use, distribution, and reproduction in any medium, provided the original author and source are credited.

# Periodontal and Dentition Status among Orphans and Children with Parents in Mysore City, India: A Comparative Study

RAVI KUMAR THETAKALA<sup>1</sup>, S SUNITHA<sup>2</sup>, BR CHANDRASHEKAR<sup>3</sup>, PRIYANKA SHARMA<sup>4</sup>, NC KRUPA<sup>5</sup>, Y SRILATHA<sup>6</sup>

## ABSTRACT

**Introduction:** Oral health symbolises the general health and quality of life of an individual. The socioeconomic status of the parents shows direct impact on oral health status of children. Thus, it can be hypothesised that the pattern of oral diseases would be different among children living with parents and orphans.

**Aim:** To explore periodontal and dentition status among orphans and children with parents in Mysore city, India.

**Materials and Methods:** A cross-sectional study was conducted among six to 15-year-old children residing in eight orphanages. Equal number of age and gender matched children living with parents were selected from government schools (non orphans) located in the same geographical areas for comparison. Clinical examination was conducted by a single trained, calibrated

examiner and oral findings were recorded according to World Health Organization (WHO) diagnostic criteria 2013. The data collected was analysed using Mann-Whitney U test and Chi-square test.

**Results:** A total of 957 children (478 from orphanages and 479 from government schools) were examined in the study. The mean defs and DMFS were significantly higher among government school children (non orphans) (defs: 3.20±4.0; DMFS: 2.43±2.8) compared to children from orphanages (defs: 2.72±4.4; DMFS: 1.72±2.3). Prevalence of gingival bleeding among orphans (79.49%) was higher compared to non orphans (71.4%).

**Conclusion:** The present study concluded that prevalence of caries was lower among orphans but periodontal status was poor among them as compared to non orphans.

**Keywords:** Gingival bleeding, Oral health status, DMFT (Decayed, Missing and Filled teeth)

## INTRODUCTION

Oral health symbolises the general health and quality of life of an individual [1]. It may be defined as a standard of health of the oral and related tissues which facilitates an individual to eat, speak and socialise without active disease, distress or awkwardness and which contributes to general well being [2].

In developing countries, majority of the population is formed by poor and marginalized people. This underserved low socioeconomic population has poor oral health status due to their lack of affordability towards basic and emergency health care services [3]. UNICEF and global partners define an orphan as a child who has lost one or both parents [4]. One of the known high risk groups is the orphans [5].

India has the highest population of children below the age of 18, i.e., 41% of the total population. According to study done by SOS Children's Village by analysing data from National Family Health Survey-3 (2005-06), about 4% of Indian population i.e., more than people residing in Delhi are orphans which constitute about 20 million children [6]. These children form a population at risk with reference to abnormal psychosocial development [7]. According to the recent estimates, 71% of Indian children are educated through government schools [8], making them as the major provider of education. Students of government schools are one more high risk group which normally house children from low socioeconomic background [9].

The schools have been an important setting in offering an effective way to reach children worldwide and, through them, families and community members. During schooling, children are particularly sympathetic and earlier the habits are established, more enduring the impact will be. Furthermore, messages can be reinforced repeatedly throughout the school years [10]. After many studies

being conducted to assess the periodontal and dental status among low socioeconomic status [11,12], handicapped [13] and mentally challenged populations [14,15], there is still scanty information on periodontal and dentition status among orphan population and their comparison with children with parents.

Early identification of high risk groups helps in preventing and controlling diseases during their early stages by the implementation of preventive and educational programs on health [16]. In the present circumstances, it is important to identify high risk groups for best utilisation of scant resources that helps in prioritising the oral health services to the deprived population during policy making and school health programs. Hence, the present study was undertaken to assess and compare the periodontal and dentition status among orphans and children with parents from low socioeconomic background in Mysore city (presently called as Mysuru), India.

## MATERIALS AND METHODS

The present descriptive cross-sectional study was undertaken over a period of six months from March to August 2015 on children from eight orphanages and seven government schools in Mysuru city, India. The children selected from government schools situated in localities housing the orphanages in Mysuru city were considered as comparative group. (Since two orphanages were in nearby location, only one government school in same geographical area was considered for comparison)

Prior to the study, ethical clearance was obtained from the Institutional Ethical Committee, JSS Dental College and Hospital, Mysuru in accordance with the World Medical Association Declaration of Helsinki 2008. The list of orphanages was obtained from the Department of District Women and Children Welfare Office, Mysuru.





## RESEARCH ARTICLE

### ORAL HEALTH STATUS AND TREATMENT NEEDS OF PRISONERS IN DISTRICT JAIL OF RAICHUR CITY, KARNATAKA – A CROSS SECTIONAL STUDY

\*<sup>1</sup>Vengal Rao, B., <sup>2</sup>Kamalsha, S. K., <sup>3</sup>Sirisha Rao, M., <sup>4</sup>Pradnya Jadhav and <sup>5</sup>Divya Sahu

<sup>1</sup>Department of Public Health Dentistry, K.S.R Institute of Dental Sciences and Research, Tiruchengode, Tamilnadu, 637215, India

<sup>2</sup>Department of Public Health Dentistry, KLR. Lenora Institute of Dental sciences, Rajahmundry, Andhrapradesh

<sup>3</sup>Department of Public Health Dentistry, Sree Sai Dental College and Research Institute, Srikakulam, Andhrapradesh

<sup>4</sup>Department of Public Health Dentistry, Sinhgad Dental College and Hospital, Pune, Maharashtra

<sup>5</sup>Department of Pedodontics, Triveni Institute of Dental Sciences and Hospital, Bilaspur, Chhattisgarh

#### ARTICLE INFO

##### Article History:

Received 17<sup>th</sup> January, 2017

Received in revised form

10<sup>th</sup> February, 2017

Accepted 21<sup>st</sup> March, 2017

Published online 30<sup>th</sup> April, 2017

##### Key words:

Oral health status,  
Treatment needs,  
Prisoners.

#### ABSTRACT

**Background and objectives:** The prison population is a unique and challenging one, with many health problems, including poor oral health. Dental diseases can reach epidemic proportions in the prison setting. The aim of the study was to assess the oral health status and treatment needs of prisoners in district jail of Raichur city, Karnataka.

**Material and Methods:** A cross sectional study was carried out on 102 prisoners (males were 98 and females were 04) in the district jail of Raichur. A specially designed questionnaire was used to assess the demographic variables and oral hygiene practices. A clinical examination was done according to WHO (World Health Organization) criteria 1997 and recorded using WHO Oral Health Assessment Form.

**Results:** The mean age of the study subjects was 29.9(± 9.74) years and the mean DT, MT, FT and DMFT was 1.59(±1.58), 0.52(±3.02), 0.05(±0.21) and 2.16 (±3.44) respectively. The prevalence of dental caries and periodontal disease was 76.5% and 93.1% respectively. The oral hygiene status was poor in 33.7% of the study subjects.

**Conclusion:** Poor oral hygiene, high prevalence of periodontal disease and dental caries are major public oral health problem among the prisoners, which require special attention and efforts from government and other organizations to meet their treatment needs.

Copyright©2017, Vengal Rao et al. This is an open access article distributed under the Creative Commons Attribution License, which permits unrestricted use, distribution, and reproduction in any medium, provided the original work is properly cited.

Citation: Vengal Rao, B., Kamalsha, SK., Sirisha Rao, M., Pradnya Jadhav and Divya Sahu, 2017. "Oral health status and treatment needs of prisoners in district jail of Raichur city, Karnataka – A cross sectional study", *International Journal of Current Research*, 9, (04), 49408-49412.

#### INTRODUCTION

Health is a fundamental right of every individual and oral health is an integral part of general health. Various factors are responsible for maintenance of good oral health. Socioeconomic status, occupation, education are playing major role in maintenance of good oral health (Dhanker et al., 2013). Our society consists of different group of people have different levels of perception and facilities to maintain good oral health. Different population groups have been assessed for oral health status in our country. Still many groups have been neglected; one such group is the prisoners (Uma and Hiremath, 2011). Prisoners make a special group of population as they are

different from other people in context of their "freedom of movement". The majority of prisoners are those who come from a context already shaped by social exclusion (Anup et al., 2014). The prisoner's area psychologically, socially, morally and economically affected group which makes them to neglect their general as well as oral health. It is generally acknowledged from extensive research that prisoners are vulnerable to a wide range of health problems, most commonly alcohol and drug abuse, smoking, chronic diseases, mental illness, psychosocial and psychiatric problems (Anup et al., 2014). Many prisoners enter prison with poor oral health requiring emergency treatment. This may be due to limited knowledge about good oral health practices. Substance misuse contributes to high levels of tooth decay and gum disease. Excessive alcohol consumption, particularly spirits, and tobacco use increase the prevalence and severity of periodontal disease and are by far the greatest risk factors for oral cancer

\*Corresponding author: Vengal Rao, B.

Department of Public Health Dentistry, K.S.R Institute of Dental Sciences and Research, Tiruchengode, Tamilnadu, 637215, India.

# Perceptions on Faculty Development among Dental Faculty in Andhra Pradesh

Sudharani N. V. Guntupalli, Suresh Sanikommu, Srinivas Pachava, Devaki Talluri, Srinivas Ravoori, Siva Kumar Pydi<sup>1</sup>, Narayana Rao Vinnakota<sup>2</sup>

Department of Public Health Dentistry, Sibar Institute of Dental Sciences, Dr. NTR University of Health Sciences, Guntur, <sup>1</sup>Department of Public Health Dentistry, Anil Neerukonda Institute of Dental Sciences, Dr. NTR University of Health Sciences, Vishakhapatnam, <sup>2</sup>Department of Public Health Dentistry, Lenora Institute of Dental Sciences, Dr. NTR University of Health Sciences, Rajahmundry, Andhra Pradesh, India

## Abstract

**Introduction:** Development of the teaching skills by the faculty has become a critical component of health professionals' education. Faculty development is an important tool for improving educational standards. **Aim:** The aim of this study is to assess the perceptions on faculty development among dental faculty members in Andhra Pradesh. **Materials and Methods:** A cross-sectional survey was conducted during the months of August and September 2015 in five randomly selected dental institutions of Dr. NTR University of Health Sciences, Andhra Pradesh. Semi-structured, self-administered questionnaires were distributed to faculty members who were present on the day of survey and collected personally. Chi-square test was used to analyze the categorical data using SPSS version 20. **Results:** A total of 130 respondents returned duly filled forms. Mean age of the respondents was  $34.7 \pm 6.53$  years. Nearly 80% of the respondents never attended any faculty development program. Preponderance of the respondents reported a lack of any established faculty development program in their respective institutions. Half of the respondents reported that they had not received any support from their institutions for improving their teaching skills. The most frequently reported barrier for faculty development was a lack of initiation from authorities followed by excessive clinical and teaching load. Majority of the respondents felt that faculty development programs can improve standards of dental education and quality of dental care. Ninety-three percent of the faculty members were interested in attending faculty development programs. **Conclusion:** It is time for the institutions and authorities to initiate reforms to remove the barriers and provide institutional support for faculty development programs.

**Keywords:** Dental education, dental faculty, faculty development, perception

## INTRODUCTION

Education can be broadly described as an act or process of imparting or acquiring general knowledge, developing the powers of reasoning and judgment, and preparing oneself to lead a meaningful life. It is the act or process of imparting or acquiring particular knowledge or skills, required for a profession.<sup>[1]</sup> Teaching is considered among the noblest of professions in India. "Guru" the Sanskrit word for "teacher" is given a status equal to that of god in ancient Indian scriptures. As early as in the 5<sup>th</sup> century BC, Takshasila was recognized as the center for learning medicine.<sup>[2]</sup> At present, medical education in India is provided by various number of colleges, both private and government, which are generally governed by the universities of health sciences of the respective states.

The role of a teacher in a student's life is very crucial right from the time the child joins the kindergarten to the stage when

he/she takes a step forward toward establishing a professional career. Not all the teachers possess the same characteristics.<sup>[3]</sup> In today's competitive world, mediocrity is not tolerated and just being good is not appreciated. Students are expecting their teachers to be at least superior if not great. Thus, development of the teaching skills by the faculty has become a critical component of health professionals' education.

Faculty development programs have been defined in several ways. According to Wilkerson and Irby,<sup>[4]</sup> it is a tool for improving the educational vitality of institutions through

**Address for correspondence:** Dr. Suresh Sanikommu, Department of Public Health Dentistry, Sibar Institute of Dental Sciences, Takkellapadu, Guntur, Andhra Pradesh, India. E-mail: [drsureshjvv@gmail.com](mailto:drsureshjvv@gmail.com)

This is an open access article distributed under the terms of the Creative Commons Attribution-NonCommercial-ShareAlike 3.0 License, which allows others to remix, tweak and build upon the work non-commercially, as long as the author is credited and the new creations are licensed under the identical terms.

For reprints contact: [reprints@medknow.com](mailto:reprints@medknow.com)

**How to cite this article:** Guntupalli SN, Sanikommu S, Pachava S, Talluri D, Ravoori S, Pydi SK, *et al.* Perceptions on faculty development among dental faculty in Andhra Pradesh. *J Indian Assoc Public Health Dent* 2017;15:151-6.

Access this article online	
Quick Response Code: 	Website: <a href="http://www.jiaphd.org">www.jiaphd.org</a>
	DOI: 10.4103/jiaphd.jiaphd_177_16

# Antibacterial Activity of Freshly Prepared Ozonated Water and Chlorhexidine on *Mutans Streptococcus* When Used as an Oral Rinse – A Randomised Clinical Study

LAVANYA ANUMULA<sup>1</sup>, KV SUNEEL KUMAR<sup>2</sup>, CHNV MURALI KRISHNA<sup>3</sup>, K SREE LAKSHMI<sup>4</sup>

## ABSTRACT

**Introduction:** Dental caries is one of the most common causes of morbidity of the tooth. Attempts have been made to reduce the pathogen population size i.e., *Mutans Streptococci* (MS) to demote the incidence of caries and increase the resistance of the tooth to cariogenic attack.

**Aim:** To evaluate the antibacterial efficacy of freshly prepared ozonated water, in proposing it as an alternative mouth rinse on MS in comparison to Chlorhexidine (CHX).

**Materials and Methods:** Subjects with high caries incidence and MS counts more than  $10^5$  Colony Forming Unit (CFU) were selected and divided by block randomization into two groups of 23 subjects each. The subjects were advised to use

the respective mouth rinses under the operator surveillance, consecutively for 14 days. Stimulated salivary samples were collected from the subjects on the first day, 7<sup>th</sup> and 14<sup>th</sup> day to analyse the changes in MS counts during the course of use of oral rinses. The obtained data was tabulated and statistically analysed.

**Results:** Freshly prepared ozonated water showed a statistically significant reduction in MS counts after an interval of 7 days and 14 days when compared to CHX.

**Conclusion:** Ozonated water when consecutively used as a mouth rinse resulted in a significant reduction of MS counts. Hence, it can be used as an alternative to chlorhexidine.

**Keywords:** Aqueous ozone, Dental caries, High caries risk, Mouth rinse

## INTRODUCTION

Dental caries still remains to be one of the most common diseases and a global health problem that affects about 60%-90% of the population [1-3]. The bacterial colonization of *Mutans Streptococci* (MS) on the tooth, makes it more vulnerable for the development of dental caries [4,5]. At the outset, caries diagnosis and treatment were restricted and primarily aimed at detection and restoration of cavitated lesions, thus futile in dealing with the underlying aetiological factors. Now, as a part of the medical model, preventive treatment for caries is mainly based on reducing the pathogen population size and increasing the resistance of the tooth to cariogenic attack. Many chemotherapeutic agents or antimicrobial agents are available to reduce the MS counts, amongst which CHX (0.12%) is the most commonly used [6,7]. CHX is bacteriostatic at low concentrations and bactericidal at high concentrations. It has a broad antimicrobial spectrum (i.e., against Gram positive/negative bacteria and fungi), thus making it effective against many oral bacterial species. But the long term use of CHX has few disadvantages such as teeth staining [8] and altered taste sensation [9].

Ozone ( $O_3$ ) is the triatomic form of oxygen ( $O_2$ ). It is oxygen in its most active state and is an extremely potent oxidant that has been shown to possess broad spectrum antimicrobial activity. The oxygen radicals cause cellular lysis by penetrating the microbial cell membrane in the presence of water, thus affecting its osmotic stability [10]. Ozone, in either gaseous or aqueous phases, is widely used as a disinfectant due its wide range of microbiologic and metabolic activity [11]. The efficacy of ozonated water as mouth rinse on MS has not been reported earlier. In proposing ozonated water as another potential antimicrobial mouth rinse, it is important to compare it with other agents. Thus, the objective of the study was to assess and compare the effect of ozonated water and 0.2% CHX on the level of MS in the saliva when used as a mouth rinse.

## MATERIALS AND METHODS

This open label randomized two arm parallel group's clinical study was conducted in RIMS government dental college, Kadapa, Andhra Pradesh, India, for over a period of two months from September 2010 to October 2010. The study was reviewed and approved by the Institutional Ethical Committee. A total of 46 healthy young adults, who volunteered, were explained about the study and written informed consent was obtained from them. Both males and females in the age group of 16 and 30 years, having DMFT index to be more than 3, missing teeth due to past caries experience, MS counts  $>10^5$ CFU/ml (tested at their initial visit) and those who were neither using antibiotics nor any mouthwash from past six months were enrolled. Subjects with missing teeth due to reason other than caries and/or who have undergone radiation therapy or having any dysfunction of the salivary glands, and/or who have undergone any surgical or non-surgical therapy in the past six months were excluded. The subjects who fulfilled the inclusion criteria were recalled after two days, and were then randomly allocated by block randomization to two groups. Any carious lesion open to the oral cavity was excavated and restored prior to the participants' allocation to treatments. The random selection of the blocks was done using a list of computer generated random numbers. The variables used for sample size calculation was the reduction in bacterial counts (Efficiency). The power of the study was 80%. A study of independent two treatment study in with 1:1 ratio was planned. Prior data indicated that the reduction in bacterial counts rate with ozone (gas) is 0.5. For experimental subjects, it is 0.9. Therefore, study included 23 experimental subjects and 23 control subjects to be able to reject the null hypothesis such that the success rates for experimental and control subjects are equal with probability (power) 0.8. The Type I error probability associated with this test of this null hypothesis is 0.05.

## Case Report

# Fracture Fragment Reattachment Using Projectors and Anatomic everStick Post™: An Ultraconservative Approach

Velagala L Deepa, Satti Narayana Reddy, Venkata Charan Teja Garapati, Srirama Rao Sudhamashetty, Padmasri Yadla

Department of Conservative Dentistry and Endodontics, Lenora Institute of Dental Sciences, Rajahmundry, Andhra Pradesh, India

Received : 15-04-17.  
Accepted : 27-05-17.  
Published : 20-06-17.

### ABSTRACT

Traumatized anterior teeth require quick functional and esthetic repair. Tooth fragment reattachment is a simple and conservative clinical procedure to restore fractured anterior teeth. Different techniques of reattachment include enamel beveling, “v-” shaped internal enamel and dentin grooves, external chamfer, over contouring, and by placing fiber post, all of which were invasive methods. This article describes a novel technique of reattachment using canal projectors for stabilizing fractured fragments followed by endodontic therapy and internal reinforcement with custom fiber post (everStick Post™, GC Corporation, Tokyo, Japan).

**KEYWORDS:** Canal projectors, fiber post, reattachment

## INTRODUCTION

Reattachment of fractured coronal tooth fragment without invading the attachment apparatus is one of the most currently acceptable noninvasive treatment options with a high clinical success due to vast advancements in adhesive technology.<sup>[1]</sup> Simple complicated supragingival fractures can be managed by endodontic therapy followed by bonding the fragments and stabilized with a fiber post.<sup>[2-4]</sup> An ultraconservative option of managing such fractures is by preendodontic stabilization using projectors followed by endodontic therapy and internal reinforcement using individualized custom fiber post.

Canal projectors were first introduced by Gerald N Glickmann and Roberta Pileggi to maintain the patency of the root canal during preendodontic buildup of a badly mutilated tooth. These projectors provide direct visualization and access to the projected canals. In this case report, we have described the unique benefits of using canal projection, not only for stabilizing fractured coronal fragment but also acts as a “hydraulic chamber” with increased surface area for even distribution of stresses.<sup>[5]</sup>

Recently a new soft, flexible individually formable resin-impregnated E-glass fiber post (everStick Post™, GC Corporation, Tokyo, Japan) with patented

interpenetrating polymer network was introduced to suit any root canal morphology without the need for postspace preparation thus preserving the root dentin. These are available in three diameters of 0.9 mm, 1.2 mm, and 1.5 mm having 1600, 2000, and 4000 fibers, respectively, with a modulus of elasticity similar to that of dentin, facilitating even distribution of occlusal stresses.<sup>[6]</sup>

This article presents a novel technique of fractured fragment reattachment using projectors and individually formable everStick™ glass fiber posts.

## CASE REPORT


A 23-year-old male patient reported a day after trauma with fractured maxillary left central incisor. On clinical examination, a simple complicated fracture with a supragingival fracture line in the cervical third extending mesiodistally on the labial surface with

*Address for correspondence:* Dr. Velagala L Deepa, Department of Conservative Dentistry and Endodontics, Lenora Institute of Dental Sciences, Rajanagaram, Rajahmundry, Andhra Pradesh, India.  
E-mail: [drdeepamesh@yahoo.com](mailto:drdeepamesh@yahoo.com)

This is an open access article distributed under the terms of the Creative Commons Attribution-NonCommercial-ShareAlike 3.0 license, which allows others to remix, tweak, and build upon the work non-commercially, as long as the author is credited and the new creations are licensed under the identical terms.

For reprints contact: [reprints@medknow.com](mailto:reprints@medknow.com)

How to cite this article: Deepa VL, Reddy SN, Garapati VC, Sudhamashetty SR, Yadla P. Fracture fragment reattachment using projectors and anatomic everStick post™: An ultraconservative approach.. J Int Soc Prevent Communit Dent 2017;7:S52-4.

Access this article online	
Quick Response Code: 	Website: <a href="http://www.jispcd.org">www.jispcd.org</a>
	DOI: 10.4103/jispcd.JISPCD_151_17

## ORIGINAL RESEARCH ARTICLE

Year : 2017 | Volume : 20 | Issue : 3 | Page : 204-209

## One-year comparative evaluation of Ketac Nano with resin-modified glass ionomer cement and Giomer in noncarious cervical lesions: A randomized clinical trial

Bollu Indira Priyadarshini<sup>1</sup>, Thumu Jayaprakash<sup>1</sup>, Bolla Nagesh<sup>2</sup>, Chukka Ram Sunil<sup>2</sup>, Varri Sujana<sup>2</sup>, Velagala L Deepa<sup>3</sup>,<sup>1</sup> Department of Conservative Dentistry and Endodontics, St. Joseph Dental College, Eluru, India<sup>2</sup> Department of Conservative Dentistry and Endodontics, Sibar Institute of Dental Sciences, Guntur, India<sup>3</sup> Department of Conservative Dentistry and Endodontics, Lenora Institute of Dental Sciences, Rajahmundry, Andhra Pradesh, India

## Correspondence Address:

Bollu Indira Priyadarshini  
Department of Conservative Dentistry and Endodontics, St. Joseph Dental College, Duggirala, Eluru, West Godavari - 534 003, Andhra Pradesh  
India

## Abstract

**Aim:** The purpose of this study was to evaluate the clinical performance of Ketac Nano (Ketac™ N100), RMGIC (Fuji Filling™ LC), and Giomer (Beautifil® II) in noncarious cervical lesions (NCCLs). **Materials and Methods:** One operator restored 120 NCCLs in 20 subjects, with at least two lesions restored with one of the restorative materials: RMGIC (control group), Giomer and Ketac Nano (experimental groups). Two observers evaluated retention, marginal discoloration, marginal adaptation, color match, surface roughness, and postoperative sensitivity using modified USPHS criteria at baseline, 6, and 12 months. **Study Design:** Double-blinded randomized clinical trial (RCT). **Statistical Analysis:** Kruskal-Wallis test, Mann-Whitney U-test, Wilcoxon matched-pairs test. **Results:** There was statistically significant difference observed between Giomer, Ketac Nano and RMGIC after 12 months ( $P < 0.05$ ). There was a significant decrease in retention rates for Giomer ( $P = 0.0050$ ), increased marginal discoloration and color mismatch for Ketac Nano ( $P = 0.0025$ ,  $P = 0.0053$ ), increased surface roughness and color mismatch with RMGIC ( $P = 0.0022$ ,  $P = 0.0077$ ) from baseline to 12 months. **Conclusion:** Within the limitations of this RCT of 12 months, Ketac Nano and RMGIC restorations were better retained in NCCLs while superior color match and surface finish were observed with Giomer restorations.

## How to cite this article:

Priyadarshini BI, Jayaprakash T, Nagesh B, Sunil CR, Sujana V, Deepa VL. One-year comparative evaluation of Ketac Nano with resin-modified glass ionomer cement and Giomer in noncarious cervical lesions: A randomized clinical trial. J Conserv Dent 2017;20:204-209

## How to cite this URL:

Priyadarshini BI, Jayaprakash T, Nagesh B, Sunil CR, Sujana V, Deepa VL. One-year comparative evaluation of Ketac Nano with resin-modified glass ionomer cement and Giomer in noncarious cervical lesions: A randomized clinical trial. J Conserv Dent [serial online] 2017 [cited 2022 Oct 29];20:204-209

Available from: <https://www.jcd.org.in/text.asp?2017/20/3/204/218305>

## Full Text

Introduction

Noncarious cervical lesions (NCCLs) occur at the neck of the tooth having multifaceted etiology, but not caused by dental caries, which manifests as abrasion, erosion, and abfraction.[1], [2] Levitch et al. have suggested NCCLs need to be restored to prevent hypersensitivity, loss of tooth structure and pulpal exposure, enhance esthetics, and for the placement of partial denture design.[3]

Challenges encountered by the clinician during the restoration of NCCLs include dentinal sclerosis,[4] concentrated occlusal loading leading to cuspal flexure,[5] lack of mechanical retention, difficulty in moisture control and isolation, along with shape and location of these lesions.[2] Therefore, selection of restorative material is a critical factor in determining the clinical success.[2],[6] Several materials and techniques have been tried to obtain the best performance in NCCLs,[6] among which most commonly used restorative materials are glass ionomers cements (GIC), RMGIC, and resin composites (RCs) and their combinations.[2],[5],[6]

Fuji Filling™ LC is a dual cure RMGIC, available in paste/paste system which helps in better handling characteristics compared to powder/liquid form.[7] RMGICs possess an improved mechanical strength, low moisture sensitivity, and improved clinical performance when compared to conventional GIC.[7],[8] Brackett et al. have reported no significant difference in overall clinical performance of RMGIC when compared to RC in NCCLs after 2 years follow-up.[9] Vaid et al. after 1-year follow-up observed no significant difference between performance of RMGIC, Equia, and Nano Hybrid RC in NCCLs.[10]

Beautiful® II belongs to the second generations Giomer which uses surface-preacted glass technology. Giomers are developed by combining the properties of RC along with high fluoride release and rechargeability of GIC.[11],[12] Jyothi et al.[12] observed no significant difference in the clinical behavior of Giomer and RMGIC in NCCLs after 1-year follow-up.

Ketac™ N100 is new light cured Nano-Filled RMGIC, which is supplied in user-friendly nonrinsing, paste/paste dispensing system. It has silane-treated glass, silica, zirconia, and ceramic nano fillers. Manufacturer claims increased mechanical properties, wear resistance, and high polish retention.[13] Perdigo et al. after 1-year recall observed a significant difference between RMGIC, Nano-Filled RMGIC, and RC IN NCCLs.[8]

The available literature does not show any studies comparing the clinical performance of RMGIC (Fuji Filling™ LC), Ketac Nano (Ketac™ N100), and Giomer (Beautifil® II) in NCCLs. Hence, the purpose of the present study is to compare and evaluate the clinical performance of Ketac Nano with RMGIC and Giomer. The null hypothesis was there is no difference in the clinical performance of these three restorative materials in NCCLs after 1-year follow-up.

Materials and Methods

This clinical trial followed the Consolidated Standards of Reporting Trials statement[14] and was conducted after obtaining the Institutional Ethical Committee clearance. Written informed consent was obtained from twenty participants aging 35-65 years requiring treatment for NCCLs [Figure 1]. Participants having three pairs of wedge-shaped NCCLs on premolars with depth of 1-3 mm and 2°, 3°, or 4° dentinal sclerosis,[15] good gingival/periodontal health, and occlusion/proximal contact were included in the study. Participants having rampant caries, parafunctional habits, and who were unable to return for recall evaluations were excluded from the study. The minimum sample size required is 75, i.e., 25 for each group with a 95%

# Sturge Weber Syndrome: A Case Study

MAHESH NEERUPAKAM<sup>1</sup>, PODDUTURI SANJAY REDDY<sup>2</sup>, BEERABOINA ANAND BABU<sup>3</sup>, GUTTIKONDA VAMSI KRISHNA<sup>4</sup>

## ABSTRACT

The aim of this case review was to touch upon the various clinical presentations and diagnostic features of Sturge-Weber syndrome (SWS) as seen in the dental/medical practice. Sturge-Weber syndrome is a rare congenital disorder that belongs to a group of disorders collectively known as the phakomatoses. The characteristic pathological elements of the disease include leptomeninges angioma extending out to cerebral cortex with angiomatous lesions on the same side and unilateral facial nevus that affects trigeminal nerve division. The classic oral lesions involve haemangiomas of gingival lesion limited on the same side of upper or lower jaw. An 18-year-old female patient reported to the Department of Oral Medicine and Radiology with oral manifestations of SWS. The evaluation of the patient, radiological findings as well as the management is discussed in this case report. It is important for the dental physician to be aware of the non-oral manifestations of SWS in order to identify and manage it appropriately. The challenge here is to see the oral manifestation as part of the syndrome and not as an isolated oral condition. Early diagnosis and appropriate treatment plan is imperative to prevent development of complications.

**Keywords:** Gingival hyperplasia, Phakomatoses, Port-wine stain

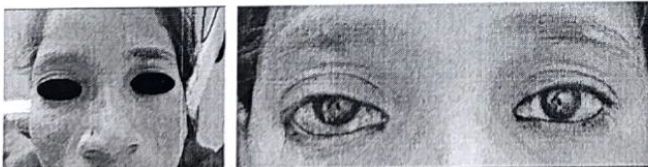## CASE REPORT

An 18-year-old female patient presented to the Oral Medicine and Radiology department with the primary complaint of swollen and bleeding gums in upper right maxillary region from the past one year. Patient gave a history of under-going surgery for glaucoma of right eye at the age of three months and was under medication for the same till date. She also gave a history of having seizures at young age which were transient and decreased with age.

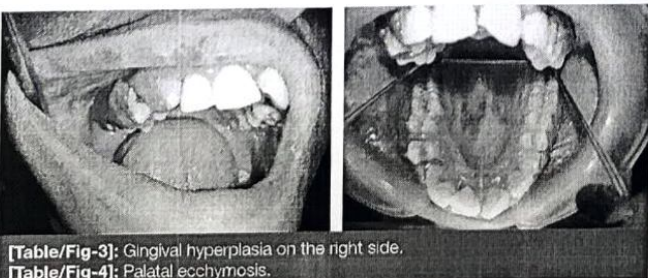
Extra oral examination was positive for presence of Port Wine Stain (PWS) on the right side of face along the ophthalmic and maxillary divisions of trigeminal nerve, involving lips and vermilion border of lips of the same side [Table/Fig-1]. Examination of eye showed enlarged globe of right eye with bluish discoloration of bulbar conjunctiva, decreased vision and glaucoma [Table/Fig-2].

Intraoral examination showed hyperplasia of right side gingiva, including interdental, marginal and attached gingiva extending from anterior to posterior region. Palatal ecchymosis was also present [Table/Fig-3,4]. The clinical picture and examination pointed to SWS and further investigations were done to confirm the same.

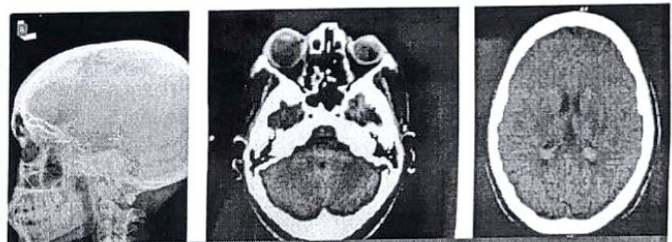
An X-ray examination of right lateral skull revealed slight eminence of the vessels with horizontal bone loss around teeth [Table/Fig-5].



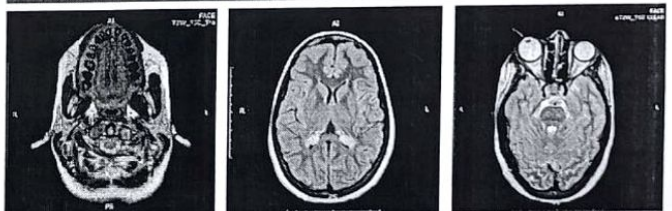[Table/Fig-1]: Port wine stain on the right side of face. [Table/Fig-2]: Enlarged right eye lobe with bluish discoloration of bulbar conjunctiva.



[Table/Fig-3]: Gingival hyperplasia on the right side.  
[Table/Fig-4]: Palatal ecchymosis.



[Table/Fig-5]: Lateral skull showing slight prominence of the vessels.  
[Table/Fig-6,7]: Prominent right optical lobe with no significant brain parenchymal abnormality. (Images from left to right)



[Table/Fig-8]: MRI showing generalized gingival hyperplasia of the right side.  
[Table/Fig-9]: Bilateral mild choroid plexus enlargements.  
[Table/Fig-10]: Right buphthalmos. (Images from left to right)

An axial section of CT of brain indicated the presence of prominent right optical lobe with no significant brain parenchymal abnormality [Table/Fig-6,7], MRI of brain and maxilla showed generalized gingival hyperplasia of the right side, mild choroid plexus enlargement and buphthalmos right side [Table/Fig-8-10]. Blood investigations were normal. The radiological findings confirmed the diagnosis of SWS.

Once the diagnosis was established the patient was first treated with deep scaling and curettage of right maxillary region. This resulted in a slight regression of gingival hyperplasia. A complete gingivectomy was performed with diode laser using 980 nm continuous wave motion under 5 watts current. Follow up of the patient after three weeks showed good healing with no recurrence.

## DISCUSSION

SWS is an uncommon congenital disorder. It is a type of neuro-cutaneous diseases called phakomatoses and is also referred as encephalofacial angiomatosis or cephalotrigeminal angiomatosis. It is seen in 1 in 50,000 populations. It affects both the sexes equally



## CASE REPORT

Year : 2017 | Volume : 29 | Issue : 2 | Page : 145-148

## Central giant cell granuloma: A case report and review

Krishnaveni Buduru<sup>1</sup>, Sanjay Reddy Podduturi<sup>1</sup>, Dal Singh Vankudoth<sup>2</sup>, Jacob Prakash<sup>3</sup>,

<sup>1</sup> Department of Oral Medicine and Radiology, Lenora Institute of Dental Sciences, Rajahmundry, Andhra Pradesh, India

<sup>2</sup> Department of Oral and Maxillofacial Surgery, Lenora Institute of Dental Sciences, Rajahmundry, Andhra Pradesh, India

<sup>3</sup> Department of Oral Pathology, Lenora Institute of Dental Sciences, Rajahmundry, Andhra Pradesh, India

### Correspondence Address:

Krishnaveni Buduru

Department of Oral Medicine and Radiology, Lenora Institute of Dental Sciences, Rajahmundry, Andhra Pradesh  
India

## Abstract

Central giant cell granuloma (CGCG) is a benign intra-osseous lesion of unknown etiology, and occurs in jaws. Clinically and radiographically difference between its nature - aggressive and non-aggressive can be made. It is characterized histologically by cellular fibrous tissue containing multiple foci of hemorrhage, aggregations of multinucleated giant cells, and occasionally, trabeculae of woven bone. Histologically, identical lesions occur in patients with known genetic defects such as cherubism, Noonan syndrome, or neurofibromatosis type I. It has an increased predilection for mandible and females in younger age group. Surgical curettage or resection is the most common therapy in aggressive lesions. The drawback is undesirable damage to the jaw or teeth, tooth germs, and frequent recurrences. Non-aggressive tumors respond well to such treatments. We are presenting a case of an aggressive type of CGCG of mandible in a young patient, who presented with massive swelling associated with loss of teeth in just 6 months duration.

### How to cite this article:

Buduru K, Podduturi SR, Vankudoth DS, Prakash J. Central giant cell granuloma: A case report and review. J Indian Acad Oral Med Radiol 2017;29:145-148

### How to cite this URL:

Buduru K, Podduturi SR, Vankudoth DS, Prakash J. Central giant cell granuloma: A case report and review. J Indian Acad Oral Med Radiol [serial online] 2017 [cited 2022 Oct 29];29:145-148

Available from: <https://www.jiaomr.in/text.asp?2017/29/2/145/217901>

## Full Text

### Introduction

Central giant cell granuloma (CGCG) of the jaw is a benign osteolytic lesion. It may exhibit aggressive biologic behavior, characterized by localized swelling, pain, rapid growth, bony expansion, cortical perforation, tooth displacement, and root resorption.[1],[2] It has been defined by the World Health Organization as an intraosseous lesion consisting of cellular fibrous tissue containing multiple foci of hemorrhage, aggregations of multinucleated giant cells, and occasionally, trabeculae of woven bone.[3] CGCG, first described by Jaffe in 1953, is a benign lesion that usually occurs in the mandible and the maxilla.